

## Effects of *Equisetum arvense* Ointment on Diabetic Wound Healing in Rats

Yusuf Ozay<sup>1</sup>; M. Kasim Cayci, PhD<sup>2</sup>; Sevda Guzel-Ozay<sup>3</sup>; Ali Cimbiz<sup>4</sup>; Esra Gurlek-Olgun<sup>5</sup>; M. Sabri Ozyurt<sup>2</sup>

WOUNDS 2013;25(9):234-241

From the <sup>1</sup>Department of Medical Biology, Faculty of Medicine, Adiyaman University, Adiyaman, Turkey; <sup>2</sup>Faculty of Arts and Sciences, Department of Biology, Dumlupinar University, Kutahya, Turkey; <sup>3</sup>Faculty of Pharmacy, Department of Pharmacognosy, Mersin University, Mersin, Turkey; <sup>4</sup>Faculty of Health Sciences, Department of Physiotherapy and Rehabilitation, Zirve University, Gaziantep, Turkey; <sup>5</sup>Ministry of Health, Department of Forensic Medicine, Izmir, Turkey

Address correspondence to:

**M. Kasim Cayci, PhD**  
Dumlupinar University  
Faculty of Arts and Sciences  
Department of Biology  
Merkez Campus  
Tavsanlı Yolu 10. km  
43270 Kutahya/Turkey  
mkasim.cayci@dpu.edu.tr

*Disclosure: The authors disclose no financial or other conflicts of interest.*

**Abstract:** This study is designed to evaluate the effect of *Equisetum arvense* (EA) ointment on dermal diabetic wound healing in streptozotocin-induced diabetic rats. **Methods.** In this study, diabetes was induced via a single intraperitoneal injection of 65 mg/kg streptozotocin in 56 male Wistar rats. After anesthetization, a 15 mm x 15 mm wound for each rat was made by removing skin in a circle on the dorsum. A total of 56 diabetic wounds were studied in 8 groups (n = 7), 4 of which were treated with EA ointment. On the 7th and 14th days after creating the wounds, the state of the diabetic wound healing was evaluated with wound closure ratio and by performing histopathologic studies. **Results.** Groups treated with EA 5%-10% ointment were found to have a statistically higher wound closure ratio than control and petroleum jelly-lanolin groups ( $P < 0.05$ ). On day 14, groups to which EA 5%-10% ointment was applied showed 99.71% and 99.93% wound closure ratio ( $P < 0.05$ ) and higher dermal and epidermal regeneration, angiogenesis, and granulation tissue thickness after 14 days than the other groups ( $P < 0.05$ ). **Conclusion.** These results indicate that EA ointments exhibit significant diabetic wound healing activity in excision wounds. Further clinical and experimental studies are needed to confirm these results.

**Key words:** *Equisetum arvense*, diabetic wound healing, reepithelialization, rat

The prevalence of diabetes has increased worldwide, and diabetic complications have become a serious issue for public health. One of these complications is impaired wound healing in patients with diabetes.<sup>1,2</sup> The wound healing process is a complex cascade that relies on several mechanisms for tissue repair, including inflammation, granulation tissue formation, reepithelialization, and angiogenesis.<sup>3</sup> However, with pathological conditions, such as diabetes mellitus, epithelial wound healing is delayed, resulting in persistent corneal epithelial defects and

recurrent corneal erosion,<sup>4,5</sup> which makes the diabetic wounds a great problem for health services. The most common site for patients with diabetes to develop a wound is in the lower extremities, especially the feet.<sup>6</sup> The pathogenesis of diabetic foot ulcers is complex and it is well known that a number of contributing factors working together lead to impaired healing. Several factors such as peripheral neuropathy, peripheral vascular disease, and peripheral edema have been identified as the most common factors responsible for impaired healing after trauma.<sup>7</sup>

Patients can undergo surgical interventions, such as peripheral bypass to improve vascular circulation, wound debridement to control the wound, and amputation, if required. However, medical therapies for wound care are limited, so development of new treatment modalities to improve wound healing in patients with diabetes is an essential and emerging field of investigation.<sup>8</sup> Numerous conservative methods for treatment of diabetic wounds are reported in the literature, such as honey as a dressing solution,<sup>9</sup> topical antimicrobial therapies,<sup>10</sup> total contact casting,<sup>11</sup> wound dressings,<sup>12</sup> extracorporeal shock wave therapy,<sup>13</sup> and vacuum-assisted closure.<sup>14</sup> Some herbal therapies were also reported, such as *Astragalus membranaceus* and *Rebmannia glutinosa*.<sup>15</sup>

The *Equisetum arvense* (EA) plant has been traditionally used in Turkey for the treatment of skin wounds in animals and for oral infections in humans. In addition, EA has also been used in Europe in the form of a bath for gynecological diseases, rheumatic diseases, gout, and treatment of poorly healing wounds, tumescence, and broken bones.<sup>16,17</sup>

Several studies have shown hypoglycemic anti-septic, antimicrobial, antioxidant, antidepressant, sedative, hepatoprotective, antinociceptive, and anti-inflammatory effects of the EA plant.<sup>18-23</sup> Less is known about the role of EA in diabetic dermal wounds. The present study was aimed to investigate the efficacy of topical application of EA ointment by morphological and histological methods in the process of wound healing in streptozotocin (STZ)-induced diabetic rats.

## Methods

Albino Wistar male rats weighing 200 g - 250 g were obtained from the central animal house of Dumlupinar University and used for the study. Rats were housed individually in cages, maintained under standard conditions (12 hour light/12 hour dark cycle at 25°C ± 3°C),

### KEYPOINTS

- Numerous conservative methods for treatment of diabetic wounds are reported in the literature such as honey as a dressing solution,<sup>9</sup> topical antimicrobial therapies,<sup>10</sup> total contact casting,<sup>11</sup> wound dressings,<sup>12</sup> extracorporeal shock wave therapy,<sup>13</sup> vacuum-assisted closure,<sup>14</sup> and herbal therapies.<sup>15</sup>
- Several studies have shown hypoglycemic anti-septic, antimicrobial, antioxidant, antidepressant, sedative, hepatoprotective, antinociceptive, and anti-inflammatory effects of the *Equisetum arvense* (EA) plant.<sup>18-23</sup>
- Less is known about the role of EA in diabetic dermal wounds.

and fed with standard pellet and water *ad libitum*. Animal studies were performed after approval from Animal Care and Ethics Committee of Dumlupinar University.

The EA plant was collected in Mersin, Turkey. The plant was identified in the Department of Biology in Dumlupinar University Faculty of Arts and Sciences. Air-dried leaves of the plant were turned into a powder using a grinder. An ointment base was formulated using a 1:1 mixture of petroleum jelly and lanolin. For 10% and 5% EA ointment, EA powder was mixed with the ointment base during ointment-forming process (eg, for 10% EA ointment, 5 g of EA powder was mixed into 45 g of the ointment base).<sup>24</sup>

Diabetes was induced by a single dose intraperitoneal (IP) injection of STZ (65 mg/kg, Sigma-Aldrich, St. Louis, MO) freshly prepared in saline.<sup>25</sup> Three days after the STZ injection, glycemia was confirmed, and rats showing fasting blood glucose > 250 mg/dl were considered diabetic rats. Animals were randomly divided into 8 groups, each of them consisting of 7 rats. Capillary blood glucose was determined by glucose meter (Optium Xceed, Abbott, Diabetes Care Ltd, Oxon, UK).

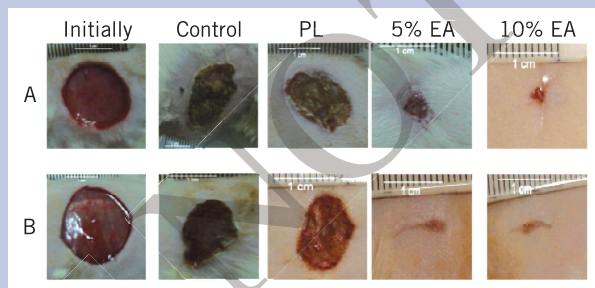
A deep skin ulcer model was created using diabetic rats as follows.<sup>24</sup> The rats were anesthetized by IP injection of xylazine hydrochloride (10 mg/kg) and ketamine hydrochloride (25 mg/kg), their back hair was shaved, and application field was outlined with a marking pen just before removing the skin. Full-thickness skin wounds in each rat were prepared by removing skin in a circle with 1.5 cm diameter on the dorsum. A total of 56 diabetic wounds were studied in 8 groups (n = 7). No treatment was administered in the first and second groups, which lasted for 7 days and 14 days, respectively. The third and fourth groups consisted of diabetic

**Table 1.** Histological scores of wounds.

Scores	Epidermal and dermal regeneration	Granulation tissue thickness	Angiogenesis
1±	Little epidermal and dermal organization	Thin granular layer	Altered angiogenesis (1-2 vessels per site) characterized by a high degree of edema, hemorrhage, and occasional congestion and thrombosis
2±	Moderate epidermal and dermal organization	Moderate granulation layer	Few newly formed capillary vessels (3-6 per site); moderate degree of edema and hemorrhage. Occasional congestion and intervascular fibrin deposition; absence of thrombosis
3±	Complete remodeling of epidermis and dermis	Thick granulation layer	Newly formed capillary vessels (7-10 per site); moderate degree of perivascular and interstitial edema and congestion; absence of thrombosis and hemorrhage
4±		Very thick granulation layer	Newly formed and well-structured capillary vessels (> 10 per site) vertically disposed toward the epithelium and at the wound margins; slight degree of perivascular edema

**KEYPOINTS**

- Diabetes was induced by a single dose intraperitoneal injection of streptozotocin (65 mg/kg, Sigma-Aldrich, St. Louis, MO) freshly prepared in saline.<sup>25</sup>
- Full-thickness skin wounds in each rat were prepared by removing skin in a circle with 1.5 cm diameter on the dorsum.
- A total of 56 diabetic wounds were studied in 8 groups (n = 7).



**Figure 1.** Macroscopic view of wound in the rats. A: Macroscopic view of wounds on day 7. B: Macroscopic view of the wound on day 14. PL: petroleum jelly-lanolin; EA: *Equisetum arvense*

rats that were administered a 1:1 mixture of petroleum jelly and lanolin therapy for 7 days and 14 days, respectively. A 5% EA plus 1:1 mixture of petroleum jelly and lanolin was used in the fifth and sixth groups for 7 days and 14 days, respectively; and in the seventh and eighth groups, 10% EA plus 1:1 mixture of petroleum jelly and lanolin therapy was used for 7 days and 14

days, respectively. All wounds were cleaned daily with sterile normal saline solution. After cleaning, ointment base and EA ointments were applied to the wounds. All ointments were applied evenly in sufficient amounts to cover all wound areas.

After treatment started, the animals were euthanized by ether inhalation at appropriate intervals (on days 7 or 14) and the tissues, including the wound and its surrounding skin and muscle, were excised. Wound healing was examined by measuring the reduction of the wound surface area with a stereomicroscope (SZX-ILLD2-200, Olympus, Center Valley, PA) and photographed using a digital camera (Spot Insight QE, Diagnostic Instruments, Sterling Heights, MI). The ratio of healing was calculated using the following equation: Healing ratio (%) = 100 x (1-wound area/initial wound area)

After macroscopic evaluation, the excised tissue was fixed with 10% buffered formalin. Each specimen was embedded in a paraffin block, sliced into thin 2.5-µm sections, and stained with hematoxylin-eosin. Then, the specimens were assessed for severity of histopathologic changes, under light microscopy by a pathologist who was unaware of the experimental procedure. Epidermal and dermal regeneration, granulation tissue thickness, and angiogenesis were scored as described by Altavilla et al<sup>26</sup> according to the criteria as shown in Table 1.

**Statistical Analysis**

The results were expressed as mean ± SD and statistical differences between several treatments and their

Table 2. Demonstration of the weights and glucose results in groups.				
Groups	Weight (gr) Initially	Day 7	Glucose (mg/dl) Initially	Day 7
Control	204.9 ± 9.4	197.9 ± 10.7	340.4 ± 58.4	365.7 ± 50.3
PL	207.7 ± 7.7	199.3 ± 7.6	323.4 ± 55.2	347.7 ± 58.3
5% EA	205.4 ± 18.9	199 ± 18.1	327.9 ± 82.0	352.4 ± 76.2
10% EA	204.9 ± 16.3	195.6 ± 16.6	312 ± 84.7	356.6 ± 71.4
	Initially	Day 14	Initially	Day 14
Control	217.9 ± 12.5	203 ± 13.7	314.9 ± 73.6	372.4 ± 43.4
PL	216.1 ± 17.7	200.4 ± 14.3	289 ± 39.3	358.3 ± 62.2
5% EA	219.4 ± 15.8	202.9 ± 10.9	285 ± 43.4	356.6 ± 35.1
10% EA	212 ± 17.6	196.7 ± 16.7	339.4 ± 48.9	411.9 ± 23.5

Data are presented Mean ± SD, PL: petroleum jelly-lanolin, EA: *Equisetum arvense*

respective control were determined by one-way analysis of variance (ANOVA) followed by Tukey test, using SPSS 14.0 software. The level of significance was set at  $P < 0.05$ .

## Results

Animal weight and glucose results for the 7th and 14th days are shown in Table 2. Accordingly, in the multiple comparisons, the rates of wound healing were found to be significantly higher in the diabetic rat groups administered 5% EA and 10% EA ointment compared with those administered a mixture of petroleum jelly and lanolin (PL) and the untreated group (for comparison, the level of significance was set at  $P < 0.05$ ).

Macroscopic view and wound closure ratio are presented in Figure 1(A and B) and Figure 2. On the 7th day wound closure ratios were observed  $-1.78\% \pm 30.14\%$  in control group,  $11.7\% \pm 10.38\%$  in PL group,  $76.74\% \pm 7.93\%$  in 5% EA group, and  $85.1 \pm 8.44\%$  in 10% EA group. The EA groups were found statistically more significant than PL and control groups ( $P < 0.05$ ). On the 14th day, wound closure ratios observed were  $14.37\% \pm 28.51\%$  in the control group,  $40.04\% \pm 9.93\%$  in the PL group,  $99.7\% \pm 0.24\%$  in the 5% EA group, and  $99.9\% \pm 0.19\%$  in the 10% EA group ( $P < 0.05$ ).

The authors think the efficacy of the EA ointment is more related to treatment time rather than dosage because there were no significant differences in wound healing in the 5% EA group and the 10% EA group during day 7 and day 14 ( $P > 0.05$ ).

The results of histopathologic studies are presented in Table 3 and Figure 3. At the end of the first week the histopathologic scores were found to be higher in the EA groups of dermal regeneration, granulation tissue thickness, and angiogenesis levels than in the control and PL

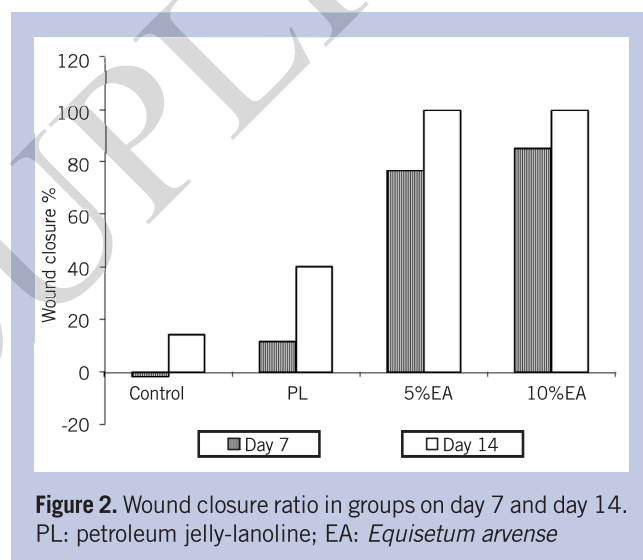


Figure 2. Wound closure ratio in groups on day 7 and day 14. PL: petroleum jelly-lanoline; EA: *Equisetum arvense*

## KEYPOINTS

- The rates of wound healing were found to be significantly higher in the diabetic rat groups administered 5% *Equisetum arvense* (EA) and 10% EA ointment compared with those administered a mixture of petroleum jelly and lanolin (PL) and the untreated group.
- The authors think the efficacy of the EA ointment is more related to treatment time rather than dosage because there were no significant differences in wound healing in the 5% EA group and the 10% EA group during day 7 and day 14 ( $P > 0.05$ ).

groups ( $P < 0.05$ ). In the second week, all histopathologic scores were observed higher in the EA groups than the other groups ( $P < 0.05$ ), which also supports the conclusion about the efficacy of treatment time and inefficacy of

**Table 3.** Histological scores of the groups.

Groups	ER	DR	GTT	Angiogenesis
<b>Day 7</b>				
Control	1.0 ± 0.0	1.0 ± 0.0	1.0 ± 0.0	1.0 ± 0.0
PL	1.0 ± 0.0	1.29 ± 0.49	1.0 ± 0.0	1.0 ± 0.0
5% EA	1.29 ± 0.49*	1.86 ± 0.38*	1.71 ± 0.49*	1.57 ± 0.53*
10% EA	1.29 ± 0.49*	1.86 ± 0.38*	1.86 ± 0.38*	1.29 ± 0.49*
<b>Day 14</b>				
Control	1.0 ± 0.0	1.29 ± 0.49	1.14 ± 0.38	1.0 ± 0.0
PL	1.14 ± 0.38	1.57 ± 0.53	1.29 ± 0.49	1.14 ± 0.38
5% EA	2.57 ± 0.53*	2.86 ± 0.38*	3.86 ± 0.38*	3.86 ± 0.38*
10% EA	3.0 ± 0.0*	3.0 ± 0.0*	4.0 ± 0.0*	4.0 ± 0.0*

Data are presented as Mean ± SD; PL: petroleum jelly-lanolin; EA: *Equisetum arvense*; ER: epidermal regeneration; DR: dermal regeneration; GTT: granulation tissue thickness.  
\* Indicates statistical significance from its own control group and from the PL group ( $P < 0.05$ ).

EA ointments dosage percentage. The authors did not find significant difference in histopathologic scores within either the EA or control groups ( $P > 0.05$ ) (Table 3).

## Discussion

Wound healing is a complex multifactorial process that results in the contraction and closure of the wound. The wound-healing process comprises inflammation, proliferation (formation of granulated tissue), and tissue remodeling. Reepithelialization of wounds begins within hours of injury and proceeds first over the margin of the residual dermis and subsequently over granulation tissue.<sup>27,28</sup>

In diabetic wounds, the healing process is prevented by several abnormalities including prolonged inflammation, impaired neovascularization, decreased collagen synthesis, and defective macrophage functions.<sup>29-31</sup> Impaired wound healing occurs in patients with diabetes, and has been reported to be associated with high blood glucose levels.<sup>32,33</sup> Hence, in the present study, rats with STZ-induced diabetes were used as the model for the study diabetic wound healing.

The STZ selectively destroys pancreatic  $\beta$ -cells, inhibits the synthesis and release of insulin, and causes the on-

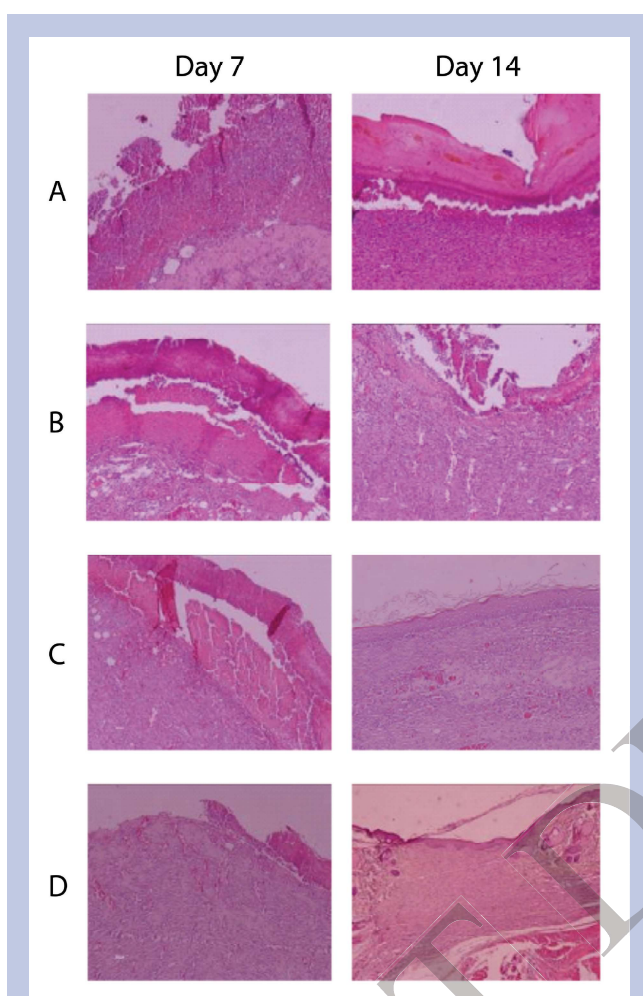
set of diabetes mellitus.<sup>34</sup> It has been shown that blood glucose levels peak 1 to 3 days after a single high-dose injection of STZ, and then remains elevated.<sup>35</sup> Streptozotocin-induced diabetes in rodents is considered to be a model of insulin-dependent diabetes mellitus, and is widely used in the study of insulinopenia and hyperglycemia.<sup>36</sup> Diabetes that has been induced by a single high dose of STZ is typically accompanied by diabetic symptoms such as weight loss, polyuria, hyperglycemia, and neuroendocrine dysfunction.<sup>37</sup>

In the present study, wound healing activity was observed in satisfactory progress when treated with ointment of EA for full-thickness skin diabetic wounds. In wounds treated with either 5% or 10% EA ointment, the period of epithelialization decreased, there were higher scores in granulation tissue thickness, angiogenesis, and wound closure ratio. In addition, both 5% and 10% EA ointment increased reepithelialization and formulated new blood vessels, especially on day 14.

There are many studies about diabetic wound healing in the recent literature. Some herbs used to make ointment for diabetic foot ulcers were Radix Rehmanniae,<sup>38</sup> oak bark in conjunction with salicylic acid benzoic acid (Bensal HP, 7 Oaks Pharmaceutical Corp, Easley, NC),<sup>39</sup> and polyherbal formulations (*Hippophae rhamnoides L.* and *Aloe vera L.* and *Curcuma longa L.*).<sup>40</sup> In diabetic full-thickness skin wounds, as used in present study, *Channa striatus*<sup>41</sup> and *Sparassis crispa*<sup>42</sup> were used for treatment of the diabetic wounds. In addition, some herb extracts were used for hypoglycemic effects as shown in the plant of *Strychnos pseudoquina* extracts

### KEYPOINTS

Because of its antioxidant, antimicrobial, and anti-inflammatory effects, the *Equisetum arvense* (EA) plant decreased processes of inflammation, improved neovascularization, and increased collagen synthesis and macrophage functions. Thanks to these positive effects, EA can be used for diabetic wound healing.



**Figure 3.** Hematoxylin-eosin (H&E X 100) stained sections of wound specimens on day 7 and day 14 from (A) untreated diabetic rat; (B) a diabetic rat treated with PL; (C) a diabetic rat treated with 5% EA ointment; and (D) a diabetic rat treated with 10% EA ointment.

(A) (day 7 and day 14) and (B) (day 7): H&E 100 $\times$  showing persistent ulceration and crust overlying the area of the wound, with thickened and immature epidermis.

(B) (day 14), (C) (day 7), and (D) (day 7): Swollen endothelial cells, poorly formed capillary channels, and evident hemorrhage characterize vascular changes.

(C) (day 7 and day 14) and (D) (day 7 and day 14): Complete remodeling of epithelium and connective tissue with a good reepithelialization, well-organized granulation tissue and connective tissue.

PL: petroleum jelly-lanolin; EA: *Equisetum arvense*

in cutaneous diabetic wound.<sup>43</sup> The referenced studies show these plants are effective for treatment of diabetic wounds. This study, with treatment results as well as

with the material and methods, is concordant with these literature studies.

## Conclusion

Angiogenesis plays an important role in wound healing and newly formed blood vessels comprise 60% of the repair tissue. Neovascularization helps hypoxic wounds to attain the normoxic conditions.<sup>44</sup> Reepithelialization plays a crucial role in cutaneous repair, depending upon the specific type of wound.<sup>45,46</sup> It was observed that the EA ointment increased the angiogenesis phase, and the reepithelialisation and wound healing process.

Literature studies show that plants proven effective at accelerating wound healing have antimicrobial, antioxidant, and anti-inflammatory characteristics. *Equisetum arvense* plants comprise antioxidant components such as flavonoids (ie, quercetin-3-O-glucoside, luteolin, onitin, isoquercitrin); copper and zinc<sup>19,22,47-50</sup>; antimicrobial components such as caffeic acid, styrylpyrone, thymol, hexahydro femmesil, trans-phytol, cisgeranyl acetone, kaempferol<sup>18,51-53</sup>; anti-inflammatory components such as  $\beta$ -cytosterol, campesterol; and isofucosterol chemical elements which have induced neutrophil migration.<sup>54,55,56,57</sup> Because of its antioxidant, antimicrobial, and anti-inflammatory effects, the EA plant decreased processes of inflammation, improved neovascularization, and increased collagen synthesis and macrophage functions. Thanks to these positive effects, EA can be used for diabetic wound healing. In addition, the authors found that the dosage of EA is not important. This plant can be used effectively in low doses. Consequently, the results of present study indicates important healing effects in diabetic wounds in an animal model.

## References

1. Brem H, Tomic-Canic M. Cellular and molecular basis of wound healing in diabetes. *J Clin Invest*. 2007;117(5):1219-1222.
2. Pavlović MD, Milenković T, Dinić M, et al. The prevalence of cutaneous manifestations in young patients with type 1 diabetes. *Diabetes Care*. 2007;30(8):1964-1967.
3. Yatomi Y, Igarashi Y, Yang L, et al. Sphingosine 1-phosphate, a bioactive sphingolipid abundantly stored in platelets, is a normal constituent of human plasma and serum. *J Biochem*. 1997;121(5):969-973.
4. Valls MD, Cronstein BN, Montesinos MC. Adenosine receptor agonists for promotion of dermal wound heal-

- ing. *Biochem Pharmacol.* 2009;77(7):1117-1124.
5. Friend J, Thoft RA. The diabetic cornea. *Int Ophthalmol Clin.* 1984;24(4):111-123.
  6. Ribu L, Birkeland K, Hanestad BR, Moum T, Rustoen T. A longitudinal study of patients with diabetes and foot ulcers and their health-related quality of life: wound healing and quality-of-life changes. *J Diabetes Complications.* 2008;22(6):400-407.
  7. Gary Sibbald R, Woo KY. The biology of chronic foot ulcers in persons with diabetes. *Diabetes Metab Res Rev.* 2008;24(suppl 1):S25-S30.
  8. Trousdale RK, Jacobs S, Simhae DA, Wu JK, Lustbader JW. Wound closure and metabolic parameter variability in a db/db mouse model for diabetic ulcers. *J Surg Res.* 2009;151(1):100-107.
  9. Shukrimi A, Sulaiman AR, Halim AY, Azril A. A comparative study between honey and povidone iodine as dressing solution for Wagner type II diabetic foot ulcers. *Med J Malaysia.* 2008;63(1):44-46.
  10. Lipsky BA, Holroyd KJ, Zasloff M. Topical versus systemic antimicrobial therapy for treating mildly infected diabetic foot ulcers: a randomized, controlled, double-blinded, multicenter trial of pexiganan cream. *Clin Infect Dis.* 2008;47(12):1537-1545.
  11. Ganguly S, Chakraborty K, Mandal PK, et al. A comparative study between total contact casting and conventional dressings in the non-surgical management of diabetic plantar foot ulcers. *J Indian Med Assoc.* 2008;106(4):237-239, 244.
  12. Kordestani S, Shahrezaee M, Tahmasebi MN, Hajimahmoudi H, Haji Ghasemali D, Abyaneh MS. A randomised controlled trial on the effectiveness of an advanced wound dressing used in Iran. *J Wound Care.* 2008;17(7):323-327.
  13. Saggini R, Figus A, Troccola A, Cocco V, Saggini A, Scuderi N. Extracorporeal shock wave therapy for management of chronic ulcers in the lower extremities. *Ultrasound Med Biol.* 2008;34(8):1261-1271.
  14. Eneroth M, van Houtum WH. The value of debridement and Vacuum-Assisted Closure (V.A.C.) Therapy in diabetic foot ulcers. *Diabetes Metab Res Rev.* 2008;24(suppl 1):S76-S80.
  15. Lau TW, Sahota DS, Lau CH, et al. An in vivo investigation on the wound-healing effect of two medicinal herbs using an animal model with foot ulcer. *Eur Surg Res.* 2008;41(1):15-23.
  16. Koç H. *Lokman Hekimden Günümüze Bitkilerle Sağlıklı Yaşama.* 1st ed. Ankara: Kultur Bakanlığı Yayınları; 2002:66.
  17. Baytop T. *Türkiye'de Bitkiler ile Tedavi (Geçmişte ve Bugün).* İstanbul: İstanbul Üniversitesi Eczacılık Fakültesi Yayınları; 1984:171-172.
  18. Broudiscou LP, Papon Y, Broudiscou AF. Effects of dry plant extracts on fermentation and methanogenesis in continuous culture of rumen microbes. *Anim Feed Sci Technol.* 2000;87(3):263-277.
  19. Guilherme dos Santos J Jr, Hoffmann Martins do Monte F, Marcela Blanco M, Maria do Nascimento Bispo Lanziotti V, Damasseno Maia F, Kalyne de Almeida Leal L. Cognitive enhancement in aged rats after chronic administration of *Equisetum arvense* L. with demonstrated antioxidant properties in vitro. *Pharmacol Biochem Behav.* 2005;81(3):593-600.
  20. Mekhfi H, El Haouari M, Legssyer A, et al. Platelet anti-aggregant property of some Moroccan medicinal plants. *J Ethnopharmacol.* 2004;94(2-3):317-322.
  21. Do Monte FH, dos Santos JG Jr, Russi M, Lanziotti VM, Leal LK, Cunha GM. Antinociceptive and anti-inflammatory properties of the hydroalcoholic extract of stems from *Equisetum arvense* L. in mice. *Pharmacol Res.* 2004;49(3):239-243.
  22. Oh H, Kim DH, Cho JH, Kim YC. Hepatoprotective and free radical scavenging activities of phenolic petrosins and flavonoids isolated from *Equisetum arvense*. *J Ethnopharmacol.* 2004;95(2-3):421-424.
  23. Dos Santos JG Jr, Blanco MM, Do Monte FH, et al. Sedative and anticonvulsant effects of hydroalcoholic extract of *Equisetum arvense*. *Fitoterapia.* 2005;76(6):508-513.
  24. Aramwit P, Sangcakul A. The effects of sericin cream on wound healing in rats. *Biosci Biotechnol Biochem.* 2007;71(10):2473-2477.
  25. Stoenoiu MS, De Vriese AS, Brouet A, et al. Experimental diabetes induces functional and structural changes in the peritoneum. *Kidney Int.* 2002;62(2):668-678.
  26. Altavilla D, Saitta A, Cucinotta D, et al. Inhibition of lipid peroxidation restores impaired vascular endothelial growth factor expression and stimulates wound healing and angiogenesis in the genetically diabetic mouse. *Diabetes.* 2001;50(3):667-674.
  27. Martin P. Wound healing—aiming for perfect skin regeneration. *Science.* 1997;276(5309):75-81.
  28. Singer AJ, Clark RA. Cutaneous wound healing. *N Engl J Med.* 1999;341(10):738-746.
  29. Kane CD, Greenhalgh DG. Expression and localization of p53 and bcl-2 in healing wounds in diabetic and nondiabetic mice. *Wound Repair Regen.* 2000;8(1):45-58.
  30. Darby IA, Bisucci T, Hewitson TD, MacLellan DG. Apoptosis is increased in a model of diabetes-impaired

- wound healing in genetically diabetic mice. *Int J Biochem Cell Biol.* 1997;29(1):191-200.
31. Rodgers KE, Ellefson DD, Espinoza T, Hsu YH, diZerega GS, Mehrian-Shai R. Expression of intracellular filament, collagen, and collagenase genes in diabetic and normal skin after injury. *Wound Repair Regen.* 2006;14(3):298-305.
  32. Hehenberger K, Heilborn JD, Brismar K, Hansson A. Inhibited proliferation of fibroblasts derived from chronic diabetic wounds and normal dermal fibroblasts treated with high glucose is associated with increased formation of l-lactate. *Wound Repair Regen.* 1998;6(2):135-141.
  33. Hoogwerf BJ. Postoperative management of the diabetic patient. *Med Clin North Am.* 2001;85(5):1213-1228.
  34. Elias D, Prigozin H, Polak N, Rapoport M, Lohse AW, Cohen IR. Autoimmune diabetes induced by the beta-cell toxin STZ. Immunity to the 60-kDa heat shock protein and to insulin. *Diabetes.* 1994;43(8):992-998.
  35. Candela S, Hernandez RE, Gagliardino JJ. Circadian variation of the streptozotocin-diabetogenic effect in mice. *Experientia.* 1979;35(9):1256-1257.
  36. Rees DA, Alcolado JC. Animal models of diabetes mellitus. *Diabet Med.* 2005;22(4):359-370.
  37. Reagan LP, Magariños AM, McEwen BS. Neurological changes induced by stress in streptozotocin diabetic rats. *Ann NY Acad Sci.* 1999;893:126-137.
  38. Lau TW, Lam FF, Lau KM, et al. Pharmacological investigation on the wound healing effects of Radix Rehmanniae in an animal model of diabetic foot ulcer. *J Ethnopharmacol.* 2009;123(1):155-162.
  39. Jacobs AM, Tomczak R. Evaluation of Bensaí HP for the treatment of diabetic foot ulcers. *Adv Skin Wound Care.* 2008;21(10):461-465.
  40. Kwon AH, Qiu Z, Hashimoto M, Yamamoto K, Kimura T. Effects of medicinal mushroom (*Sparassis crispa*) on wound healing in streptozotocin-induced diabetic rats. *Am J Surg.* 2009;197(4):503-509.
  41. Baie SH, Sheikh KA. The wound healing properties of *Channa striatus*-cetrimide cream-wound contraction and glycosaminoglycan measurement. *J Ethnopharmacol.* 2000;73(1-2):15-30.
  42. Gupta A, Upadhyay NK, Sawhney RC, Kumar R. A poly-herbal formulation accelerates normal and impaired diabetic wound healing. *Wound Repair Regen.* 2008;16(6):784-790.
  43. Honório-França AC, Marins CM, Boldrini F, França EL. Evaluation of hypoglycemic activity and healing of extract from amongst bark of "Quina do Cerrado" (*Strychnos pseudoquina* ST. HILL). *Acta Cir Bras.* 2008;23(6):504-510.
  44. Ehrlich HP, Grislis G, Hunt TK. Metabolic and circulatory contributions to oxygen gradients in wounds. *Surgery.* 1972;72(4):578-583.
  45. Schaffer CJ, Nanney LB. Cell biology of wound healing. *Int Rev Cytol.* 1996;169:151-181.
  46. Moulin V, Auger FA, Garrel D, Germain L. Role of wound healing myofibroblasts on re-epithelialization of human skin. *Burns.* 2000;26(1):3-12.
  47. Kim DW, Yokozawa T, Hattori M, Kadota S, Namba T. Inhibitory effects of an aqueous extract of *Apocynum venetum* leaves and its constituents on Cu(2+)-induced oxidative modification of low density lipoprotein. *Phytother Res.* 2000;14(7):501-504.
  48. Lee MH, Lin RD, Shen LY, Yang LL, Yen KY, Hou WC. Monoamine oxidase B and free radical scavenging activities of natural flavonoids in *Melastoma candidum* D. Don. *J Agric Food Chem.* 2001;49(11):5551-5555.
  49. Nagai T, Myoda T, Nagashima T. Antioxidative activities of water extract and ethanol extract from field horsetail (*tsukushi*) *Equisetum arvense* L. *Food Chem.* 2005;91(3):389-394.
  50. Stajner D, Popović BM, Canadanović-Brunet J, Anackov G. Exploring *Equisetum arvense* L., *Equisetum ramosissimum* L. and *Equisetum telmateia* L. as sources of natural antioxidants. *Phytother Res.* 2009;23(4):546-550.
  51. Beckert C, Horn C, Schnitzler JP, Lehning A, Heller W, Veit M. Styrylpyrone biosynthesis in *Equisetum arvense*. *Phytochemistry.* 1997;44(2):275-283.
  52. Radulović N, Stojanović G, Palić R. Composition and antimicrobial activity of *Equisetum arvense* L. essential oil. *Phytother Res.* 2006;20(1):85-88.
  53. Milovanović V, Radulović N, Todorović Z, Stanković M, Stojanović G. Antioxidant, antimicrobial and genotoxicity screening of hydro-alcoholic extracts of five Serbian *Equisetum* Species. *Plant Foods Hum Nutr.* 2007;62(3):113-119.
  54. Deepak M, Handa SS. Antiinflammatory activity and chemical composition of extracts of *Verbena officinalis*. *Phytother Res.* 2000;14(6):463-465.
  55. Park EH, Kahng JH, Lee SH, Shin KH. An anti-inflammatory principle from cactus. *FitoTerapia.* 2001;72(3):288-290.
  56. Gómez MA, Sáenz MT, García MD, Fernández MA. Study of the topical anti-inflammatory activity of *Achillea ageratum* on chronic and acute inflammation models. *Z Naturforsch C.* 1999;54(11):937-941.
  57. Navarro A, De las Heras B, Villar A. Anti-inflammatory and immunomodulating properties of a sterol fraction from *Sideritis foetens* Clem. *Biol Pharm Bull.* 2001;24(5):470-473.