



## Original Article

Intercalary autograft not mandatory for shortening in total hip arthroplasty: A retrospective study<sup>☆</sup>Mehmet Fevzi Cakmak<sup>a</sup>, Serkan Bayram<sup>b,\*</sup>, Levent Horoz<sup>a</sup>, Hicabi Sezgin<sup>c</sup>, Burak Akan<sup>d</sup><sup>a</sup> Department of Orthopedics and Traumatology, Kirsehir Ahi Evran University, Kirsehir, Türkiye<sup>b</sup> Department of Orthopedics and Traumatology, Istanbul Faculty of Medicine, Istanbul University, Istanbul, Türkiye<sup>c</sup> Department of Orthopedics and Traumatology, Amasya University, Amasya, Türkiye<sup>d</sup> Department of Orthopedics and Traumatology, Ufuk University Faculty of Medicine, Ankara, Türkiye

## ARTICLE INFO

## Article history:

Received 28 October 2024

Received in revised form

2 April 2025

Accepted 21 June 2025

Available online 16 July 2025

## Keywords:

Total hip arthroplasty

Autograft

Press-fit

Complications

## ABSTRACT

**Background:** This study aimed to compare the clinical and radiological outcomes of patients who underwent autograft application following standard transverse osteotomy supported by two cobalt-chrome cables with those who did not use autografts to support the osteotomy line in Crowe type IV Developmental Dysplasia of the Hip (DDH).

**Methods:** Sixty-nine patients (78 hips) with Crowe type IV DDH underwent a transverse subtrochanteric shortening osteotomy. In Group 1, 42 hips had their osteotomy site supported with an autograft harvested from the shortening osteotomy. Conversely, Group 2 consisted of 36 hips in which graft application was not performed, and fixation of the osteotomy site was solely achieved by employing the femoral stem. Clinical outcome measures included limb length discrepancy, pain (visual analog score), and functional **Harris Hip Score (HHS)**. For radiological evaluation, bone healing of the femoral osteotomy site was assessed using **the radiographic union score for tibial (mRUST)** classification, and stabilization of components was evaluated according to the Engh classification.

**Results:** There were no significant differences in age, body mass index, follow-up duration, preoperative and postoperative LLD, VAS score, and HHS values. No statistically significant difference was identified between the Engh classification. Significant differences between the groups were detected in the mRUST classification ( $p = 0.020$ ). The mean value of the group not utilizing autograft ( $11,89 \pm 1,83$ ) was higher than that of the group using autografts ( $10,95 \pm 1,59$ ). There was no statistically significant relationship between complications between the groups ( $p = 0.981$ ).

**Conclusion:** Performing of THA in Crowe type IV DDH, the press-fit application of the femoral component, without additional implantation or grafting, have shown comparable and satisfactory outcomes.

© 2025 The Japanese Orthopaedic Association. Published by Elsevier B.V. All rights are reserved, including those for text and data mining, AI training, and similar technologies.

## 1. Introduction

In Crowe type 4 cases, anatomical structures are inherently disrupted, with the femoral head displaced upwards and posteriorly, losing articulation with the acetabulum. Total hip arthroplasty (THA) is performed using various techniques for patients

presenting with such conditions [1,2]. Crowe type IV developmental dysplasia of the hip (DDH) treatment via total hip arthroplasty is a surgically intricate procedure owing to anatomical anomalies [2–4]. Precise preoperative planning is imperative to determine the optimal position of the acetabular component and the femoral neck osteotomy level [5]. Numerous researchers have advocated femoral shortening osteotomy during THA in these patients. This approach facilitates the mitigation of sciatic nerve injury, correction of inter-limb length discrepancy, and correction of femoral anteversion, thereby affording the possibility of addressing these concerns concomitantly [6–10].

Femoral shortening osteotomy is commonly executed as a transverse subtrochanteric shortening osteotomy (TSSO), although

<sup>☆</sup> This study was conducted at Kirsehir Ahi Evran University Department of Orthopedics and Traumatology.

\* Corresponding author. Istanbul University, Istanbul Faculty of Medicine, Department of Orthopedics and Traumatology, Millet Street No:118, Çapa, Fatih Istanbul 34093, Türkiye.

E-mail addresses: [dr.serkanbayram89@gmail.com](mailto:dr.serkanbayram89@gmail.com), [serkan.bayram@istanbul.edu.tr](mailto:serkan.bayram@istanbul.edu.tr) (S. Bayram).

oblique, double-chevron, and step-cut techniques are also viable [2,6,11–13]. The objective was to enhance the stability of osteotomies described in the literature for DDH. In all cases, an autograft was used to facilitate healing and contribute to stability. It has been demonstrated that increasing the length of the graft applied to the osteotomy site and reducing the osteotomy gap in Crowe type 4 hips have a positive effect on the rate of union [14]. Although autografts have been shown to have a positive effect on fracture healing, additional implant applications are required for fixation [2]. Depending on the graft application, the surgical time can be prolonged. There is limited literature showing the effect of a press-fit femoral stem applied without autograft on osteotomy healing when performing shortening osteotomy in Crowe type 4 hips.

The aim of this study was to investigate the effect of using the autograft obtained during shortening of the osteotomy area on radiological and clinical outcomes in patients with Crowe type 4 DDH who underwent TSSO. Our hypothesis was that autograft application to the osteotomy area is not mandatory in cases where the rectangular femoral stem is press-fit after TSSO. The initial group consists of individuals who received autograft placement within the typical TSSO area, reinforced by two CoCr cables. In contrast, the second group, utilizing the same components, involves the placement of the femoral component without the use of autografts to support the osteotomy line.

## 2. Method

This retrospective study analyzed the data of 96 patients who underwent transverse femoral shortening osteotomy and cementless total hip arthroplasty with a diagnosis of Crowe type IV congenital hip dislocation between January 2012 and January 2021. The study population comprised a retrospective analysis of total hip arthroplasties.

The cases evaluated in this study were performed by two senior surgeons who applied two different surgical techniques. The patients were divided into two groups according to the application of the autograft to the osteotomy site. Ninety-six patients diagnosed with Crowe type IV congenital hip dislocation underwent transverse femoral shortening osteotomy and cementless total hip arthroplasty at an orthopedics and traumatology clinic between January 2012 and January 2021. Two different surgeons operated on the patients. Difficult cases, such as Crowe type 4, are referred to surgeons in their local area, as they are senior surgeons in the field of arthroplasty. The cases in our study were performed at two different centers by two senior surgeons (M.F.C. and B.A.). The reason for the separation of the two different surgical techniques without randomization of the patients was the surgeon's preference.

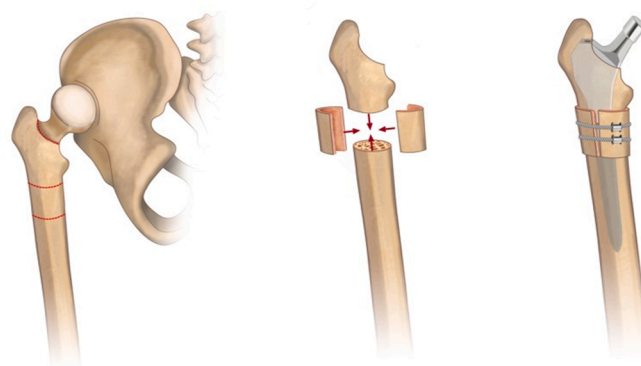
The inclusion criteria were patients diagnosed with Crowe type 4 hip, those who underwent total hip arthroplasty using the posterolateral or lateral approach with shortening osteotomy, individuals aged 18 years or older, patients with a minimum one-year follow-up, and those with accessible demographics and radiological data. The exclusion criteria included unmanaged neurological/psychiatric disorders, chronic renal insufficiency, uncontrolled diabetes mellitus, metabolic bone diseases, and patients who underwent surgery without shortening osteotomy in the postoperative period. After excluding participants who did not adhere to the predefined criteria, 69 were included in the study. Nine participants presented bilateral afflictions at distinct temporal intervals.

A total of 78 hip specimens were analyzed. In Group 1, 42 hips had their osteotomy site supported with an autograft harvested from the shortening osteotomy. Conversely, Group 2 consisted of

36 hips in whom graft application was not performed and fixation of the osteotomy site was solely achieved by employing the femoral stem. Prior to the surgery, demographic information, implant selection, and measurement planning were documented for all participants. Preoperative assessments included joint range of motion (ROM), pain scores measured using a Visual Analog Scale (VAS), lower limb length discrepancies (LLD), and Harris Hip Scores (HHS). Comprehensive information regarding the surgical procedures, rehabilitation, and treatment protocols was provided to the participants, and informed consent was obtained prior to the surgical procedure.

**Group 1 (autograft):** All participants included in the study were prepared for the operation by applying a lateral decubitus position under general anesthesia. Following the standard sterilization procedure, a posterolateral hip incision was made, and the skin and subcutaneous tissues were dissected. Subsequently, access to the hip joint was achieved using a posterior approach. After femoral neck resection, the reaming process was performed using a rectangular Rasp system. The true acetabulum was accessed from the cotyloid rim. Following the reaming procedure, a cementless porous-coated acetabular component (**REFLECTION SL Plus TM, Smith and Nephew, Memphis, USA**) was affixed with 2–3 screws, and a polyethylene liner was inserted. A dual-tapered rectangular femoral stem (SL-Plus; Smith & Nephew Inc., Memphis, TM, USA) was positioned within the proximal femur without entering the distal femoral canal. The patient was then seated in the acetabulum with the trial head. Osteotomy was performed on the distal femoral segment and distraction was applied to equalize the knee levels. Subsequently, the overlapping ends of the proximal and distal femoral fragments were aligned to determine the extent of the femoral shortening. The distal and proximal medullae were matched for implantation in the distal femur and femoral shaft. To this end, independent reaming was performed. Following the application of the femoral component, the removed segment was bisected longitudinally using two CoCr cables. The bifurcated graft was augmented to the osteotomy site using two cables. Soft tissue release was performed as required and reduced accordingly. Post-reduction, stability, and safe range of joint motion were examined. After ensuring hemostasis and applying drains, the capsule and soft tissues were closed, thus concluding the surgical procedure (**Fig. 1**).

**Group 2 (no graft):** identical surgical procedures were reiterated. The femoral component was implemented and hip reduction was performed. Subsequently, an examination of the secure range of joint motion was conducted, aided by fluoroscopy, and mobile stabilization was assessed using the same protocol, excluding the



**Figure 1.** The image provides a visual representation of the osteotomy line, along with the autograft augmented to the osteotomy line using two cables.

use of grafts and cables. Surgical intervention was performed following the protocol described above. (Fig. 2).

Postoperatively, on the 1st, second, and third days, standard inpatient assessments were conducted. Subsequently, evaluations were performed on the 10th and 20th days, at the sixth week, and at the 3rd, 6th, and 12th months following the surgery. Comprehensive outpatient follow-ups and assessments were also performed. Routine follow-up was performed annually.

Age, body mass index (BMI), and side of surgery were evaluated and compared between the groups. The temporal sequence and therapeutic course of complications arise within soft tissues (superficial wound infections, deep joint infections, hematomas, and tissue degradation). We evaluated the final control VAS and HHS values of the patients during the convalescent period. Disparities in extremity length were gauged through radiological assessments during the participants' final follow-up examinations. Bone healing of the femoral osteotomy site was assessed using **the radiographic union score for tibial (mRUST)** classification (formed by scoring cortical bone healing in four areas within a range of 1–4 points) [15]. The stabilization of components was evaluated according to the Engh classification, encompassing bone ingrowth/stable fibrous/osteolysis, loosening, or subsidence [16].

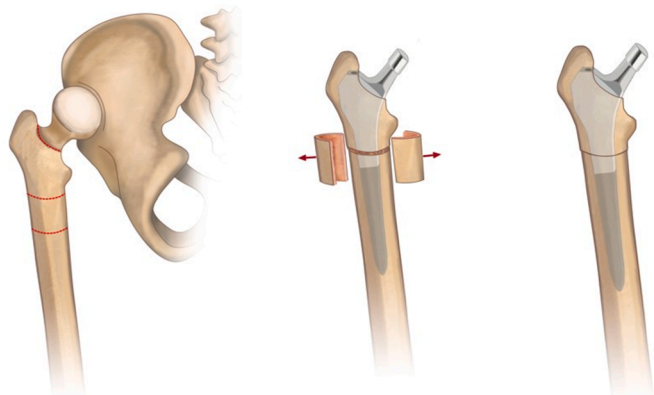
Ethical permission for the study was obtained from the ethics committee of the tertiary healthcare institution in which the researchers worked. The participants provided information regarding the research, and informed consent was obtained from all participants.

### 2.1. Statistical analyses

Analyses of research data were conducted using SPSS 26 software. Descriptive findings are presented as frequency, percentage, minimum/maximum values, mean, standard deviation, and median values. The average distribution compatibility of the data on variables was examined using the Shapiro-Wilk test. For the comparison of two independent groups, either the *t*-test or Mann-Whitney *U* test was performed. In analyzing two repeated measurements, recourse was made to the paired *t*-test or Wilcoxon Signed-Rank test. Relationships among categorical variables were explored using the chi-squared test. Statistical significance was set at a threshold of  $p < 0.05$ .

## 3. Results

The demographic data are presented in Table 1. There was a comparable distribution of age, BMI, follow-up duration,



**Figure 2.** The image illustrates the implantation of a femoral stem, a procedure which does not involve the use of grafts or cables.

preoperative and postoperative LLD, VAS, and HHS values, with no significant differences observed between them. Similarly, among participants in whom autografts were utilized, the mean preoperative LLD ( $4.28 \pm 0.86$ ) was higher than the mean postoperative LLD ( $0.65 \pm 0.39$ ). Disparities in average length were statistically significant ( $p < 0.001$ ).

The preoperative and postoperative LLD, HHS, and VAS scores were compared between the groups. There was no statistically significant difference between these variables pre- and postoperatively (Table 2).

The values obtained from the groups were comparable with respect to Engh Classification. No statistically significant correlations were identified between these variables. While stable fibrosis was observed in one patient in both groups, bony growth was observed in all other patients. Significant differences between the groups were detected in the mRUST classification ( $p = 0.046$ ). The mean value of the group not utilizing autograft ( $11,89 \pm 1,83$ ) was higher than that of the group employing autografts ( $10,95 \pm 1,59$ ) (Table 3). There is no statistically significant relationship regarding complications between the groups ( $p = 0.981$ ). In the group where autograft was employed, three cases of femoral cracks were identified, whereas in the group where autograft was not utilized, five cases were observed, resulting in a total of eight participants affected. In these instances, intraoperative cable fixation sufficed for stabilization, rendering additional implant or graft intervention unnecessary (Fig. 3). Within the group not utilizing grafts, two cases of dislocation, one of hematoma necessitating surgical site drainage, and two cases of prolonged serous discharge were identified. One dislocation was treated after closed reduction, whereas the other required revision with a dual-mobility acetabular cup. In the autograft-utilizing group, two cases of dislocation, one case of non-union at the femoral osteotomy site, and two cases of prolonged serous discharge were observed. Both dislocations were resolved by closed reduction. The patient with nonunion at the osteotomy site underwent femoral stem revision for treatment.

Nine patients in the general patient population underwent bilateral procedures at different times. When participants were analyzed unilaterally and bilaterally, no statistically significant differences were found between the two groups in terms of the HHS, VAS, and mRUST score parameters.

## 4. Discussion

Intraoperative adjustment of anteversion simultaneously with the femoral shortening procedure is technically more feasible during TSSO. Hence, although TSSO is considered a more advantageous technique, its stability remains subject to inquiry [6,17]. Osteotomies, such as the stepped and double chevron techniques, are theoretically more stable owing to the potential to achieve rotational stability through rectangular femoral stems. Nevertheless, the clinical outcomes align closely with those obtained from our patient cohorts subjected to TSSO procedure [6,13]. Healing at the osteotomy site was notably successful radiologically and clinically in both study cohorts. Consequently, the clinical and functional scores, radiological measurements, and complications within both groups concur with the existing literature. Based on the data acquired from our study, it can be deduced that TSSO is a stable and reliable osteotomy technique. The results from the literature are summarized in Table 4. When examining the healing status within the osteotomy site in both groups, a significant disparity was observed in the radiological mRUST classification scores. Kawai et al. [9] showed that the length of the applied autograft had positive effects on healing in Crowe type 4 hips. The

**Table 1**  
Comparison of patient demographics between patients with and without autograft.

	Patients with autograft (n: 42)		Patients without autograft (n: 36)		Total	p value
	Mean ± SD	Min – Max	Mean ± SD	Min – Max		
Age, years	42.6 ± 5.4	33–61	43.5 ± 6.6	33–61	43.05	0.809
Gender, Female/Male	36/6		32/4		68/10	0.745
Bilateral, Yes/No	10/32		8/28		18/60	1
Side, Right/Left	22/20		21/15		43/35	0.765
Body mass index, kg/m <sup>2</sup>	28.9 ± 4.5	21–38	29.6 ± 5	21–38	29.2	0.519
Follow-up, months	48.6 ± 19	14–94	51.7 ± 17	28–94	49.9	0.443

SD: Standard deviation; Min: Minimum; Max: Maximum.

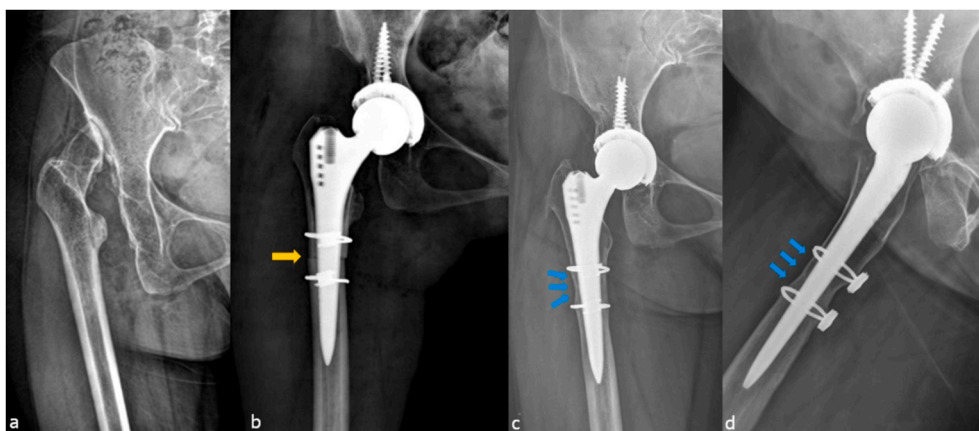
**Table 2**  
Comparison of groups in terms of pre-op and post-op LLD, HSS and VAS values.

	Patients with autograft (n: 42)		Patients without autograft (n: 36)		Total	p value
	Mean ± SD	Min – Max	Mean ± SD	Min – Max		
Preoperative LLD, cm	4.28 ± 0.86	2.8–6.2	4.45 ± 0.92	3.3–6.2	4.36	0.467
Postoperative LLD, cm	0.65 ± 0.39	0–1.6	0.71 ± 0.45	0–1.6	0.68	0.597
p value	<0.001		<0.001			
Preoperative HHS	38.8 ± 8.5	22–60	41.4 ± 9.3	22–60	40.07	0.123
Postoperative HHS	81.9 ± 8.1	56–94	83 ± 9.6	42–94	82.4	0.333
p value	<0.001		<0.001			
Preoperative VAS	7.1 ± 1.1	4–9	7 ± 1.2	4–9	7.06	0.696
Postoperative VAS	2.17 ± 1.4	0–7	2.53 ± 1.2	0–6	2.33	0.171
p value	<0.001		<0.001			

HHS: Harris Hip Score; SD: Standard deviation; Min: Minimum; Max: Maximum.

**Table 3**  
Comparison of osteotomy healing, Engb Classification, mRUST score and complication between the groups.

	Patients with autograft (n: 42)		Patients without autograft (n: 36)		Total	p value
	Mean ± SD	Min – Max	Mean ± SD	Min – Max		
Osteotomy healing time	Complete	41	36		77	0.351
	Delayed (>6 months)	1	0		1	
Engb Classification	Bony in Growth	40	34		74	0.988
	Stable fibrosis	1	1		2	
	Loosening	1	1		2	
mRUST Score	10.95 ± 1.5	6–14	11.89 ± 1.8	9–16	11.38	0.020*
Complications, Yes	7		5		12	0.735



**Figure 3.** Radiographs of a 44-year-old woman with Crowe type IV developmental dysplasia of the right hip: (a) Preoperative anteroposterior view. (b) Early postoperative anteroposterior radiographs, highlighting the use of cables in the context of intraoperative femur fractures. The yellow arrow indicates the osteotomy line. (c, d) Three years after the first surgery, anteroposterior and lateral radiographs. The blue arrows indicate primary endosteal healing along the osteotomy line without the use of autograft. (For interpretation of the references to colour in this figure legend, the reader is referred to the Web version of this article.)

**Table 4**  
Previously reported outcomes of total hip arthroplasty in crowe type 4 dysplastic hips.

	Patients/Hips	Age	Follow-up (y)	HHS		LLD		Intraoperative Femoral Fracture/ Femoral Crack Rate	Complication
				Pre-op	Post-op	Pre-op	Post-op		
Ollivier et al. (23)	24/28	48	10	43	87	4.3	0.6	17.8/-	Severe limp 4 Dislocation 1 Peri-protetic fracture 2
Mu et al. (24)	58/71	35.8	5.8	35.6	82.9	4.1	1	28.1/-	Dislocation 2 Intraop FF 19 SNI 2 FNI 6
Zeng et al. (25)	45/52	40.6	9.8	33.7	89.8	4.3	0.7	-/-	Dislocation 2 SNI 2 venous thrombosis 3
Wang et al. (26)	62/76	38.8	10	38.8	86.1	4.3	1	5.2/-	Dislocation 3 Intraop FF 4 SNI 2 Trendelenburg sign 2
Li et al. (27)	18/22	53	6.5	47	88	4.5	1.5	-/-	Intraop FF 3 SNI 1
Eskelinen et al. (18)	56/68	54	12.3	54.2	83.9	3.5	1.2	-/5.8	Dislocation 2 PNP 3 FNP 3
Örs et al. (2)	91/127	43	8.4	33.7	94.2	5	1.3	2.3/55.1	Superficial wound infection 1 Dislocation 5 Intraop FF 3 PJI 3
Chang et al.	28/33	36.6	10.1	47	89.6	5	1.3	-/0.6	Intraop FF 2 Dislocation 3 SNI 2 venous thrombosis 3
Cakmak et al. (present study)	69/78	43.0	4.1	41.4	83.0	4.4	0.7	-/10.2	Intraop FF 8 Dislocation 4 Hematoma 1 Superficial wound infection 4 Non-union 2

Intraop FF: intraoperative femoral fracture.

SNI: sciatic **nerve** injury.

FNI: femoral nerve injury.

PNI: peroneal nerve injury.

PJI: periprosthetic joint infection.

results of our study indicate that healing in the osteotomy area was achieved to a similar extent in both the groups.

According to the mRUST classification, the group that did not use grafts exhibited higher scores. The absence of the remodeling phase, as defined by the presence of calli, was more pronounced in the group where grafts were not employed. The noted score discrepancy is believed to stem from the non-graft-utilizing group receiving a score of four for each cortex [15]. In cases where the osteotomy line is identified through a press-fit femoral stem in a compressive manner, it consolidates directly through primary endosteal bone healing. This phenomenon facilitates fracture healing without callus formation. These observations were substantiated by both the numerical outcomes and radiological imagery. In numerous instances, the fracture line directly undergoes endosteal healing, leading to healing without autograft integration. Consequently, in cases where the proximal and distal segments are deemed stable following component application, autograft intervention is deemed unnecessary for fracture healing.

In cases where the osteotomy site is stabilized with a femoral stem, utilization of the graft leads the osteotomy site to progress towards endosteal healing. Integration of the graft into this site occurs either belatedly or not at all. In this scenario, the current use of cables augments the implant load within the osteotomy site. This augmentation consequently leads to osteolysis in the cortical bone of the femoral shaft in the long term. Perren et al. have also postulated that the use of tension cables disrupts periosteal circulation in sound bone and induces lysis in the bone [18]. Yıldırım et al. conducted THA using TSSO in 61 out of 102 hip joints afflicted with coxarthrosis within the context of DDH [19]. Similar to our

study, patients who underwent shortening osteotomy had rectangular stems. Implementing a rectangular stem underscored the attainment of stability in both the proximal and distal segments. The same study did not employ cables, implants, or autografts for osteotomy site fixation. Delayed healing was observed in three patients. This study yielded successful outcomes that supporting our hypothesis.

Reikeraas et al. conducted a study involving 25 cases of developmental DDH [20]. Cemented stems were applied in four cases, while 21 cases received press-fit femoral stems and were followed without autografts or additional fixation. While delayed healing was observed in only one patient, no instances of mechanical insufficiency were recorded across the cases. Similar to our study, the substantial improvement in average HHS values supports the notion that grafting and implantation may not be imperative. Similarly, in a case series of TSSO performed without autografts by Götze et al., encompassing seven patients, one participant exhibited stem loosening after an average follow-up of 15 months. As depicted in our study series, rectangular SI-plus stems in TSSO advocate the necessity of supplementary implants for osteotomy fixation and autografts [21]. Our study found no significant difference in VAS values between the two groups. Both cohorts exhibited elevated contentment levels in the general assessment of the participants and the examination of the osteotomy site. No significant difference was observed between the groups regarding the preoperative and postoperative HHS values. Statistically significant improvement was observed when the preoperative and postoperative HHS values were compared within each group. These obtained findings are consistent with the

existing literature [2,17,22–26]. The functional scores of the two cases of dislocation in our study were notably low. Nevertheless, the cases that we primarily investigated were not associated with osteotomy healing issues. The dislocation rate identified in our study is consistent with the literature [22,25–28].

The literature concerning intraoperative femur fractures is extensive [22,23,25,26]. In our study, non-displaced intraoperative fractures in the distal femur were observed in eight participants. This finding aligns with that in the existing literature. These participants were fixed with cables distally and proximally and encountered no complications during follow-up. A similar procedure was routinely performed by Örs et al. [2] involving controlled fractures distal to the osteotomy site, and it was noted to have a positive impact on osseointegration. We also believe that additional issues did not arise with intraoperative identification in these cases. Whether occurring as a complication or intentionally, we believe that applying an extra cable to secure the distal part of the osteotomy site and to maintain control over the fracture line would suffice. We believe that supplementary autograft application is unnecessary when a stable femoral stem is present. In participants with unilateral DDH, the mean values of LLD were  $4.36 \pm 0.8$  cm preoperatively and  $0.68 \pm 0.4$  cm postoperatively in participants with unilateral DDH. No significant difference in limb length was observed after surgery in participants with bilateral DDH. This finding is consistent with the existing literature [3,17,22,26].

Our study has certain limitations. First, this study was a retrospective evaluation of prospectively followed up patients. Second, the follow-up duration remains limited, despite our cohort encompassing a relatively extensive patient series with a rare diagnosis. Comprehensive outcomes can be derived from long-term follow-up studies of intricate surgeries. **Another limitation, only rectangular stem used due to availability.** To obtain more refined data from our cohort, follow-up of the case series within the study is still ongoing.

## 5. Conclusion

For patients with Crowe type IV Developmental Dysplasia of the Hip (DDH), Total Hip Arthroplasty (THA) utilizing the SL-plus femoral component along with autograft augmentation has proven to be a dependable and successful treatment option. Similarly, THA procedures that employ a press-fit technique with the same component, without the need for additional implants or grafts, have yielded equally satisfactory results. Therefore, it can be concluded that when intraoperative stability is achieved through the press-fit method of the femoral stem, the use of autografts and extra implants may not be necessary. This strategy reduces the implant burden on patients, potentially offering benefits in terms of time efficiency and cost-effectiveness.

## Ethics approval

Ethics committee approval was obtained before starting the study.

## Consent for publication

Participants agree to the publication of information about them.

## Data availability statement

The data of study will be made available on reasonable request.

## Funding statement

None.

## Declaration of competing interest

None of the authors has any conflict of interest to disclose.

## Acknowledgement

We would like to express our gratitude to Mehmet Akan for his invaluable technical assistance.

## References

- [1] Crowe JF, Mani VJ, Ranawat CS. Total hip replacement in congenital dislocation and dysplasia of the hip. *J Bone Joint Surg Am* 1979 Jan;61(1):15–23.
- [2] Ors C, Caylak R, Togrul E. Total hip arthroplasty with the wagner cone femoral stem in patients with Crowe IV developmental dysplasia of the hip: a retrospective study. *J Arthroplasty* 2022 Jan;37(1):103–9.
- [3] Togrul E, Ozkan C, Kalaci A, Gülşen M. A new technique of subtrochanteric shortening in total hip replacement for Crowe type 3 to 4 dysplasia of the hip. *J Arthroplasty* 2010 Apr;25(3):465–70.
- [4] Bao N, Meng J, Zhou L, Guo T, Zeng X, Zhao J. Lesser trochanteric osteotomy in total hip arthroplasty for treating CROWE type IV developmental dysplasia of hip. *Int Orthop* 2013 Mar;37(3):385–90.
- [5] Decking J, Decking R, Schoellner C, Fuerderer S, Rompe JD, Eckardt A. Cementless total hip replacement with subtrochanteric femoral shortening for severe developmental dysplasia of the hip. *Arch Orthop Trauma Surg* 2003 Sep;123(7):357–62.
- [6] Sener N, Tözün IR, Aşık M. Femoral shortening and cementless arthroplasty in high congenital dislocation of the hip. *J Arthroplasty* 2002 Jan;17(1):41–8.
- [7] Masonis JL, Patel JV, Miu A, Bourne RB, McCalden R, Macdonald SJ, et al. Subtrochanteric shortening and derotational osteotomy in primary total hip arthroplasty for patients with severe hip dysplasia: 5-year follow-up. *J Arthroplasty* 2003 Apr;18(3 Suppl 1):68–73.
- [8] Takao M, Ohzono K, Nishii T, Miiki H, Nakamura N, Sugano N. Cementless modular total hip arthroplasty with subtrochanteric shortening osteotomy for hips with developmental dysplasia. *J Bone Joint Surg Am* 2011 Mar 16;93(6):548–55.
- [9] Kawai T, Tanaka C, Ikenaga M, Kanoe H. Cemented total hip arthroplasty with transverse subtrochanteric shortening osteotomy for Crowe group IV dislocated hip. *J Arthroplasty* 2011 Feb;26(2):229–35.
- [10] Park MS, Kim KH, Jeong WC. Transverse subtrochanteric shortening osteotomy in primary total hip arthroplasty for patients with severe hip developmental dysplasia. *J Arthroplasty* 2007 Oct;22(7):1031–6.
- [11] Zagra L, Bianchi L, Mondini A, Ceroni RG. Oblique femoral shortening osteotomy in total hip arthroplasty for high dislocation in patients with hip dysplasia. *Int Orthop* 2015 Sep;39(9):1797–802.
- [12] Kiliçoğlu Ö, Türker M, Akgül T, Yazıcıoğlu O. Cementless total hip arthroplasty with modified oblique femoral shortening osteotomy in Crowe type IV congenital hip dislocation. *J Arthroplasty* 2013 Jan;28(1):117–25.
- [13] Becker DA, Gustilo RB. Double-chevron subtrochanteric shortening derotational femoral osteotomy combined with total hip arthroplasty for the treatment of complete congenital dislocation of the hip in the adult. Preliminary report and description of a new surgical technique. *J Arthroplasty* 1995 Jun;10(3):313–8.
- [14] Kawai T, Goto K, Kuroda Y, Matsuda S. Total Hip Arthroplasty Combined With Subtrochanteric Transverse Shortening Osteotomy: Factors Associated With Delayed Union at the Osteotomy Site. *J Am Acad Orthop Surg Glob Res Rev* 2020 Aug;4(8):e20.00056.
- [15] Fisher JS, Kazam JJ, Fufa D, Bartolotta RJ. Radiologic evaluation of fracture healing. *Skeletal Radiol* 2019 Mar;48(3):349–61.
- [16] Engh CA, Bobyn JD, Glassman AH. Porous-coated hip replacement. The factors governing bone ingrowth, stress shielding, and clinical results. *J Bone Joint Surg Br* 1987 Jan;69(1):45–55.
- [17] Eskelinen A, Helenius I, Remes V, Ylinen P, Tallroth K, Paavilainen T. Cementless total hip arthroplasty in patients with high congenital hip dislocation. *J Bone Joint Surg Am* 2006 Jan;88(1):80–91.
- [18] Perren SM, Fernandez Dell'oca A, Regazzoni P. Fracture Fixation Using Cerclage, Research Applied to Surgery. *Acta Chir Orthop Traumatol Cech* 2015;82(6):389–97.
- [19] Yildirim T, Guclu B, Karagüven D, Kaya A, Akan B, Cetin I. Cementless total hip arthroplasty in developmental dysplasia of the hip with end stage osteoarthritis: 2–7 years' clinical results. *Hip Int* 2015 Sep–Oct;25(5):442–6.
- [20] Reikeraas O, Lereim P, Gabor I, Gunderson R, Bjerkreim I. Femoral shortening in total arthroplasty for completely dislocated hips: 3–7 year results in 25 cases. *Acta Orthop Scand* 1996 Feb;67(1):33–6.
- [21] Götze C, Winkelmann W, Gosheger G, Rödl R. Erfordert die transverse Osteotomie bei der subtrochantären Femurverkürzungsosteotomie in der

- Hüftprothesenimplantation hoher Dysplasiekoxarthrosen eine additive Osteosynthese? Kurzfristige Erfahrung bei 7 Hüften mit kongenitaler Luxation [Is there a need of an additional extramedullary fixation in transverse subtrochanteric shortening in primary total hip arthroplasty for patients with severe hip dysplasia? Short-term experience in seven patients with congenital dislocation]. *Z Orthop Unfall* 2007 Sep-Oct;145(5):568–73.
- [22] Ollivier M, Abdel MP, Krych AJ, Trousdale RT, Berry DJ. Long-term results of total hip arthroplasty with shortening subtrochanteric osteotomy in Crowe IV developmental dysplasia. *J Arthroplasty* 2016 Aug;31(8):1756–60.
- [23] Mu W, Yang D, Xu B, Mamtimin A, Guo W, Cao L. Midterm outcome of cementless total hip arthroplasty in Crowe IV-Hartofilakidis type III developmental dysplasia of the hip. *J Arthroplasty* 2016 Mar;31(3):668–75.
- [24] Zeng WN, Liu JL, Wang FY, Zhang X, Fan HQ, Chen GX, et al. Total hip arthroplasty for patients with Crowe type IV developmental dysplasia of the hip: Ten years results. *Int J Surg* 2017 Jun;42:17–21.
- [25] Wang D, Li LL, Wang HY, Pei FX, Zhou ZK. Long-term results of cementless total hip arthroplasty with subtrochanteric shortening osteotomy in Crowe type IV developmental dysplasia. *J Arthroplasty* 2017 Apr;32(4):1211–9.
- [26] Li X, Lu Y, Sun J, Lin X, Tang T. Treatment of Crowe type-IV hip dysplasia using cementless total hip arthroplasty and double chevron subtrochanteric shortening osteotomy: A 5- to 10-year follow-up study. *J Arthroplasty* 2017 Feb;32(2):475–9.
- [27] Oe K, Iida H, Nakamura T, Okamoto N, Wada T. Subtrochanteric shortening osteotomy combined with cemented total hip arthroplasty for Crowe group IV hips. *Arch Orthop Trauma Surg* 2013 Dec;133(12):1763–70.
- [28] Altay M, Demirkale İ, Çatma MF, Karaduman M. Results of Crowe type IV developmental dysplasia of hip treated by subtrochanteric osteotomy and total hip arthroplasty. *Indian J Orthop* 2018 Jul-Aug;52(4):374–9.