

# Acute otitis media associated with Gradenigo syndrome and transverse sinus thrombosis: a case report

Journal of International Medical Research

2019, Vol. 47(3) 1348–1352

© The Author(s) 2019

Article reuse guidelines:

[sagepub.com/journals-permissions](http://sagepub.com/journals-permissions)

DOI: 10.1177/0300060518823404

[journals.sagepub.com/home/imr](http://journals.sagepub.com/home/imr)**Sercan Özkaçmaz** 

## Abstract

Gradenigo syndrome is associated with middle ear infection that extends to the petrous apex, leading to pain at the innervation site of the ophthalmic and maxillary branches of the trigeminal nerve and the development of abducens nerve palsy. Cerebral venous sinus thrombosis is a serious neurological complication of otitis media and occurs secondary to spread of the infection to the underlying bone. We herein report a pediatric case of otitis media associated with Gradenigo syndrome and ipsilateral sigmoid–transverse sinus thrombosis with magnetic resonance imaging findings.

## Keywords

Gradenigo syndrome, transverse sinus thrombosis, magnetic resonance imaging, otitis media, petrous apex, abducens nerve

Date received: 4 October 2018; accepted: 14 December 2018

## Introduction

Gradenigo syndrome is characterized by otitis media, pain in the region innervated by the first and second branches of the trigeminal nerve, and ipsilateral abducens nerve palsy. The condition occurs secondary to extension of inflammation from the middle ear to the petrous apex and tissues close to the cranial nerves. Cerebral sinus venous thrombosis is an important complication of otitis media that usually spreads via underlying bone tissue.<sup>1</sup>

Gradenigo syndrome is a rare complication of otitis media with various causes and requires special attention for a correct diagnosis. We herein report a pediatric case of

---

Kırşehir Ahi Evran University, Kırşehir, Turkey

### Corresponding author:

Sercan Özkaçmaz, Department of Radiology, Faculty of Medicine, Kırşehir Ahi Evran University, Kırşehir 40100, Turkey.

Emails: [Sercanozkacmaz@hotmail.com](mailto:Sercanozkacmaz@hotmail.com);

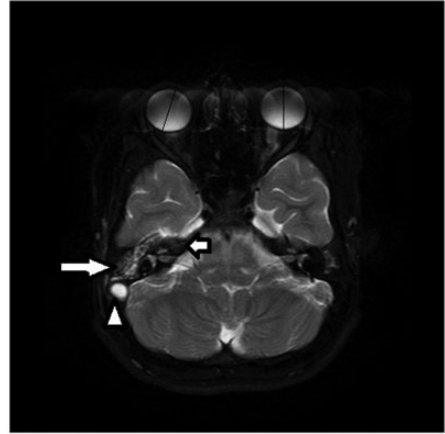
[drsercanozkacmaz@gmail.com](mailto:drsercanozkacmaz@gmail.com)



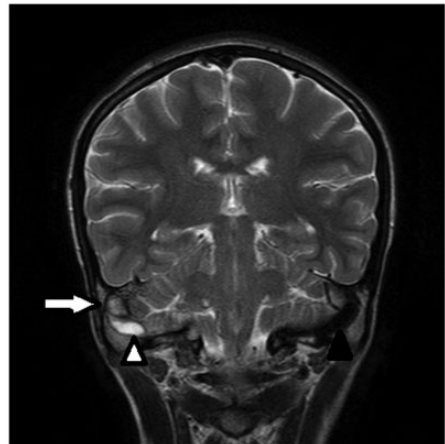
otitis media associated with right-sided Gradenigo syndrome and ipsilateral sigmoid–transverse sinus thrombosis with magnetic resonance imaging (MRI) findings. The presence of Gradenigo syndrome indicates that a middle ear infection has spread to the petrous apex and is becoming more serious. Awareness of this condition will allow for early detection and treatment of serious complications of otitis media. Additionally, this report emphasizes the importance of MRI for the diagnosis of complications of otitis media.

### Case presentation

A 14-year-old girl was admitted to the emergency department with a 2-week history of right-sided otorrhea and headache and a 2-day history of diplopia. She had also developed vomiting and confusion immediately before admission. Her medical history was unremarkable. Physical examination revealed perforation and hyperemia of the tympanic membrane of her right ear and ipsilateral abducens nerve palsy (paralysis of the lateral rectus muscle). Neck stiffness, right mastoid tenderness, and a body temperature of 39.1°C were also detected. Laboratory examination revealed a high white cell count of  $16.4 \times 10^3/\text{mm}^3$ , high C-reactive protein level of 16.2 mg/L, and high erythrocyte sedimentation rate of 71 mm/h. Due to the abducens paralysis and neck stiffness, the patient underwent contrast-enhanced cranial MRI with a 1.5 Tesla MRI system (Intera; Philips Medical Systems, Best, The Netherlands) for detection of possible neurological complications of acute otitis media. An axial fat-suppressed T2-weighted image showed increased signal intensity in the middle ear and petrous apex (Figure 1). A coronal T2-weighted image demonstrated right sigmoid sinus thrombosis and hyperintense right mastoid cells, which are compatible with mastoiditis (Figure 2). A coronal



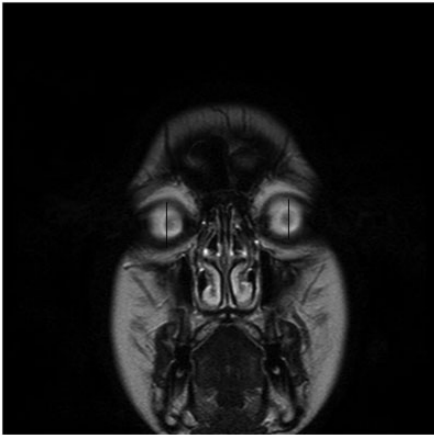
**Figure 1.** An axial fat-suppressed T2-weighted image shows increased signal intensity in the middle ear (long arrow) and petrous apex (short arrow) when compared with the normal contralateral side. Hyperintensity is also seen in the lumen of the right sigmoid sinus, which is consistent with thrombus formation (white arrowhead). Medial deviation of the right globe is present (lines), suggesting ipsilateral abducens nerve palsy.



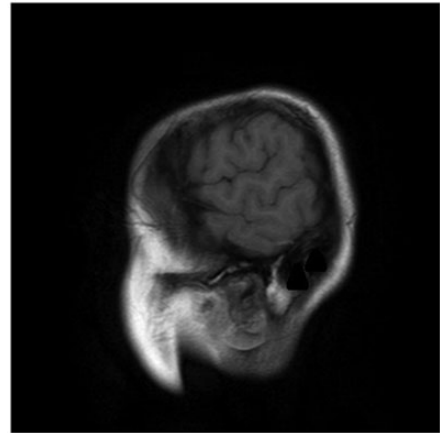
**Figure 2.** A coronal T2-weighted image demonstrates a right sigmoid sinus thrombus (white arrowheads) and hyperintense right mastoid cells (long arrow), which are compatible with mastoiditis. An intact left transverse sinus with void signals is also seen (black arrowhead).

T2-weighted image showed medial deviation of the right globe secondary to cranial nerve VI palsy (Figure 3). Sagittal non-enhanced T1-weighted images demonstrated a hyperintense right transverse sinus, which is consistent with complete obstruction by a thrombus (Figure 4), and a

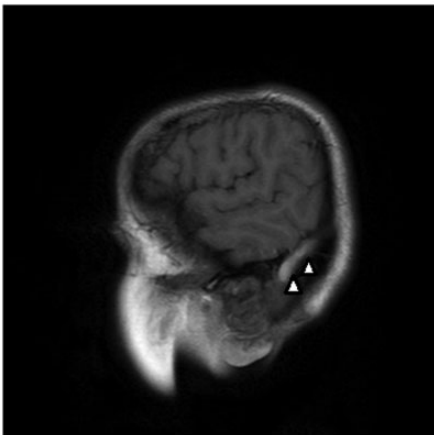
normal left transverse sinus with flow voids (Figure 5). Contrast-enhanced images confirmed complete obstruction of the lumens of the right sigmoid–transverse sinuses by a thrombus (Figures 6, 7) and abnormal



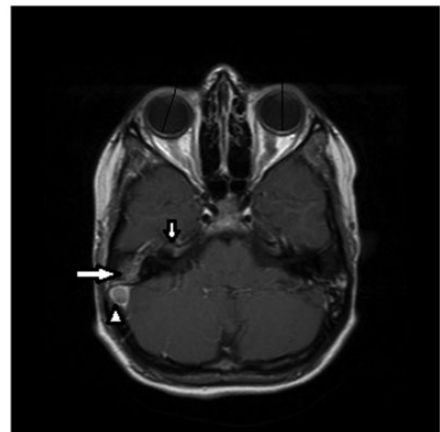
**Figure 3.** A coronal T2-weighted image shows medial deviation of the right globe secondary to cranial nerve VI palsy (lines).



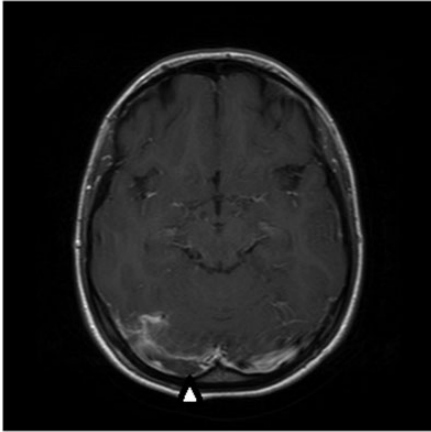
**Figure 5.** A sagittal non-enhanced T1-weighted image demonstrates an intact left transverse sinus with normal signal voids (black arrowheads).



**Figure 4.** A sagittal non-enhanced T1-weighted image demonstrates a hyperintense right transverse sinus, which is consistent with total thrombosis (white arrowheads).



**Figure 6.** An axial contrast-enhanced T1-weighted image demonstrates hypointense clot formation within the lumen of the right transverse sinus (white arrowhead) and enhancement of the right middle ear (long arrow) and petrous apex (short arrow). Medial deviation of the right globe is also seen (lines).



**Figure 7.** An axial contrast-enhanced T1-weighted image shows hypointense clot formation within the lumen of the right transverse sinus (white arrowhead). Abnormal collaterals are seen close to the proximal segment of the right transverse sinus.

collaterals (Figure 7). The images also showed opacification of the right mastoid cells and right petrous apex, which are suggestive of inflammation (Figure 6). Based on these clinical and laboratory findings, a diagnosis of Gradenigo syndrome with cerebral venous sinus thrombosis caused by otitis media was made. Intravenous antibiotic therapy with ceftriaxone and anticoagulant therapy were started. The abducens nerve palsy and clinical findings had totally disappeared 1 week after beginning treatment. The sinus venous thrombosis had regressed by day 15 after beginning treatment, and the clot was completely resolved 2 months later.

Informed consent was obtained from the patient's parents. Ethics committee approval was not required because of the study design (case report).

## Discussion

Gradenigo syndrome is an uncommon complication of middle ear infection characterized by otitis media, pain in the innervation

region of the ophthalmic and maxillary branches of the trigeminal nerve, and ipsilateral abducens nerve palsy.<sup>1,2</sup> The spread of inflammation from the middle ear to the petrous apex, which is close to Dorello's canal and Meckel's cave, affects the abducens nerve and the ophthalmic and maxillary branches of the trigeminal nerve. This leads to pain in the retro-orbital region, which is innervated by these branches of the trigeminal nerve, and to palsy of the rectus lateralis muscle, which is innervated by the abducens nerve.<sup>3</sup>

Another serious complication of otitis media is cerebral venous sinus thrombosis. The transverse sinus is most commonly affected. Spread of the infection to the sigmoid part through a dehiscence in the underlying bone is the suggested mechanism of transverse sinus thrombosis.<sup>4</sup>

Gradenigo syndrome with cerebral venous sinus thrombosis has been rarely reported.<sup>1,4,5</sup> Contrast-enhanced MRI is essential for the detection of neurological complications such as Gradenigo syndrome and cerebral venous thrombosis. The radiological findings of Gradenigo syndrome are increased signal intensity of the petrous apex; enhanced thickening of the meninges extending into the right internal auditory meatus, Meckel's cave, and region of Dorello's canal; and thickening of the trigeminal nerve.<sup>4,6</sup> MRI and magnetic resonance venography are the modalities with which to detect thrombus formation in the lumen of the cerebral venous sinuses.

## Conclusion

MRI is very important for detection of the complications of otitis media. Contrast-enhanced MRI and magnetic resonance venography must be immediately performed in patients with neurological symptoms such as nerve palsy, neck stiffness, or confusion.

### Declaration of conflicting interest

The authors declare that there is no conflict of interest.

### Funding

This research received no specific grant from any funding agency in the public, commercial, or not-for-profit sectors.

### ORCID iD

Sercan Özkaçmaz  <http://orcid.org/0000-0002-9245-0206>

### References

1. Scardapane A, Del Torto M, Nozzi M, et al. Gradenigo's syndrome with lateral venous sinus thrombosis: successful conservative treatment. *Eur J Pediatr* 2010; 169: 437–440. DOI 10.1007/s00431-009-1047-4
2. Chole RA and Donald PJ. Petrous apicitis: clinical considerations. *Ann Otol Rhinol Laryngol* 1983; 92: 544–551.
3. Janjua N, Bajalan M, Potter S, et al. Multidisciplinary care of a paediatric patient with Gradenigo's syndrome. *BMJ Case Rep* 2016; 2016: bcr2015214337. DOI: 10.1136/bcr-2015-214337
4. Valles JM and Fekete R. Gradenigo syndrome: unusual consequence of otitis media. *Case Rep Neurol* 2014; 6: 197–201. DOI: 10.1159/000365843
5. Colpaert C, Van Rompaey V, Vanderveken O, et al. Intracranial complications of acute otitis media and Gradenigo's Syndrome. *B-ENT* 2013; 9: 151–156.
6. Khurshid R, ul Islam M, Islam S, et al. Gradenigo's syndrome: a report of two cases with review of literature. *Internet J Otorhinolaryngol* 2009; 12(2).