



Tractography analysis results of the trigeminus nerve, which contains fibers responsible for proprioception sensation and motor control in Adolescent Idiopathic Scoliosis

Ahmet Payas¹ · Fatih Çiçek² · Yakup Ekinci³ · Sabri Batın³ · Şule Göktürk⁴ · Yasin Göktürk⁴ · Caner Karartı⁵ · İlyas Uçar⁶

Received: 13 June 2024 / Revised: 13 June 2024 / Accepted: 9 October 2024 / Published online: 18 October 2024
© The Author(s), under exclusive licence to Springer-Verlag GmbH Germany, part of Springer Nature 2024

Abstract

Study Design Cross-sectional Study.

Background It is not yet clear whether the loss of proprioceptive sensation and muscle weakness seen in adolescent idiopathic scoliosis (AIS) is the result of central nervous system dysfunction or secondary to spinal deformity. In our study, in order to find an answer to this question, we examined the microarchitecture of the nervus trigeminus, which is least affected by spinal deformity and contains both proprioceptive sensory and motor fibers.

Methods In this single-center, cross-sectional cohort study, 40 Lenke Type 3 (27 female, 13 male) AIS patients and 40 (25 female, 15 male) healthy individuals between the ages of 10–18 years. Tractography of the nervus trigeminus was performed using the “DSI Studio” program. The volumes of the targeted musculus pterygoideus lateralis and musculus pterygoideus medialis were measured using the Insight Segmentation and Registration Tool Kit (ITK -SNAP) program. The data were evaluated using the Statistical Package for the Social Sciences 22.0 program for Windows.

Results There was no significant difference between the two groups in terms of baseline characteristics ($p > 0.05$). Left nervus trigeminus fiber number and fiber ratio were significantly higher in the control group compared to the scoliosis group $p < 0.05$. Right and left lateral pterygoid muscle showed lower volume and volume percentage in the scoliosis group compared to the control group ($p < 0.05$).

Conclusion According to the study data, proprioceptive sensory and motor control dysfunction in AIS is predicted to develop independently of spinal deformity.

Keywords Scoliosis · Tractography · Etiology · Brain · Cranial nerve · Magnetic resonance images

Abbreviations

AIS	Adolescent Idiopathic Scoliosis
ITK –SNAP	Insight Segmentation and Registration Tool Kit
CNS	Central Nervous System
MRI	Magnetic Resonance Images
DTI	Diffusion Tensor Imaging
AD	Axial diffusivity
FA	Fractional anisotropy
DTI	Diffusion tensor imaging
MD	Mean diffusivity
RD	Radial diffusivity

✉ İlyas Uçar
ilyas.ucar@erciyes.edu.tr

¹ Faculty of Medicine, Department of Anatomy, Amasya University, Amasya, Turkey

² Faculty of Medicine, Department of Anatomy, Niğde Ömer Halisdemir University, Niğde, Turkey

³ Kayseri City Education and Training Hospital, Orthopedics and Traumatology Department, Kayseri, Turkey

⁴ Kayseri City Education and Training Hospital Brain and Nerve Surgery Department, Kayseri, Turkey

⁵ School of Physicaltherapy and Rehabilitation, Ahi Evran University, Kırşehir, Turkey

⁶ Faculty of Medicine, Department of Anatomy, Erciyes University, No:4/3 PK, Kayseri 38100, Turkey

Introduction

The etiology of adolescent idiopathic scoliosis (AIS), a complex three-dimensional deformity of the spine, is still unclear, although it has received continuous attention [1]. There are various theories trying to explain the pathogenesis of AIS. These theories include genetic, neurologic and environmental factors, spinal biomechanics, hormones and biochemical events [2].

One of the most important theories explaining the pathogenesis of AIS is undoubtedly central nervous system (CNS) anomaly [3]. It has been found that there are anomalies in some CNS regions such as cerebrum, brainstem, corpus callosum, fibers responsible for motor control, and pathways carrying proprioception in AIS [1, 4–7]. It has been suggested that visual-spatial perception disorders, body-spatial orientation changes and sensory integration disorders seen in individuals with AIS are related to CNS dysfunction [8]. Some studies have even reported that the main cause of spinal deformity is dysfunction of areas of the CNS responsible for postural mechanisms [9, 10]. It has been suggested that the loss of proprioception sensation and the asymmetry between the muscle forces around the spine detected in individuals with AIS may be the primary cause of spinal deformity [1, 11]. Proprioception, simply defined, is the ability to be consciously and/or unconsciously aware of the position of body parts in space [12].

While some studies suggest these CNS-related problems in individuals with AIS as a possible cause of AIS [13–16], some studies argue that CNS anomalies develop secondary to spinal deformity [1, 8, 9, 13]. Because spinal curvature in AIS causes some changes in the body. These changes activate the neuroplasticity feature in the CNS, leading to some regulations in neurons and synapses between neurons and structural changes in the brain [17, 18].

Twelve pairs of cranial nerves originating from the brain and brainstem innervate structures in the head and neck region in general after passing through foramen in the neurocranium [19]. The nuclei of the fifth cranial nerve, the nervus trigeminus, which contains both sensory and motor fibers, are distributed throughout the brainstem. The sensory root of the trigeminal nerve receives sensations of pressure, contact, pain, heat, and proprioceptive sensation from mimic and masticatory muscles. The motor root innervates the unilateral masticatory muscles [20, 21]. Diffusion tensor imaging (DTI) technique, which was developed from the traditional magnetic resonance imaging (MRI) method, provides information about the microarchitecture of the brain white matter [22].

In order to reveal the relationship between motor control and proprioceptive sensory abnormalities and spinal deformity in individuals with AIS, the nervus trigeminus cranial

nerve, which is the least affected by spinal deformity and contains motor control and proprioceptive sensory fibers, was examined. The microarchitectural structure of the nervus trigeminus was analyzed by tarctography, and the musculus pterygoideus lateralis and musculus pterygoideus medialis were analyzed by volume to reveal possible differences compared to the control group.

Methods

The presented study was conducted in a single center and as a cross-sectional cohort. Ethics committee approval for the study was received from the Local Ethics Committee with decision number 2023/03. Participants were informed about the study and their written consent was obtained. The Declaration of Helsinki was complied with at every stage of the stud.

Participants and study groups

In a pilot study with 7 individuals for each of the two groups, the sample size was determined to be at least 30 participants for each group, with an effect size of 0.7 using a power of 0.80 and $\alpha=0.05$.

This study was designed on 40 (27 female, 13 male) Lenke Type 3 AIS patients and 40 (25 female, 15 male) healthy individuals from the same age population. The AIS group included individuals diagnosed with AIS with a major curve in the right thoracic spine with a major curve angle between 20 and 40 degrees (Cobb angle 20–40°). The inclusion criteria for the control group were as follows: no postural deformity according to postural analysis, clinical scoliometric and radiologic evaluation. In both groups, participants had to be between the ages of 10–18 years and have a cranial MRI taken within the last six months.

Exclusion criteria in both groups were individuals with a history of head trauma, headache, back injury or cranial surgery for any reason. To avoid differences in gender, age, race and sociocultural aspects in the study groups, participants were selected by block randomization among those who applied to the outpatient clinic between June 2023 and January 2024.

Data acquisition

MRI procedures of the participants were performed on the Netherlands-based Siemens Magnetom Skyra MRI device with 3T (Tesla) feature. In the study, the MRI acquisition protocol was performed in the following sequences.

- T1 weighted MPRAGE sequence: Sagittal, Echo Time (TE)=3.4ms, FOV=250 mm, Matrix:256×256, Repetition time (TR)=2300ms, Slice Thickness=1 mm.
- DTI: Axial, TR=4900ms, TE=95ms, Number-of-Slice=36, FOV=230 mm, Matrix: 128×128, Slice Thickness=3.5 mm, Averages=3, b=0.1000 s/mm², 20 diffusion directions. The data obtained from the MRI devices were saved in DICOM format and the planned measurements were made.

Data processing

Tractography of the nerve trigeminus was performed using the “DSI Studio” program. The tractography process of each participant was started by making “Fiber tracking” settings. Here; “Threshold” was set to 0.20, “Angular Threshold” was set to 70 degrees, “Smoothing” was set to 0.50, the shortest tract was 10 mm, the longest tract was 1000 mm, and “terminateif” was set to 100,000 lifts. “Tractography Atlas” was used during tractography of the nervus trigeminus in the DSI Studio program. As a result of the analysis, fractional anisotropy (FA), axial diffusivity (AD), mean diffusivity (MD), radial diffusivity (RD), total number of

fibers, fiber ratio (ratio to the number of fibers in the whole brain) and mean fiber length (in millimeters) values of the right and left trigeminus nerves were obtained (Fig. 1).

Musculus pterygoideus medius and lateralis volume calculation process

In this study, the volume calculation of the targeted muscles was done using the Insight Segmentation and Registration Tool Kit (ITK -SNAP) program. Muscle volumes of the participants were measured manually in the ITK SNAP program using MRI data in DICOM format. Using the TK SNAP program, pixels corresponding to the anatomical structure of the muscle whose volume was to be calculated in the coronal plane were determined and muscle volumes in mm³ were obtained (Fig. 2).

Statistical analysis

Study data were collected using the Statistical Package for the Social Sciences 22.0 program, which is compatible with Windows. The variables were investigated using visual (probability plots, histograms) and analytical (Kolmogorov-Smirnov/Shapiro-Wilk’s test) methods to check

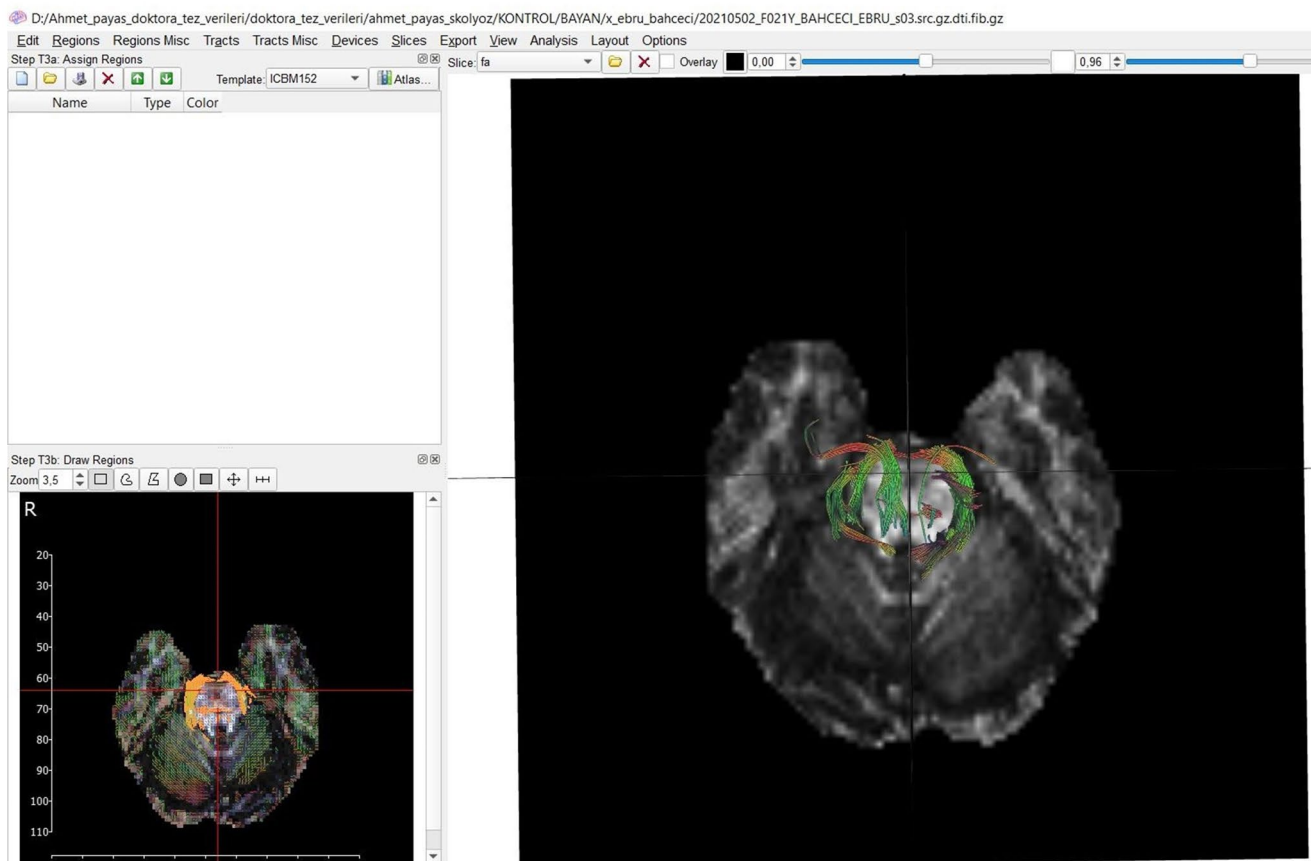


Fig. 1 Tractography process of nervus trigeminus in the DSI Studio program

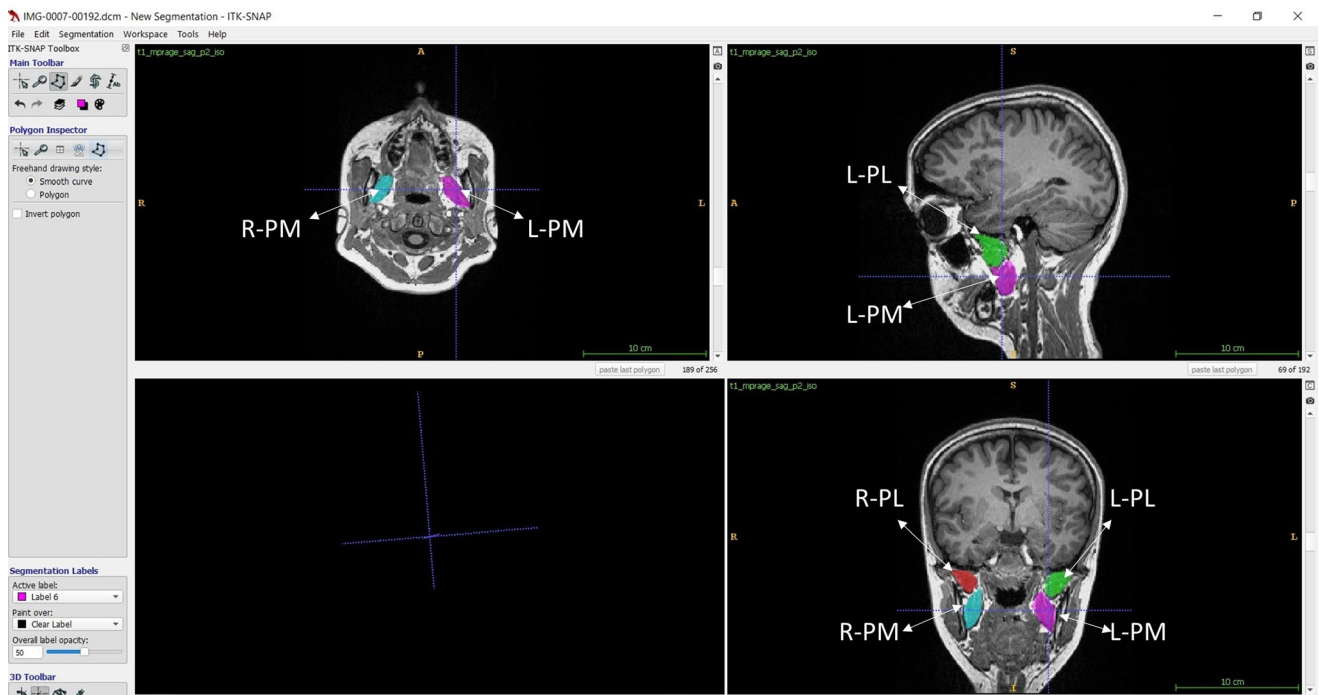


Fig. 2 Musculus pterygoideus medialis and lateralis volume calculation with the help of ITK-SNAP program. *R-PL: Right musculus pterygoideus lateralis, *L-PL: Left musculus pterygoideus lateralis,

*R-PM: Right musculus pterygoideus medialis, *L-PM: Left musculus pterygoideus medialis

Table 1 Demographic and clinical characteristics of groups

Variable	AIS group (n=32)	Control group (n=32)	p
Age (years)	17.11 ± 2.95	17.52 ± 2.93	0.74
Body mass index (kg/m ²)	22.13 ± 5.21	21.59 ± 4.44	0.65
Female (%)	27 (84.37%)	25 (78.12%)	0.52
Cobb angle for thoracic	32.12 ± 7.84	-	-
Cobb angle for lumbar	15.54 ± 4.81	-	-
Risser sign	2.21 ± 2.54	2.35 ± 2.49	0.82
Lenke curve type 3	32 (100%)	-	-
Dominant side upper (R)	28 (87.50%)	24 (75.00%)	0.20
Dominant side lower (R)	28 (87.50%)	24 (75.00%)	0.20

Independent samples t test or χ^2 test; R: Right; AIS: Adolescent idiopathic scoliosis

normality. Counts and rates were reported using descriptive statistics for categorical data, and distribution measures for continuous data. Baseline characteristics were compared using independent t test or χ^2 test. To evaluate the side-related differences in the outcomes, a 2*2 [group (control and AIS) * side (left or right)] repeated measures ANCOVA was performed with group as a between-groups factor and side as a within-subjects factor, and with demographic measures set as the covariates. When the F ratio was significant, mean differences were determined using Bonferroni’s post hoc test. Effect sizes were determined as partial eta squared (η^2_p) and the significance level was $p < 0.05$.

Results

There were a total of 80 participants in the study, 40 with AIS with Lenke type 3 curvature and 40 healthy. There was no significant difference between the groups in terms of basic characteristics ($p > 0.05$), (Table 1). When the tractography data of the nervus trigeminus were compared between the scoliosis and control groups, it was observed that the number of fibres and fibre ratio of the left nervus trigeminus were significantly greater in the control group than in the individuals with scoliosis $p < 0.05$. ANCOVA did not reveal any significant group*side interaction effect in terms of trigeminal nerve measurements (fiber count, fiber length, fractional anisotropy, mean diffusivity, axial diffusivity, radial diffusivity, and fiber percentage) performed on both sides (right and left) for the two groups ($p > 0.05$, Table 2). However, there were statistically significant differences in terms of lateral pterygoid muscle volume ($p = 0.003$, $\eta^2 = 0.13$) and lateral pterygoid muscle volume percentage ($p = 0.008$, $\eta^2 = 0.10$). Right and left lateral pterygoid muscle showed lower volume and volume percentage in the scoliosis group compared to the control group ($p < 0.05$, Table 2).

Table 2 Comparison of the outcome measurements between the groups

Outcome Measures	Right		p^1	Left		p^1	Side p^2 (η^2p)	Group*Side p^2 (η^2p)
	AIS group	Control Group		AIS group	Control Group			
Trigeminal nerve fiber count	2105.06 ± 862.4	2137.12 ± 724.9	0.87	1672.34 ± 771.2	2043.96 ± 965.6	0.09	0.03 (0.06)	0.17 (0.03)
Trigeminal nerve fiber length	42.67 ± 7.91	41.90 ± 7.78	0.69	38.86 ± 9.39	40.35 ± 8.55	0.51	0.02 (0.08)	0.31 (0.01)
Trigeminal nerve fractional anisotropy	0.38 ± 0.02	0.38 ± 0.03	0.35	0.36 ± 0.04	0.37 ± 0.04	0.62	0.002 (0.14)	0.23 (0.02)
Trigeminal nerve mean diffusivity	1.20 ± 0.11	1.18 ± 0.10	0.49	1.18 ± 0.17	1.22 ± 0.13	0.12	0.09 (0.04)	0.13 (0.03)
Trigeminal nerve axial diffusivity	1.66 ± 0.11	1.63 ± 0.11	0.35	1.71 ± 0.19	1.67 ± 0.13	0.33	0.02 (0.07)	0.70 (0.002)
Trigeminal nerve radial diffusivity	0.97 ± 0.10	0.95 ± 0.10	0.61	1.03 ± 0.18	1.00 ± 0.14	0.38	0.003 (0.13)	0.52 (0.006)
Trigeminal nerve fiber percentage	2.69 ± 1.11	2.73 ± 0.92	0.87	2.14 ± 1.00	2.61 ± 1.22	0.09	0.03 (0.06)	0.17 (0.02)
Lateral pterygoid muscle volume (mm ³)	8392.0 ± 1460.8	8692.81 ± 1888.9	0.47	8486.46 ± 1724.1	8669.2 ± 1705.5	0.67	0.65 (0.003)	0.003 (0.13)*
Lateral pterygoid muscle volume percentage	49.26 ± 1.39	50.57 ± 2.29	0.008	49.42 ± 2.29	50.73 ± 1.39	0.008	0.74 (0.002)	0.008 (0.10)*
Medial pterygoid muscle volume (mm ³)	9257.1 ± 2044.3	9307.1 ± 2135.5	0.92	8855.06 ± 2301.6	8846.0 ± 1857.3	0.98	0.001 (0.25)	0.75 (0.002)
Medial pterygoid muscle volume percentage	51.29 ± 2.54	51.16 ± 1.59	0.80	48.70 ± 2.54	48.83 ± 1.59	0.80	0.001 (0.25)	0.80 (0.001)

p^1 : independent samples t-test for between-group comparisons; p^2 : two-way repeated measures analysis of covariance with a mixed model. Values are expressed as mean ± standard deviation. Effect sizes were determined as partial eta squared (η^2p) for p^2 . AIS: Adolescent idiopathic scoliosis

Discussion

Whether the cause of motor control and proprioception sensory dysfunction detected in individuals with AIS is a CNS anomaly or spinal deformity is still hotly debated [1, 4–7]. This was the question we sought to answer in this study. For this purpose, we analyzed the trigeminal cranial nerve, which contains fibers responsible for both motor control and proprioceptive sensation that would be minimally affected by spinal deformity. As a result of the analysis, it was determined that there was a difference in the fiber number, ratio and left pterygoideus lateralis muscle volume data of the left nervus trigeminus in individuals with AIS compared to healthy individuals. While the cause of AIS remains a mystery, one of the various theories attempting to explain its pathogenesis is CNS abnormality [3]. In AIS, abnormalities have been found in some CNS regions such as the cerebrum, brainstem, corpus callosum, fibers responsible for motor control and pathways carrying proprioception [1, 4–7]. The anomalies detected in the CNS were somehow related to the anatomical structures around the columna vertebralis and postural balance. Therefore, it was not clear whether the CNS abnormality was a cause or a consequence in individuals with AIS.

Some studies in the literature have reported that CNS abnormalities seen in AIS are a triggering cause of spinal

deformity [8, 9, 14]. On the other hand, some studies have claimed that different stimuli caused by spinal deformity and altered body posture in AIS cause structural changes in neurons, synapses and brain, and therefore CNS abnormalities develop [6, 8, 9, 17, 18].

The nervus trigeminus, which is minimally affected by spinal deformity, is known to contain various sensory and motor fibers, the majority of which are proprioceptive [20, 21]. Diffusion tensor imaging (DTI) is the most suitable method to examine the neuroarchitecture of anatomical structures composed of axons such as the nervus trigeminus [23–25]. In tractography using DTI, some values such as the course of pathways in the brain, fiber number, fiber volume, fiber area, mean fiber length, fractional anisotropy (FA), mean diffusion (MD), axial diffusion (AD) and radial diffusion (RD) are calculated [27]. FA is an indicator of direction-dependent (anisotropic) diffusion fraction. Low FA values are a reflection of myelin sheath damage. MD is the mean overall directional diffusion. Increased MD gives information about decreased white matter due to axon and myelin damage. AD data is indicative of the magnitude of diffusion parallel to the fiber tract. A low AD value provides information about axon damage, decreased axon diameter. RD data provides information about the magnitude of diffusion perpendicular to the fiber tract. An increase in the RD value is an indicator of myelin loss or axon loss [28, 29]. In

tractography analysis, fiber number and fiber ratio values are as important as the data providing information about the tendency and axon structure. Because it has been reported that data such as fiber number and fiber ratio in a nerve or tract are directly related to the functionality of the related nerve or tract [1, 30, 31].

In the present study, the neuromimetic structure of the nervus trigeminus, which will be minimally affected by spinal deformity, was analyzed by DTI. The fiber number and fiber ratio of the left nervus trigeminus were found to be smaller in individuals with AIS compared to healthy individuals. As it is known, the nervus trigeminus contains fibers responsible for motor control, mostly proprioception. We needed to distinguish whether the source of the low fiber number and fiber ratio detected in the left nervus trigeminus of individuals with AIS was proprioception or fibers responsible for motor control. A review of the literature showed that there is a direct correlation between muscle volume and the fibers responsible for motor control that innervate the muscle [1, 11]. Therefore, the volumes of the musculus pterygoideus lateralis and musculus pterygoideus medialis innervated by the nervus trigeminus were also calculated.

In the present study, the left nervus trigeminus, fiber number and fiber ratio as well as the left musculus pterygoideus lateralis volume data of the left nervus trigeminus of individuals with AIS were smaller than healthy individuals. This may indicate that both motor and proprioception sensory fibers of the nervus trigeminus are affected in individuals with AIS. The low fiber number and ratio of the nervus trigeminus, which would be minimally affected by spinal deformity, may be evidence that the loss of motor control and proprioception sensory loss detected in individuals with AIS may have developed independently of spinal deformity.

In our previous study, it was observed that the fiber and fiber ratios of the lemniscus medialis, which carries proprioception sensation, and tractus corticospinalis, which provides motor control of the muscles, were lower in individuals with AIS compared to healthy individuals [1]. In studies conducted in individuals with AIS, it was reported that asymmetry was observed in the tractus corticospinalis ventral to the pons [5], the tractus corticospinalis was more lateralized in individuals with AIS compared to healthy individuals [32], and the capsula interna of the brain white matter was weaker in individuals with AIS [4].

In this study, the fact that only the left nervus trigeminus data were different in individuals with AIS compared to healthy individuals suggests that there is asymmetry between the nervus trigeminus of individuals with AIS. The findings of the study are also supported by the literature.

It has been reported that proprioceptive sensation cannot be transmitted to the cerebral cortex in a functional manner in individuals with AIS and therefore balance disorder

is observed in individuals with AIS [1,33]. In the present study, the fact that the nervus trigeminus data, which contains a high proportion of proprioception sensory fibers, were lower in individuals with AIS may be related to inadequate functioning of the proprioceptive system in individuals with AIS. Because the functionality of the nerve and tractar is directly related to fiber number and fiber ratio.

The present study had some limitations. Firstly, it was conducted on a relatively small group of patients and secondly, it was cross-sectional. Therefore, more cases and longer studies are needed.

Conclusion

In the study, it was observed that the nervus trigeminus, which contains fibers responsible for motor control and proprioception sensation, which can be affected the least by spinal deformity, was affected in individuals with AIS. Considering that this nerve contains intensive proprioception sensory and motor fibers, it suggests that the loss of proprioception sensation and motor control in individuals with AIS may have occurred independently of spinal deformity. Our study is the first to demonstrate this relationship and large-scale studies are needed to obtain clear results and to elucidate the pathophysiology.

Funding The authors declared that this study hasn't received no financial support.

Declarations

Ethical approval Ethical approval of the study was received by Hitit University Local Ethics Committee with decision number 2023/03.

Conflict of interest The authors declare that they have no competing interest.

References

1. Payas A, Batin S, Kurtoğlu E, Arik M, Seber T, Uçar İ, Unur E (2023) Is the Integration Problem in the Sensorio-motor System the cause of adolescent idiopathic scoliosis? *J Pediatr Orthop* 43(2):e111–e119. <https://doi.org/10.1097/BPO.0000000000002300>
2. Peng Y, Wang SR, Qiu GX, Zhang JG, Zhuang QY (2020) Research progress on the etiology and pathogenesis of adolescent idiopathic scoliosis. *Chin Med J* 133(4):483–493. <https://doi.org/10.1097/CM9.0000000000000652>
3. Le Berre M, Pradeau C, Brouillard A, Coget M, Massot C, Catanzariti JF (2019) Do adolescents with idiopathic scoliosis have an erroneous perception of the Gravitational Vertical? *Spine Deformity* 7(1):71–79. <https://doi.org/10.1016/j.jspd.2018.05.004>
4. Shi L, Wang D, Chu WC, Burwell RG, Freeman BJ, Heng PA, Cheng JC (2009) Volume-based morphometry of brain MR images in adolescent idiopathic scoliosis and healthy control

- subjects. *AJNR Am J Neuroradiol* 30(7):1302–1307. <https://doi.org/10.3174/ajnr.A1577>
5. Geissele AE, Kransdorf MJ, Geyer CA, Jelinek JS, Van Dam BE (1991) Magnetic resonance imaging of the brain stem in adolescent idiopathic scoliosis. *Spine* 16(7):761–763. <https://doi.org/10.1097/00007632-199107000-00013>
 6. Wang D, Shi L, Chu WC, Burwell RG, Cheng JC, Ahuja AT (2012) Abnormal cerebral cortical thinning pattern in adolescent girls with idiopathic scoliosis. *NeuroImage* 59(2):935–942. <https://doi.org/10.1016/j.neuroimage.2011.07.097>
 7. Batin S, Payas A, Bal E, Ekinci Y, Kurtoglu E, Ucar I, Arik M, Seber T, Varol BK, Ulusoy EK, Bayram AK, Ekinci D, Unur E (2023) Evaluation of cerebellum volume and trunk oscillation velocity in cases with adolescent idiopathic scoliosis: a preliminary report. *European spine journal: official publication of the European Spine Society, the European Spinal Deformity Society, and the European section of. Cerv Spine Res Soc* 32(11):4012–4019. <https://doi.org/10.1007/s00586-023-07948-2>
 8. Burwell RG, Freeman BJ, Dangerfield PH, Aujla RK, Cole AA, Kirby AS, Polak F, Pratt RK, Webb JK, Moulton A (2006) Etiologic theories of idiopathic scoliosis: neurodevelopmental concept of maturational delay of the CNS body schema (body-in-the-brain). *Stud Health Technol Inform* 123:72–79
 9. Burwell RG, Aujla RK, Grevitt MP, Dangerfield PH, Moulton A, Randell TL, Anderson SI (2009) Pathogenesis of adolescent idiopathic scoliosis in girls - a double neuro-osseous theory involving disharmony between two nervous systems, somatic and autonomic expressed in the spine and trunk: possible dependency on sympathetic nervous system and hormones with implications for medical therapy. *Scoliosis* 4:24. <https://doi.org/10.1186/1748-7161-4-24>
 10. Picelli A, Negrini S, Zenorini A, Iosa M, Paolucci S, Smiana N (2016) Do adolescents with idiopathic scoliosis have body schema disorders? A cross-sectional study. *J Back Musculoskelet Rehabil* 29(1):89–96. <https://doi.org/10.3233/BMR-150602>
 11. Kocaman H, Bek N, Kaya MH, Büyükturan B, Yetiş M, Büyükturan Ö (2021) The effectiveness of two different exercise approaches in adolescent idiopathic scoliosis: a single-blind, randomized-controlled trial. *PLoS ONE* 16(4):e0249492. <https://doi.org/10.1371/journal.pone.0249492>
 12. Kargin D, Emre Aycan O, Gönen Aydin C, Albayrak A, Atici Y, Balioğlu MB (2018) The proprioception of the knee joint following tibia plateau fractures. *Acta Orthop Belg* 84(2):213–222
 13. Formaggio E, Bertuccelli M, Rubega M, Di Marco R, Cantele F, Gottardello F, De Giuseppe M, Masiero S (2022) Brain oscillatory activity in adolescent idiopathic scoliosis. *Sci Rep* 12(1):17266. <https://doi.org/10.1038/s41598-022-19449-1>
 14. Chaloupka R, Mikl M, Nováková M, Repko M, and Ivan Rektor (2022). Modification of Brain Functional Connectivity in Adolescent Thoracic Idiopathic Scoliosis by Lower Extremities Position Symmetry 14, no. 10: 2068. <https://doi.org/10.3390/sym14102068>
 15. Lanthier J, Simoneau M, Knoth IS, Lippé S, Bluteau C, Fortin C (2020) Increased EEG alpha peak frequency in adolescents with idiopathic scoliosis during balance control in normal upright standing. *Neurosci Lett* 722:134836. <https://doi.org/10.1016/j.neulet.2020.134836>
 16. Fortin C, Pialasse JP, Knoth IS, Lippé S, Duclos C, Simoneau M (2019) Cortical dynamics of sensorimotor information processing associated with balance control in adolescents with and without idiopathic scoliosis. *Clin Neurophysiology: Official J Int Federation Clin Neurophysiol* 130(10):1752–1761. <https://doi.org/10.1016/j.clinph.2019.07.005>
 17. Li P, Legault J, Litcofsky KA (2014) Neuroplasticity as a function of second language learning: anatomical changes in the human brain. *Cortex* 58:301–324. <https://doi.org/10.1016/j.cortex.2014.05.001>
 18. Sagi Y, Tavor I, Hofstetter S, Tzur-Moryosef S, Blumenfeld-Katzir T, Assaf Y (2012) Learning in the fast lane: new insights into neuroplasticity. *Neuron* 73(6):1195–1203. <https://doi.org/10.1016/j.neuron.2012.01.025>
 19. Trejo JL (2019) Cranial nerves: mind your head. *Anat Record (Hoboken N J : 2007)* 302(3):374–377. <https://doi.org/10.1002/ar.24071>
 20. Harsha KJ, Kesavadas C, Chinchure S, Thomas B, Jagtap S (2012) Imaging of vascular causes of trigeminal neuralgia. *J Neuroradiol = J de Neuroradiologie* 39(5):281–289. <https://doi.org/10.1016/j.neurad.2012.08.006>
 21. Becker M, Kohler R, Vargas MI, Viallon M, Delavelle J (2008) Pathology of the trigeminal nerve. *Neuroimaging Clin N Am* 18(2):283–x. <https://doi.org/10.1016/j.nic.2007.11.002>
 22. Cheng H, Wang Y, Sheng J, Kronenberger WG, Mathews VP, Hummer TA, Saykin AJ (2012) Characteristics and variability of structural networks derived from diffusion tensor imaging. *NeuroImage* 61(4):1153–1164. <https://doi.org/10.1016/j.neuroimage.2012.03.036>
 23. Lee SK, Kim DI, Kim J, Kim DJ, Kim HD, Kim DS, Mori S (2005) Diffusion-tensor MR imaging and fiber tractography: a new method of describing aberrant fiber connections in developmental CNS anomalies. *Radiographics: Rev Publication Radiological Soc North Am Inc* 25(1):53–68. <https://doi.org/10.1148/rg.251045085>
 24. Rollins NK (2007) Clinical applications of diffusion tensor imaging and tractography in children. *Pediatr Radiol* 37(8):769–780. <https://doi.org/10.1007/s00247-007-0524-z>
 25. Chokshi FH, Poretti A, Meoded A, Huisman TA (2011) Normal and abnormal development of the cerebellum and brainstem as depicted by diffusion tensor imaging. *Seminars in ultrasound, CT, and MR*, 32(6), 539–554. <https://doi.org/10.1053/j.sult.2011.06.005>
 26. Mori S, Zhang J (2006) Principles of diffusion tensor imaging and its applications to basic neuroscience research. *Neuron* 51(5):527–539. <https://doi.org/10.1016/j.neuron.2006.08.012>
 27. Wahl M, Barkovich AJ, Mukherjee P (2010) Diffusion imaging and tractography of congenital brain malformations. *Pediatr Radiol* 40(1):59–67. <https://doi.org/10.1007/s00247-009-1448-6>
 28. Pietrasik W, Cribben I, Olsen F, Huang Y, Malykhin NV (2020) Diffusion tensor imaging of the corpus callosum in healthy aging: investigating higher order polynomial regression modelling. *NeuroImage* 213:116675. <https://doi.org/10.1016/j.neuroimage.2020.116675>
 29. Gao J, Cheung RT, Lee TM, Chu LW, Chan YS, Mak HK, Zhang JX, Qiu D, Fung G, Cheung C (2011) Possible retrogenesis observed with fiber tracking: an anteroposterior pattern of white matter disintegrity in normal aging and Alzheimer's disease. *J Alzheimer's Disease: JAD* 26(1):47–58. <https://doi.org/10.3233/JAD-2011-101788>
 30. Higgen FL, Braaß H, Backhaus W, Schulz R, Xue G, Gerloff C (2021) Reduced frontal white matter microstructure in healthy older adults with low tactile recognition performance. *Sci Rep* 11(1):11689. <https://doi.org/10.1038/s41598-021-90995-w>
 31. Goldberg CJ, Dowling FE, Fogarty EE, Moore DP (1995) Adolescent idiopathic scoliosis and cerebral asymmetry. An examination of a nonspinal perceptual system. *Spine* 20(15):1685–1691. <https://doi.org/10.1097/00007632-199508000-00007>
 32. Dąbrowska, A., Olszewska-Karaban, M. A., Permoda-Białozorzyczyk, A. K., & Szalewska, D. A. (2020). The Postural Control Indexes during Unipodal Support in Patients with Idiopathic Scoliosis. *BioMed research international*, 2020, 7,936,095. <https://doi.org/10.1155/2020/7936095>

Publisher's note Springer Nature remains neutral with regard to jurisdictional claims in published maps and institutional affiliations.

Springer Nature or its licensor (e.g. a society or other partner) holds exclusive rights to this article under a publishing agreement with the author(s) or other rightsholder(s); author self-archiving of the accepted manuscript version of this article is solely governed by the terms of such publishing agreement and applicable law.