

See discussions, stats, and author profiles for this publication at: <https://www.researchgate.net/publication/368907359>

Effects of COVID-19 on brain and cerebellum: a voxel based morphometrical analysis

Article in Bratislavske Lekarske Listy · June 2023

DOI: 10.4149/BLL_2023_068

CITATIONS

11

READS

480

10 authors, including:



Burcu Kamaşak Arpaçay

Ahi Evran University

32 PUBLICATIONS 91 CITATIONS

SEE PROFILE



Tufan Ulcay

Ahi Evran University

37 PUBLICATIONS 86 CITATIONS

SEE PROFILE



Mehtap Nisari

Erciyes University

71 PUBLICATIONS 383 CITATIONS

SEE PROFILE



Özkan Görgülü

Ahi Evran Üniversitesi Faculty of Medicine

86 PUBLICATIONS 609 CITATIONS

SEE PROFILE

CLINICAL STUDY

Effects of COVID-19 on brain and cerebellum: a voxel based morphometrical analysis

Burcu KAMASAK¹, Tufan ULCAI¹, Mehtap NISARI², Ozkan GORGULU³, Veysel AKCA⁴, Muhammet ALPASLAN⁵, Aysu YETIS⁶, Lokman HIZMALI⁴, Mustafa Kasim KARAHOCAGIL⁴, Kenan AYCAN¹

Department of Anatomy, Faculty of Medicine, Kirsehir Ahi Evran University, Kirsehir, Turkey.
brc1608@hotmail.com

ABSTRACT

OBJECTIVE: COVID-19 is caused by SARS-CoV-2 virus and turned into a pandemic in a short time, affects many organs and systems, especially the nervous system. In the present study, it was aimed to determine the morphological and volumetric changes in cortical and subcortical structures in recovered COVID-19 patients.

BACKGROUND: We think that COVID-19 has a long-term effect on cortical and subcortical structures.

METHODS: In our study, 50 post-COVID-19 patients and 50 healthy volunteers participated. In both groups, brain parcellations were made with Voxel-Based Morphometry (VBM) and regions showing density changes in the brain and cerebellum were determined. Gray matter (GM), white matter, cerebrospinal fluid and total intracranial volume were calculated.

RESULTS: Neurological symptoms developed in 80% of COVID-19 patients. In post-COVID-19 patients, a decrease in GM density was detected in pons, gyrus frontalis inferior, gyri orbitales, gyrus rectus, gyrus cinguli, lobus parietalis, gyrus supramarginalis, gyrus angularis, hippocampus, lobulus semilunaris superior of cerebellum, declive, and Brodmann area 7-11-39-40. There was a significant decrease in GM density in these regions and an increase in GM density in amygdala ($p < 0.001$). The GM volume of post-COVID-19 group was found to be less than in the healthy group.

CONCLUSIONS: As a result, it was seen that COVID-19 negatively affected many structures related to the nervous system. This study is a pioneering study to determine the consequences of COVID-19, especially in the nervous system, and to determine the etiology of these possible problems (Tab. 4, Fig. 5, Ref. 25). Text in PDF www.elis.sk

KEY WORDS: COVID-19, pandemic, Voxel-based morphometry (VBM), brain, magnetic resonance imaging (MRI).

Introduction

COVID-19 turned into a pandemic in a short time and has been spreading worldwide since December 2019. As the number of cases increases, it has been revealed that COVID-19 affects the respiratory system and many organs and systems, including the central and peripheral nervous system (1,2). It has been known that some respiratory viruses cause neurological involvement for a long time. These neurological symptoms, especially emerging

in the acute phase, can occur even after mild forms of respiratory disease (3,4). The first report was declared by Mao et al (1) on neurologic results during the COVID-19 pandemic. In many studies (1,2,5–7), neurological symptoms such as headaches, dizziness, unconsciousness, neuropathic pain, seizures, ataxia, speech disorders, loss of taste and smell, memory problems, and brainstem and cerebellar disorders were observed. While patients with severe SARS-CoV-2 infection had various neurological symptoms, new brain changes were seen in those with mild to moderate disease (8). Except for the olfactory and gustatory dysfunctions in mild-to-moderate COVID-19 patients recorded by 12 European hospitals, various neurological diseases including stroke, encephalitis, encephalopathy, micro-hemorrhage, and cerebral venous embolism were also reported in hospitalized patients (9,10).

The long-term effect of the disease on the cortical and subcortical structures of participants should be further investigated, as potential damage to the central nervous system (CNS) is unknown in the post-COVID-19 period. In order to determine whether SARS-CoV-2 could cause long-term changes in the cortical and cerebellar regions, we examined the morphological and volumetric changes in neurological system of individuals with COVID-19.

¹Department of Anatomy, Faculty of Medicine, Kirsehir Ahi Evran University, Kirsehir, Turkey, ²Department of Anatomy, Faculty of Medicine, Erciyes University, Kayseri, Turkey, ³Department of Biostatistics, Faculty of Medicine, Kirsehir Ahi Evran University, Kirsehir, Turkey, ⁴Department of Infectious Diseases and Clinical Microbiology, Faculty of Medicine, Kirsehir Ahi Evran University, Kirsehir, Turkey, ⁵Darica Farabi Teaching and Research Hospital, Department of Radiology, Kocaeli, and ⁶Department of Neurology, Faculty of Medicine, Kirsehir Ahi Evran University, Kirsehir, Turkey

Address for correspondence: Burcu KAMASAK, Kirsehir Ahi Evran University, Faculty of Medicine, Department of Anatomy, Kirsehir, Turkey. Phone: +90 545 282 89 02

Material and methods

Participants

This study was conducted between November 2020 and February 2021 in Kirsehir Ahi Evran University Training and Research Hospital, 50 participants (25 males and 25 females) between the ages of 30–60 were diagnosed and recovered with COVID-19, and 50 healthy volunteers (25 males and 25 females) were not diagnosed with COVID-19 and within the same age range were included in the study. Participants without any previous neurological or systemic disease were included in both groups. In addition, factors regarding cerebrovascular risk factors such as smoking, alcohol use, regular drug use, hypertension and diabetes were not present in the individuals included in the study. The group of COVID-19 was formed from participants with mild and moderate COVID-19 diagnoses according to SARS-CoV-2 diagnostic criteria and follow-up algorithm. Participants recovering from COVID-19 infection joined our study one week after completing a 10-day quarantine.

MRI protocol

MRI examinations were performed on a 1.5 Tesla GE SIGNA Explorer (United States) with a 32-channel sense head coil at a supine position lasting for each subject. T1-weighted 3D magnetization-prepared rapid gradient echo (MPRAGE) sequence images: sagittal, repetition time (TR)/echo time (TE)/flip angle=1900

ms/2.67 ms/20°, TI:1100, Field-of-view (FOV)=250 mm, 1 mm slice thickness, 196 slices, matrix=256×256, voxel size=1×1×1 mm³. No artefacts were observed in their MR images.

VBM analysis

This study used the Computational Anatomy Toolbox (CAT12), which utilizes and extends the new unified segmentation approach implemented in Statistical Parametric Mapping (SPM12), executed in Matlab 7.10.0 (R201a) for whole brain volumetric analysis. The sagittal T1 Digital Imaging and Communications in Medicine (DICOM) files were converted to the Neuroimaging Informatics Technology Initiative (NIFTI-1) format. The converted files were then segmented into grey and white matter and normalized using the unified model cited above. Gray matter (GM), white matter (WM) and cerebrospinal fluid (CSF) were obtained to calculate the overall tissue volume (GM, WM and CSF volume) and TIV. The Automated Anatomical Labeling (AAL) atlas is delivered as part of the SPM toolboxes used to calculate the lobar GM volumes. We performed brain and cerebellum VBM analyses using the CAT12 toolbox to identify the morphological changes in groups. Initially, a two-sample t-test was conducted to compare the volume of GM between the two groups. TIV, age, and gender were included as covariates in all analyses. These analyses utilized a less uncorrected thresholds of $p < 0.001$ and extent threshold (voxels) of 50.

Statistical analysis

In the study, the normality assumption of the data was tested with the Kolmogorov-Smirnov and Shapiro-Wilk tests. An independent t-test was used for group comparisons. Descriptive statistics of variables providing a normality assumption were given as mean ± standard deviation. The study’s statistics were analyzed using Statistical Package for Social Sciences for Windows version 25.0 (IBM SPSS Statistics for Windows, Version 25.0, Armonk, NY: IBM Corp., USA).

Results

The mean age was 38.10±5.85 in the post-COVID-19 group and 38.78±6.16 in the healthy group. During the SARS-CoV-2 infection, 40 (80%) patients had neurological symptoms. At the time of the MRI scan, 20 (40%) participants in the post-COVID-19 period had neurological symptoms. Some patients had more than one neurological symptom. These symptoms are shown in Table 1.

The GM volume of the whole brain was less in a post-COVID-19 group than in the healthy group and the difference was statistically significant ($p < 0.05$). Although the TIV, WM, and CSF volume were lower in the post-COVID-19 group than in the healthy group, it was found to be statistically non-significant (Tab. 2).

To identify the morphological changes in the brain and cerebellum in post-COVID-19 and healthy groups, we performed VBM analysis using the CAT12 toolbox. GM volume in the post-COVID-19 group showed a reduction in gyri orbitales, gyrus rectus and Brodmann area 11, forming the orbitofrontal cortex (Fig. 1), gyrus cinguli (Fig. 1B), pons (Figs 1B, 2A), gyrus frontalis inferior (Figs 1B, 2B), lobus parietalis-Brodmann area 7 (Fig. 3), gyrus

Tab. 1. COVID-19 symptoms belonging to the group with COVID-19.

Symptoms		Participants with COVID-19 n=50 (100 %)
Neurological Symptoms	Headache	20 (40%)
	Dizziness	10 (20%)
	Memory problems – inability to focus	5 (10%)
	Loss of smell (anosmia%)	25 (50%)
	Loss of taste (ageusia%)	20 (40%)
	Speech disorder	2 (4%)
	Defect of vision	2 (4%)
Other symptoms	Diarrhea	4 (8%)
	Fever	24 (48%)
	Cough	11 (22%)
	Dyspnea	8 (16%)
	Muscle-joint pain	31 (62%)
	Muscle weakness-fatigue	14 (28%)
	Nausea	8 (16%)
	Throat ache	10 (20%)
	Chest pain	4 (8%)
	Rash and itching on the skin	1 (2%)
	Chill	2 (4%)
	Lung parenchyma involved	6 (12%)

Tab. 2. Mean GM, WM, TIV and CSF volumes of all groups (mm³).

	Participants with COVID-19	Healthy Group	p
GM	624.38±46.11	663.04±57.79	0.042
WM	527.30±45.85	534.66±62.86	0.505
TIV	1479.90±135.68	1539.34±157.06	0.182
CSF	328.22±58.07	341.64±64.98	0.279

GM: Gray matter, WM: White matter, TIV: Total intracranial volume, CSF: Cerebrospinal fluid

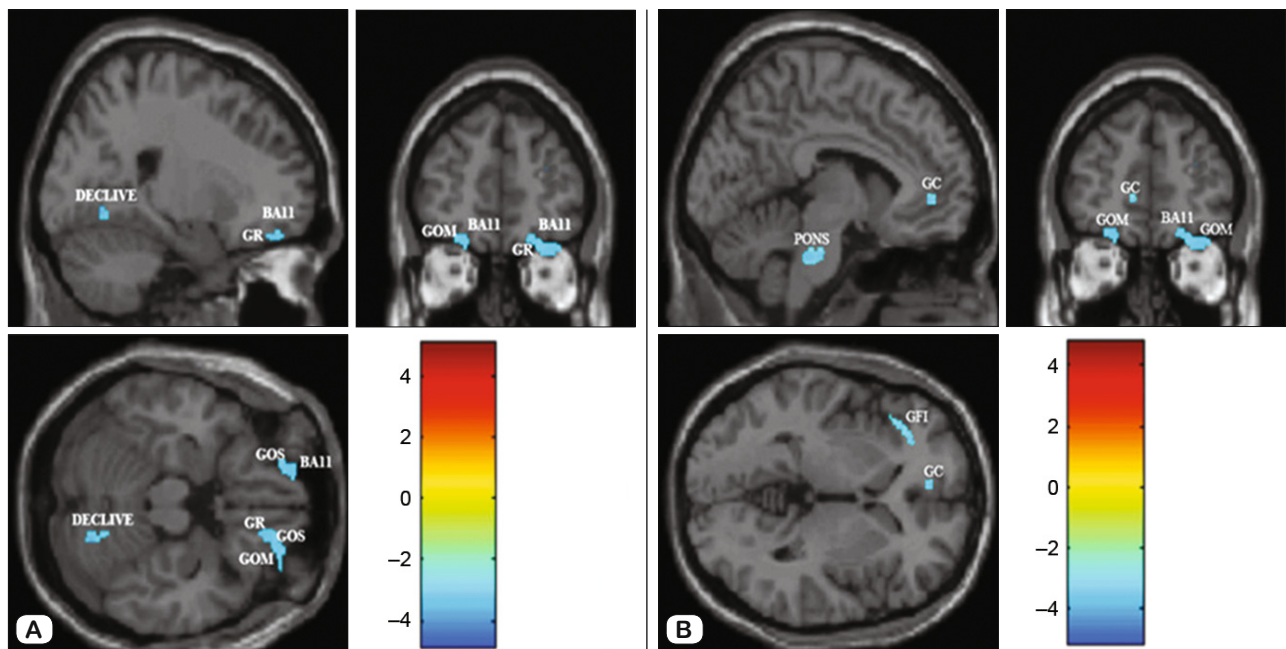


Fig 1. Altered gray matter volume of post-COVID-19 group and healthy group in single T1 images ($p < 0.001$). Blue area shows the decrease in GM volume of COVID-19 patients. A: BA11: Brodmann area 11, GR: Gyrus rectus, GOM: Gyrus orbitalis medialis, GOS: Gyrus orbitalis superior, B: GC: Gyrus cinguli, GFI: Gyrus frontalis inferior.

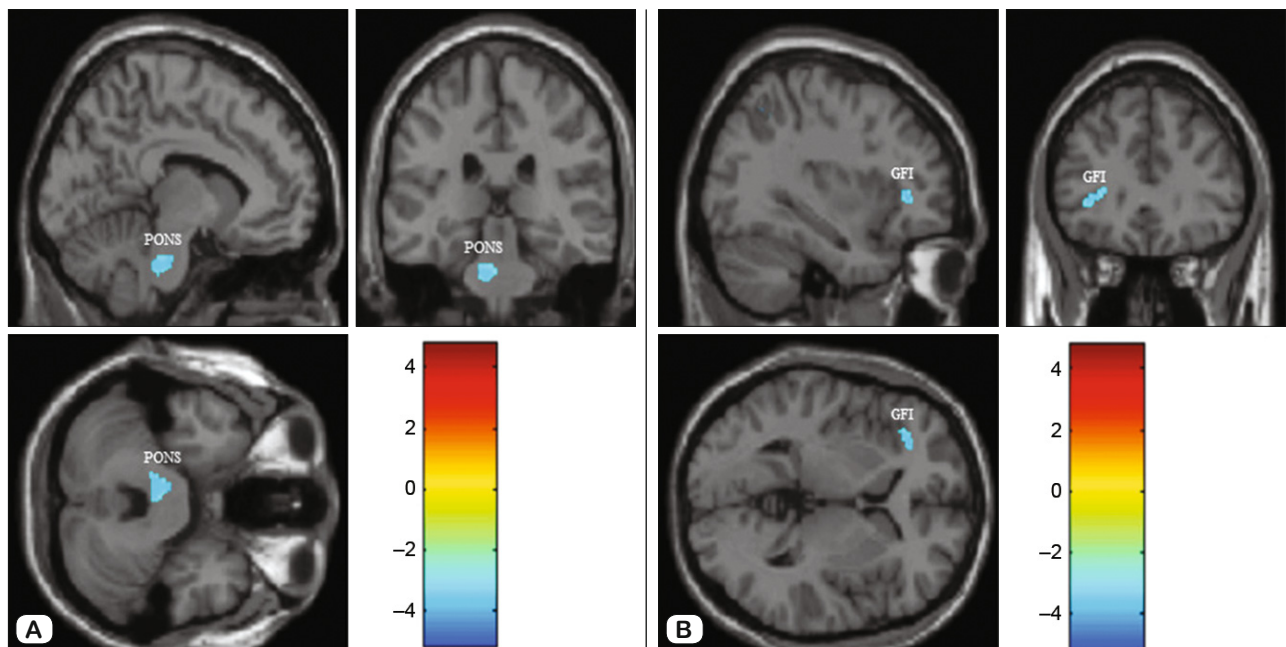


Fig 2. Altered gray matter volume of post-COVID-19 group and healthy group in single T1 images ($p < 0.001$). Blue area shows the decrease in GM volume of COVID-19 patients. A: Pons. B: GFI: Gyrus frontalis inferior.

supramarginalis-Brodmann area 40 (Figs 3A, 5A), gyrus angularis-Brodmann area 39 (Fig. 3B), lobulus semilunaris superior-crus 1 (Figs 3, 4A), hippocampus (Fig. 4B), declive (Figs 1A, 5B, Tab. 3) when compared to that in the healthy group. The GM volume of the amygdala and WM volume of the lobus parietalis increased compared to the healthy group (Fig. 5, Tab. 4).

Discussion

Coronaviruses are not always limited to the respiratory tract and can invade the CNS and trigger neurological diseases (4,7). SARS-CoV-2, a neurotropic virus, manifests itself with neurological symptoms in the majority of diseased individuals. Dur-

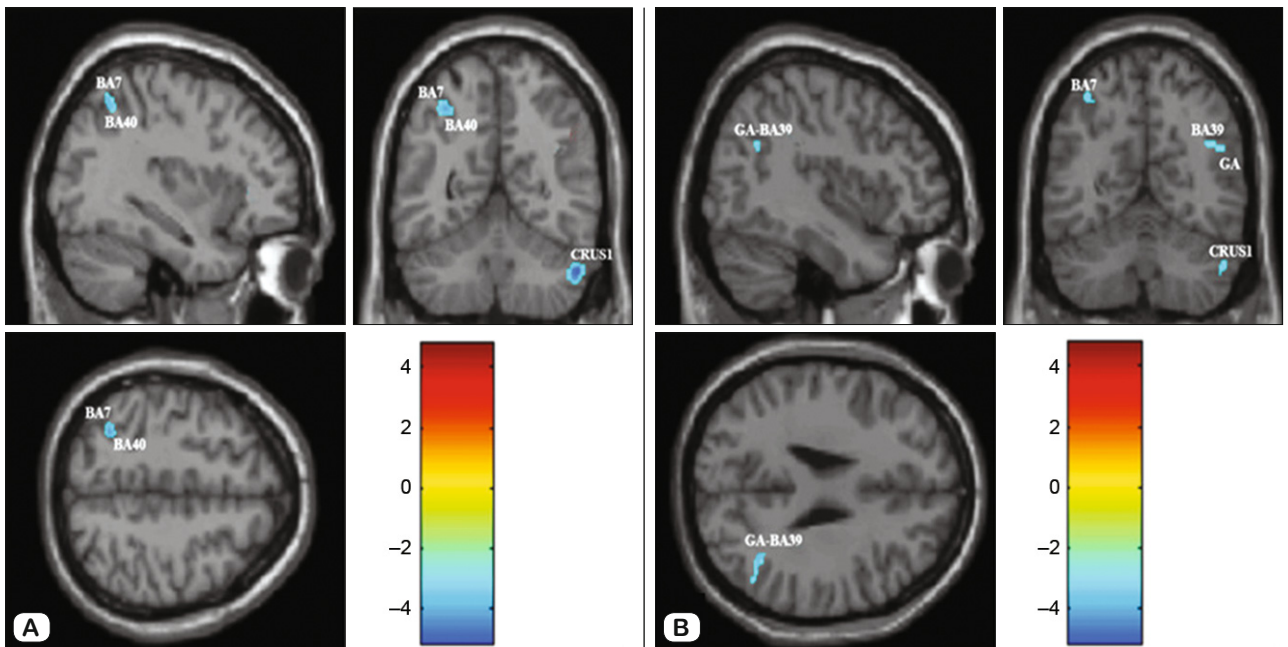


Fig 3. Altered gray matter volume of post-COVID-19 group and healthy group in single T1 images ($p < 0.001$). Blue area shows the decrease in GM volume of COVID-19 patients. A: BA7: Brodmann area 7, BA40: Brodmann area 40. B: GA: Gyrus angularis.

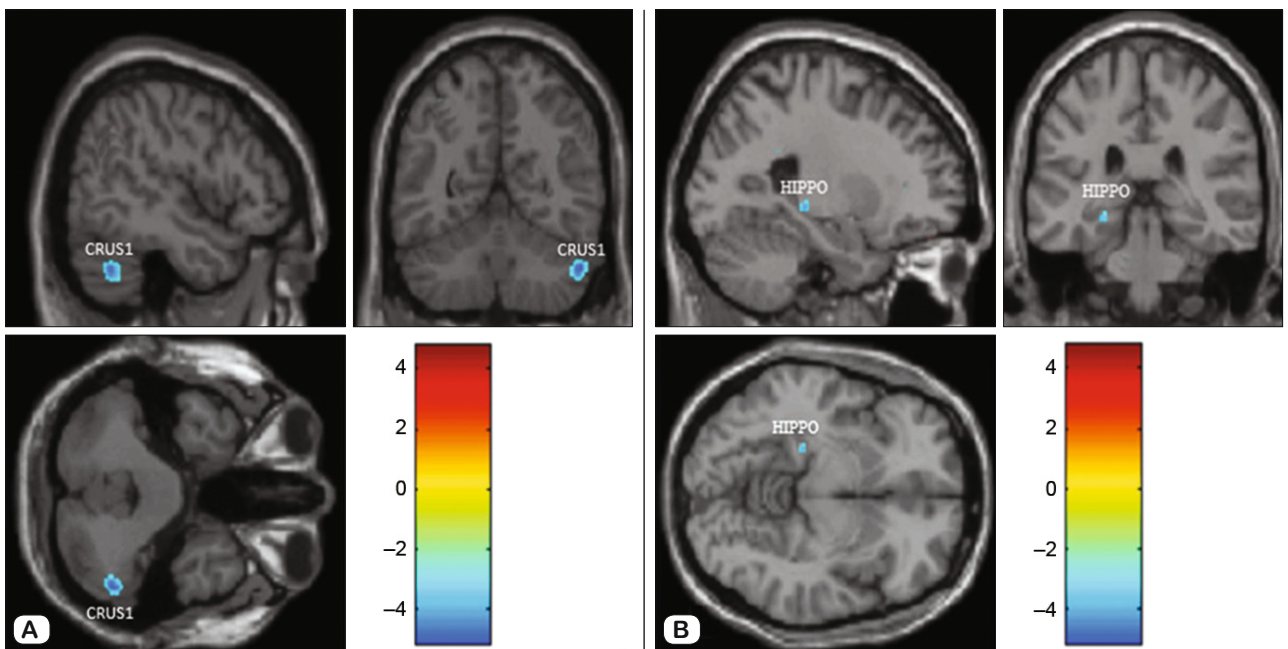


Fig 4. Altered gray matter volume of post-COVID-19 group and healthy group in single T1 images ($p < 0.001$). Blue area shows the decrease in GM volume of COVID-19 patients. A: Lobulus semilunaris superior-crus 1. B: HIPPO: Hippocampus.

ing the COVID-19 pandemic, neurological symptoms were first reported by Mao et al (1). These symptoms were observed in 78 (36.4%) of 214 patients infected with COVID-19. From most to least, in order of frequency; dizziness, headache, confusion, acute cerebrovascular disease (CVD), ataxia, and seizures. It was also reported in this study that peripheral nervous system disorders

(taste-smell disorder, visual impairment and neuropathy), musculoskeletal system disorders, level of consciousness (drowsiness, stupor and coma) and content of consciousness (confusion and delirium) were changed (1). In our study, the clinical symptoms of participants who had COVID-19 were, in order of frequency; muscle-joint pain (62%), loss of smell (50%), loss of taste (40%),

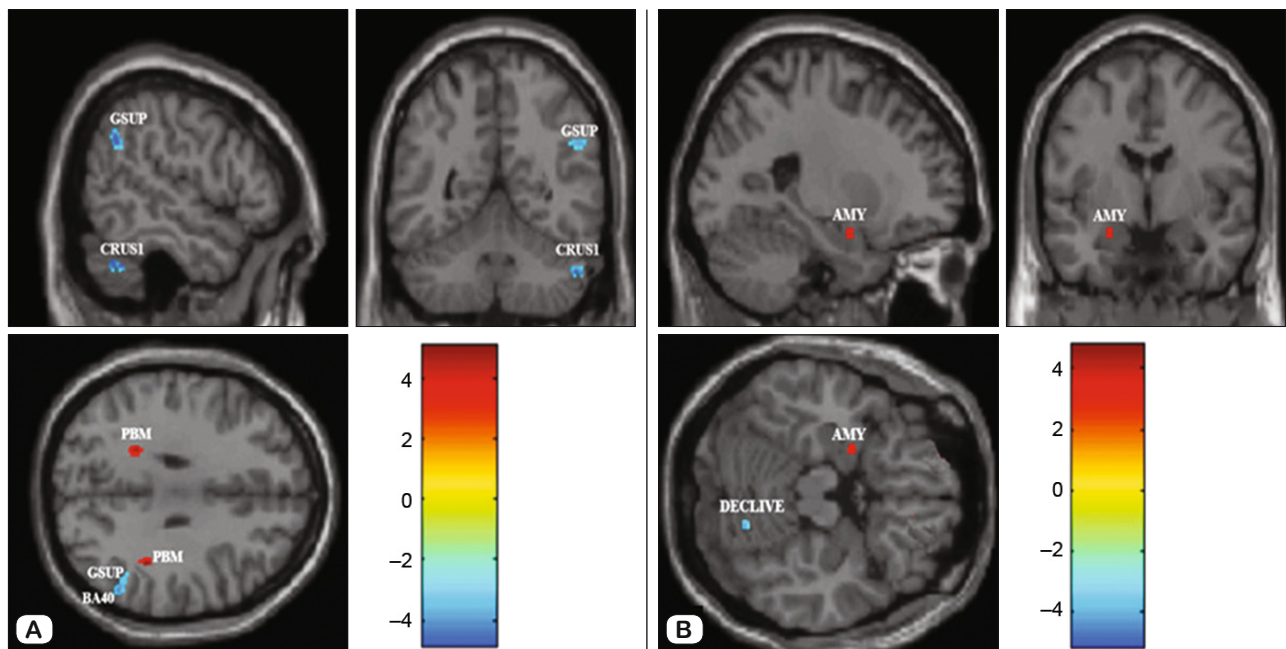


Fig 5. Altered gray matter volume of post-COVID-19 group and healthy group in single T1 images ($p < 0.001$). Red area shows GM volume increase, blue area shows GM volume decrease in post-COVID-19 group. A: GSUP: Gyrus supramarginalis, PBM: Lobus parietalis, BA40: Brodmann area 40. B: AMY: Amygdala.

Tab. 3. Significant gray matter decreases in post-COVID-19 group > healthy group using uncorrected maps at $p < 0.001$ (extent threshold voxels: 50).

No	Regions	Cluster extent (mm ³)	MNI coordinates (x, y, z)			p
1	Pons	246	-9	-30	-31.5	<0.001
2	Gyrus frontalis inferior (pars triangularis)	177	-30	33	4.5	<0.001
3	Lobus frontalis (Gyrus orbitalis medialis, Gyrus orbitalis superior, Gyrus rectus) + Brodmann area 11	299	16.5	39	-18	<0.001
4	Gyrus cinguli	55	-6	46	3	<0.001
5	Gyrus parietalis superior (Brodmann area 7)	100	-31.5	-57	49.5	<0.001
6	Gyrus parietalis inferior	68	-35	-55	51	<0.001
7	Gyrus supramarginalis (Brodmann area 40)	129	54	-56	33	<0.001
8	Gyrus angularis (Brodmann area 39)	64	39	-57	27	<0.001
9	Cerebellum (Lobulus semilunaris superior – Crus 1)	209	51	-56	-38	<0.001
10	Cerebellum (Declive)	77	19.5	-72	-19.5	<0.001
11	Hippocampus	126	-24	-32	-7	<0.001

MNI: Montreal Neurological Institute

headache (40%), dizziness (20%), memory problems/inability to focus (10%).

The Angiotensin Converting Enzyme-2 (ACE2) receptor found in alveolar cells in the lung is also found in cardiorespiratory neurons in the brainstem, motor cortex, and nucleus raphe in experimental animals and has been informative in terms of the way the virus enters the brain (11, 12). It has been emphasized that COVID-19 may cause serious respiratory symptoms by affecting the CNS, especially the respiratory center in the brainstem (7,9,13). Guedjet al (14), while detecting hypometabolism in the pons in COVID-19 patients, Mancaet al (15) found mild hypermetabolism in the pons. Al-Dalahmahet al (16) found signs of inflammation in the pons region of a COVID-19 patient. In our study, it was observed that there was a decrease in GM density in pons

in a post-COVID-19 group compared to the healthy group. The decrease in GM density in the pons, which controls the inspiration and expiration mechanisms, may reveal the cause of possible respiratory problems in COVID-19.

Studies have shown that COVID-19 infection has been characterized by olfactory and gustatory disorders (1,6,17–20). It has been reported that anosmia in cases of COVID-19 occurs due to the involvement of the gyrus rectus and/or bulbus olfactorius (14,20). Politiet al (20) reported a COVID-19 patient with bilateral hyperintensity in gyrus rectus/orbitofrontal cortex MRI. However, Galougahiet al (18) reported that their study showed normal intensity in the bulbus olfactorius of a COVID-19 patient with anosmia. On the other hand, Guedjet al (14) found hypometabolism in the gyrus rectus and bulbus olfactorius in COVID-19 patients

in their study with 35 COVID-19 patients and 44 healthy participants.

Lu et al (21) reported higher GM volume in the bulbus olfactorius in the brain MRI study of the post-COVID-19 group compared to healthy individuals. In our study, while no difference was observed in bulbus olfactorius in the post-COVID-19 group compared to healthy individuals, it was detected that there was a decrease in GM density in the orbitofrontal cortex/gyrus rectus and Brodmann area 11 involving the perception of odors. The orbitofrontal cortex/gyrus rectus and Brodmann area 11 receive dense afferent fibers from the bulbus olfactorius. The decrease in GM density due to neuronal degeneration in these counted regions can be seen as an explanatory cause of hyposmia and anosmia.

Niesenet al (19), in their Positron Emission Tomography-Magnetic Resonance (PET-MR) study, they compared COVID-19 patients with olfactory disorders and healthy individuals and found that there was a significant decrease in regional glucose consumption in the bilateral dorso-lateral prefrontal cortex, gyri orbitales in lobus frontalis, and anterior part of gyrus cinguli. In our study, a reduction in GM density in gyrus orbitalis medialis and gyrus orbitalis superior, which are thought to represent the decision-making, taste, and smell centers in the post-COVID-19 group, and gyrus cinguli, which also belongs to the emotional limbic system, was observed. The decrease in GM density in this region can explain the mood change in individuals with COVID-19.

Duanet al (22) compared 58 COVID-19 patients with neurological symptoms and 62 healthy participants, utilizing Surface-Based Morphometry (SBM) analysis, a multivariate extension of VBM. They found that GM volume in the lobus frontalis in the COVID-19 group was lower than in the control group. The same study found a significant decrease in GM volume in gyrus fusiformis, gyrus temporalis medius, and inferior in 58 COVID-19 patients, in those with fever (29 patients) compared to those without fever (29 patients). In our study, although no findings related to gyrus temporalis were found in the post-COVID-19 group, a decrease in GM density was detected in gyri orbitales, gyrus rectus, Brodmann 11th area in gyrus frontalis, and pars triangularis (which has a role in speech function). Considering that the attention deficit, disorientation, inability to focus, and memory problems persist even after recovery of COVID-19 patients, our results and other findings in the literature show that abnormalities in lobus frontalis and temporalis occur in COVID-19 patients and that these abnormalities may be permanent.

Qin et al (23) examined the microstructure of GM and WM in MR images of mild to severe COVID-19 patients without any neurological symptoms in the acute phase, 3 months after infection. In the severe COVID-19 group, cortical thickness and volume decreased in the insula, hippocampus, and gyrus temporalis superior. In our study, GM, BM, and CSF volumes of the whole brain and TIV were lower in the post-COVID-19 group. Our findings support the literature and show the long-term effects of the disease on the brain.

Analytical neuroimaging studies of COVID-19 are still scarce. Lu et al (21) used the VBM method to examine the difference in

Tab. 4. Significant gray and white matter increase in post-COVID-19 group > healthy group using uncorrected maps at p<0.001 (extent threshold voxels: 50).

No	Regions	Cluster extent (mm ³)	MNI coordinates (x, y, z)			p
1	Amygdala-GM	63	-26	-3	-19	<0.001
2	Lobus parietalis-WM	85	-22.5	-45	30	0.112

MNI: Montreal Neurological Institute. GM: Gray matter, WM: White matter

GM and WM volume, and density in 60 recovered COVID-19 patients and 39 non-COVID-19 controls. In COVID-19 group, gyrus olfactorius (COVID-19: 1.37 cm³, healthy: 1.29 cm³), hippocampus (COVID-19: 4.20 cm³, healthy: 3.94 cm³), insula (COVID-19: 7.60 cm³, healthy: 7.20 cm³), left gyri temporales transversi (Heschl gyrus) (COVID-19: 0.71 cm³, healthy: 0.64 cm³), and right gyrus cinguli (COVID-19: 8.05 cm³, healthy: 7.78 cm³) had higher GM volume and density than the control group. Contrary to this, our study detected a decrease in GM density in the orbitofrontal cortex, gyrus rectus, hippocampus, and gyrus cinguli in the post-COVID-19 group. We think that due to the difference in the degree of illness of COVID-19 patients, Lu et al (21)'s results contradict ours.

People are afraid and anxious because of the global COVID-19 pandemic. The COVID-19 Fear Scale created by Ahorsuet al (2020) was used in a study to determine COVID-19 fear in the epidemic process of people with and without chronic disease. In this study, the mean COVID-19 fear scale score was higher in the patient group than in the healthy group (24).

Tu et al (25) evaluated the structural and functional changes related to post-traumatic stress symptoms in COVID-19 patients in two consecutive periods, 3 months and 6 months after the initial infection. As a result of this study, they found an increase in the functional activity of the bilateral hippocampus and amygdala in COVID-19 patients. Like Tu et al (25), we saw an increase in GM density in the amygdala in the post-COVID-19 group, which is involved in processing fear-related emotions and memories. Our results are similar to those of other studies.

Conclusion

The symptoms related to COVID-19 may differ personally during the treatment process, and the effect of the disease on the body after treatment may vary. Despite numerous studies, it remains unclear what kind of complications COVID-19 causes during the chronic phase. There are numerous opinions regarding the permanent complications caused by the virus in patients, and there is ongoing research in this field. As a result of our study, it was determined that COVID-19 negatively affects many structures in the nervous system. Therefore, we believe that our results will be a reference for future studies. In this context, our study is pioneering to determine what COVID-19 patients may encounter in the short and long term, what consequences COVID-19 may have, and the etiology of these possible problems.

Funding: Erciyes University Scientific Research Projects Coordination Unit (TDK-2020-10597)

References

1. **Mao L, Jin H, Wang M et al.** Neurologic Manifestations of Hospitalized Patients With Coronavirus Disease 2019 in Wuhan, China. *JAMA Neurol* 2020; 77 (6): 1–9. DOI:10.1001/jamaneurol.2020.1127.
2. **Tsivgoulis G, Palaodimou L, Katsanos AH, Caso V, Köhrmann M, Molina C.** Neurological manifestations and implications of COVID-19 pandemic. *Ther Adv Neurol Disord* 2020; 13: 1–14. DOI:10.1177/1756286420932036.
3. **Arbour N, Day R, Newcombe J, Talbot PJ.** Neuroinvasion by human respiratory coronaviruses. *J Virol* 2000; 74 (19): 8913–8921. DOI:10.1128/jvi.74.19.8913-8921.2000.
4. **Beghi E, Feigin V, Caso V, Santalucia P, Logroscino G.** COVID-19 Infection and Neurological Complications: Present Findings and Future Predictions. *Neuroepidemiology* 2020; 54 (5): 1–6. DOI:10.1159/000508991.
5. **Koralnik IJ, Tyler KL.** COVID-19: A Global Threat to the Nervous System. *Ann Neurol* 2020; 88: 1–11. DOI: 10.1002/ana.25807.
6. **Lechien JR, Chiesa-Estomba CM, De Siati DR, Horoi M, Le Bon SD, Rodriguez A.** Olfactory and gustatory dysfunctions as a clinical presentation of mild-to-moderate forms of the coronavirus disease (COVID-19): a multicenter European study. *Eur Arch Otorhinolaryngol* 2020; 277 (8): 2251–2261. DOI:10.1007/s00405-020-05965-1.
7. **Li YC, Bai WZ, Hashikawa T.** The neuroinvasive potential of SARS-CoV2 may play a role in the respiratory failure of COVID-19 patients. *J Med Virol* 2020; 92 (6): 552–555. DOI:10.1002/jmv.25728.
8. **Marcic L, Marcic M, Kojundzic SL, Marcic B, Capkun V, Vukojevic K.** Personalized Approach to Patient with MRI Brain Changes after SARS-CoV-2 Infection. *J Pers Med* 2021; 11 (6): 442. DOI:10.3390/jpm11060442.
9. **Baig AM.** Neurological manifestations in COVID-19 caused by SARS-CoV-2. *CNS Neurosci Ther* 2020; 26 (5): 499–501. DOI:10.1111/cns.13372.
10. **Poillon G, Obadia M, Perrin M, Savatovsky J, Lecler A.** Cerebral Venous Thrombosis associated with COVID-19 infection: causality or coincidence? *J Neuroradiol* 2021; 48 (2): 121–124. DOI:10.1016/j.neurad.2020.05.003.
11. **Chen T, Wu D, Chen H, Yan W, Yang D, Chen G.** Clinical characteristics of 113 deceased patients with coronavirus disease 2019: retrospective study. *BMJ* 2020; 368: m1091. DOI:10.1136/bmj.m1295.
12. **Doobay MF, Talman LS, Obr TD, Tian X, Davisson RL, Lazarigues E.** Differential expression of neuronal ACE2 in transgenic mice with overexpression of the brain reninangiotensin system. *Am J Physiol Regul Integr Comp Physiol* 2007; 292 (1): R373–R381. DOI:10.1152/ajpregu.00292.2006.
13. **Cheng Q, Yang Y, Gao J.** Infectivity of human coronavirus in the brain. *EBioMedicine* 2020; 56: 102799. DOI:10.1016/j.ebiom.2020.102799.
14. **Guedj E, Million M, Dudouet P et al.** 18 F-FDG brain PET hypometabolism in post-SARS-CoV-2 infection: substrate for persistent/delayed disorders? *Eur J Nucl Med Mol Imaging* 2021; 48 (2): 592–595. DOI:10.1007/s00259-020-04973-x.
15. **Manca R, De Marco M, Ince PG, Venneri A.** Heterogeneity in Regional Damage Detected by Neuroimaging and Neuropathological Studies in Older Adults with COVID-19: A Cognitive-Neuroscience Systematic Review to Inform the Long-Term Impact of the Virus on Neurocognitive Trajectories. *Front Aging Neurosci* 2021; 13: 646908. DOI:10.3389/fnagi.2021.646908.
16. **Al-Dalahmah O, Thakur KT, Nordvig AS, Prust ML, Roth W, Lignelli A.** Neuronophagia and microglial nodules in a SARS-CoV-2 patient with cerebellar hemorrhage. *Acta Neuropathol Commun* 2020; 8: 147.
17. **Chen N, Zhou M, Dong X, Qu J, Gong F, Han Y.** Epidemiological and clinical characteristics of 99 cases of 2019 novel coronavirus pneumonia in Wuhan, China: a descriptive study. *Lancet* 2020; 395 (10223): 507–513. DOI: 10.1016/S0140-6736(20)30211-7.
18. **Galougahi MK, Ghorbani J, Bakhshayeshkaram M, Naeini AS, Haseli S.** Olfactory Bulb Magnetic Resonance Imaging in SARS-CoV-2-Induced Anosmia: The First Report. *Acad Radiol* 2020; 27: 892–893. DOI:10.1016/j.acra.2020.04.002.
19. **Niesen M, Trotta N, Noel A, Coolen T, Fayad G, Leurkin-Sterk G.** Structural and metabolic brain abnormalities in COVID-19 patients with sudden loss of smell. *Eur J Nucl Med Mol Imaging* 2021; 48 (6): 1890–1901. DOI: 10.1007/s00259-020-05154-6.
20. **Politi LS, Salsano E, Grimaldi M.** Magnetic Resonance Imaging Alteration of the Brain in a Patient with Coronavirus Disease 2019 (COVID-19) and Anosmia. *JAMA Neurol* 2020; 77: 1028–1029. DOI:10.1001/jamaneurol.2020.2125.
21. **Lu Y, Li X, Geng D, et al.** Cerebral micro-structural changes in COVID-19 patients- an MRI-based 3-month follow-up study. *EClinicalMedicine* 2020; 25: 100484. DOI:10.1016/j.eclinm.2020.100484.
22. **Duan K, Premi E, Pilotto A, et al.** Alterations of frontal-temporal gray matter volume associate with clinical measures of older adults with COVID-19. *Neurobiol Stress* 2021; 14: 100326.
23. **Qin Y, Wu J, Chen T, et al.** Long-term microstructure and cerebral blood flow changes in patients recovered from COVID-19 without neurological manifestations. *J Clin Invest* 2021; 131 (8): e147329. DOI:10.1172/JCI147329.
24. **Alacahan Yiğit S.** Daily life changes, level of mood and COVID-19 fears of adults with chronic disease in COVID-19 epidemic process. Dissertation, University of KahramanmaraşSütçü İmam, 2021: 40–56.
25. **Tu Y, Zhang Y, Li Y, et al.** Post-traumatic stress symptoms in COVID-19 survivors: a self-report and brain imaging follow-up study. *Mol Psychiatry* 2021; 26: 7475–7480. DOI:10.1038/s41380-021-01223-w.

Received December 17, 2022.

Accepted January 7, 2023.