

Quadrantwise Comparison of Lens-Iris Distance in Patients With Pseudoexfoliation Syndrome and Age-matched Controls

Eray Atalay, MD,* Nevbahar Tamçelik, MD,† and Mustafa D. Bilgeç, MD‡

Purpose: To perform a quadrantwise comparison of the minimum distance between the posterior iris and the anterior lens in eyes with pseudoexfoliation syndrome (PXS) and age-matched controls.

Patients and Methods: This study was designed as a prospective cross-sectional study. The study population consisted of 60 patients with PXS and 50 age-matched controls. Anterior segment Scheimpflug images of segments 90 to 270, 135 to 315, 180 to 360, and 225 to 45 degrees were exported as high-quality JPEG images (1920 pixels wide, 1048 pixels high; each pixel having a physical dimension of $8.064 \times 8.064 \mu\text{m}$) for further evaluation. The images were analyzed by Image J software. Minimum lens-iris distance (MLID) of the superior, inferior, nasal, and temporal quadrants were analyzed and compared between the groups. Anterior chamber depth, anterior chamber angle, pupillary diameter, average of K1 and K2 (Km), and cataract grading system by Scheimpflug imaging [Oculus Pentacam Nucleus Grading System (PNS)] were also assessed.

Results: The MLIDs of all quadrants in eyes with PXS were shorter than controls and these differences were statistically significant ($P < 0.05$). The shortest distance was recorded in the inferior quadrant followed by the superior, temporal, and nasal quadrants in both groups. Pupillary diameter was the only variable found to be correlated with mean global MLID at a statistically significant level ($r = -0.465$, $P < 0.001$; adjusted for age, sex, anterior chamber angle, anterior chamber depth, PNS, and Km).

Conclusion: Eyes with PXS manifested with shorter mean MLID than controls.

Key Words: lens-iris distance, lens-iris channel, pseudoexfoliation, Scheimpflug, Pentacam, lens displacement, zonule laxity

(*J Glaucoma* 2016;25:95–100)

Pseudoexfoliation syndrome (PXS) is an age-related disorder of the extracellular matrix with several systemic associations. The disease is more prevalent over the age of 50 and is more commonly observed in Scandinavian countries. The hallmark of the disease is pathologic production and progressive accumulation of a fibrillary extracellular matrix, primarily on anterior segment structures.¹ Its presence has been clearly linked with

development of open-angle glaucoma with an increased cumulative probability over time.² Glaucoma associated with PXS is also difficult to manage due to higher mean intraocular pressure (IOP) levels, greater diurnal fluctuations, and marked pressure spikes.³ The most likely cause of elevated IOP in eyes with PXS is generally considered to be related to trabecular meshwork obstruction by abnormal extracellular material or pigment.¹ Zonular weakness has been proposed as a theoretical explanation to intermittent pressure spikes usually related to a change in body position resulting in forward displacement of the crystalline lens, particularly in the prone position.^{3,4} Dehiscence of zonular fibers from their attachments in ciliary body and the lens may also cause a characteristic inferior displacement of the lens.⁵ These features, together with frequent formation of posterior synechia renders these eyes to pupillary block or even ciliary block resulting in angle-closure glaucoma.^{6,7}

The level of overall integrity of zonular fibers in eyes with PXS determines the appropriate alignment and positioning of the crystalline lens relative to the iris. The risks of experiencing significant IOP fluctuations and pupillary block due to increased lens mobility are thus increased, when zonular fibers are progressively impaired during the course of the disease. It might be suggested that the distance between the posterior iris and the lens might, therefore, indirectly reflect the level of zonular weakness. In this study, we aimed to quantify and compare the minimum distance between the posterior iris and the anterior lens of several quadrants in eyes with PXS and age-matched controls, using Scheimpflug photography.

MATERIALS AND METHODS

Study Participants

This prospective cross-sectional study was conducted in Istanbul University Cerrahpasa Ophthalmology Outpatient Clinic between the dates of January 2012 and August 2012. The study population consisted of 60 patients with PXS and 50 age-matched control patients. Informed consent was received from all patients. The protocol in the study adhered to the tenets of the Declaration of Helsinki and Institutional Review Board (IRB)/Ethics Committee approval was obtained.

All patients were consecutively selected from the outpatient clinic. Patients underwent an initial ophthalmologic examination which included noncontact measurement of IOP, visual acuity testing, and dilated slit-lamp examination. Diagnosis of PXS was confirmed by the observation of pseudoexfoliation material after the dilation. Exclusion criteria for all subjects were previous history of intraocular surgery or any laser procedure; patient aged less than 55 or

Received for publication July 27, 2013; accepted June 25, 2014.

From the *Kars State Hospital, Kars Devlet Hastanesi Göz Hastalıkları Polk, Kars, Türkiye; †Istanbul University Cerrahpasa Medical School, Istanbul, Turkey; and ‡Kirsehir Ahi Evran Research Hospital, Kirsehir, Turkey.

Disclosure: The authors declare no conflict of interest.

Reprints: Eray Atalay, MD, Örnek Mah. Kars Devlet Hastanesi Göz Hast. Polk. 36200, Kars Türkiye (e-mail: erayat@gmail.com).

Copyright © 2014 Wolters Kluwer Health, Inc. All rights reserved.

DOI: 10.1097/IJG.0000000000000093

more than 80 years; known or suspected ocular hypertension or glaucoma; previous history of intraocular inflammation; dry eye syndrome; presence of any corneal disease; presence of posterior synechiae, ocular movement disorders; proliferative diabetic retinopathy; myopia or hyperopia >3 D; astigmatism >2 D. Subjects were grouped according to the presence of PXS.

Anterior Segment Imaging and Image Processing

All patients underwent Pentacam HR (Oculus; Optikgeräte GmbH, Wetzlar, Germany) examination 1 week after the initial examination. The device uses a 475-nm monochromatic slit of light to illuminate the cornea and a 1.45-megapixel camera for photography.⁸ Before examination the lights of the examination room were dimmed and the cover cloth was put over the patients to minimize reflections. The examination mode of the Pentacam device was set to 3D scan, 25 pictures per second and 3 consecutive scans were conducted. Only images with a Quality Score > 95 were evaluated and the scan with the highest quality was selected for analysis. Pentacam images of some patients were not eligible for the evaluation due to the distortion of intraocular details caused by high reflection; 4 patients with PXS and 1 control patient were excluded for the mentioned reason.

One eye of each patient was randomly selected for further evaluation of anterior segment images. Anterior chamber depth (ACD), pupillary diameter (PD), anterior chamber angle (ACA), average of K1 and K2 (Km), and cataract grading system by Scheimpflug imaging [Oculus Pentacam Nucleus Grading System (PNS)] were recorded from the Pentacam output. Anterior segment Scheimpflug images of segments 90 to 270, 135 to 315, 180 to 360, and 225 to 45 degrees were exported as high-quality JPEG images (1920 pixels wide, 1048 pixels high; each pixel having a physical dimension of $8.064 \times 8.064 \mu\text{m}$) for further evaluation. The images were analyzed by Image J software (National Institute of Health, Bethesda, MD; available at: <http://imagej.nih.gov/ij/>). To minimize the errors in object detection and to make more accurate analyses, an image segmentation technique was used. Locally adaptive thresholding methods were found to be appropriate for images which have contrast fluctuation between objects of interest and background across the image plane and also from image to image.^{9,10} For this reason, a local adaptive thresholding method of Niblack was used for image segmentation.⁹ After this step, the iris plane and the mass representative of the lens were selected and isolated from the remaining objects. The steps of image processing are summarized in Figure 1.

The minimum distance between the iris planes and the mass representative of the lens were automatically computed using the “Minimum Separation Distance Between Boundaries” java plugin (Produced by Ben Tupper; available at: http://imagejdocu.tudor.lu/doku.php?id=plugin:analysis:minimum_separation_distance:start). Figure 1C shows an output of the plugin. This plugin is configured to calculate the minimum 2-dimensional distance between the selected objects, referred as “minimum lens-iris distance” (MLID) in this study. The calculated value for each correspondent quadrant was recorded for further analysis. The overall mean of the quadrants was defined as “mean global minimum lens-iris distance.”

Statistical Analysis

Collected data were recorded into a Microsoft Excel Datasheet and transferred to SPSS version 19.0 by IBM (SPSS Inc., Chicago, IL) for statistical analysis. Patient age, ACD, ACA, Km, PD, and MLID of the quadrants were normally distributed, meanwhile PNS values showed non-normal distribution. Independent samples *t* tests were used to compare normally distributed variables among the groups. Mean values of MLID of the quadrants within the groups were compared using ANOVA test. Mann-Whitney *U* test was used to compare non-normal distributed data. χ^2 test was used to test differences in the sex distribution of groups. The association between MLID and anterior segment parameters were assessed using Pearson correlation. $P < 0.05$ were considered statistically significant.

RESULTS

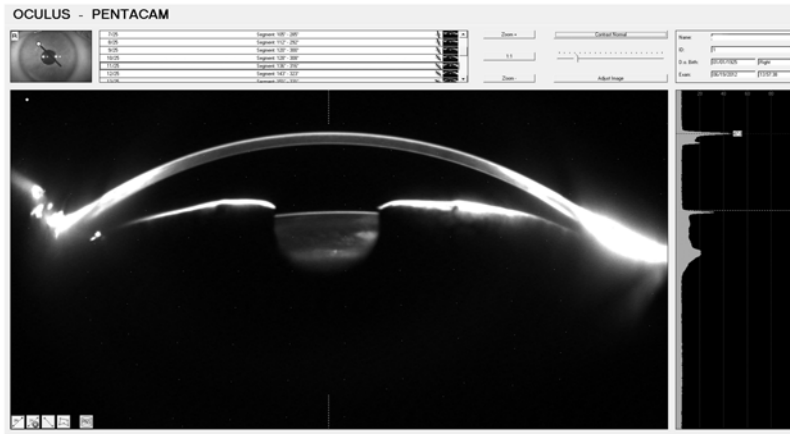
The mean ages of subjects with PXS and controls were 68.38 ± 6.64 years (range, 56 to 80 y) and 68.12 ± 6.26 years (range, 57 to 80 y), respectively. Thirty-one of the 60 patients with PXS and 23 of the 50 control patients were female. There was no statistically significant difference in the age and sex distribution among the groups. Table 1 shows the mean values of MLID of each quadrant for the groups. The mean MLIDs of all quadrants in eyes with PXS were shorter than the eyes of controls and these differences were statistically significant (Table 1).

The mean differences (Δ) between the superior-inferior (mean of superior quadrant – mean of inferior quadrant; $\Delta\text{Sup-Inf}$) and nasal-temporal (mean of nasal quadrant – mean of temporal quadrant; $\Delta\text{Nas-Tem}$) quadrants in eyes with PXS were 5.91 ± 24.24 and $6.00 \pm 27.27 \mu\text{m}$, respectively (Table 2). The corresponding values for controls were 1.91 ± 19.53 and $15.00 \pm 23.06 \mu\text{m}$, respectively. Although $\Delta\text{Sup-Inf}$ and $\Delta\text{Nas-Tem}$ varied among the eyes of the 2 groups, the differences were not statistically significant ($P = 0.350$ and 0.067 , respectively). There was no statistically significant difference among the groups regarding ACD, PD, ACA, and Km.

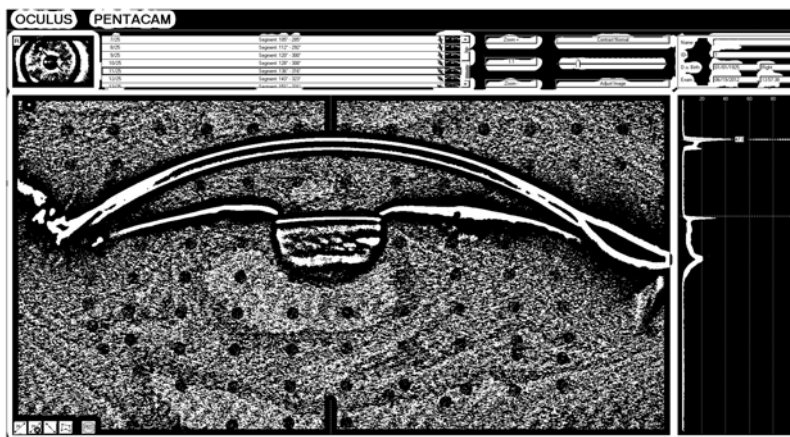
Figure 2 shows a line graph of mean values of MLID for nasal, temporal, superior, and inferior quadrants of both groups. Comparison of the quadrants yielded the shortest mean MLID in the inferior quadrant followed by superior, temporal, and nasal quadrants in both groups. When the quadrants were compared within the groups, the nasal quadrant of controls had a higher mean value compared with the inferior, superior, and temporal quadrants. However, the differences were statistically significant only between nasal-inferior and nasal-superior quadrants ($P = 0.004$ and $P = 0.01$, respectively), whereas the difference between nasal-temporal quadrants was not statistically significant ($P = 0.09$). Meanwhile, the only statistically significant difference was between the nasal and the inferior quadrant in eyes with PXS ($P = 0.006$).

The PNS grading results of the groups are shown in Figure 3. In subjects with PXS, 33 (55%) patients had PNS grade 1, 22 (36.6%) patients had PNS grade 2, and 5 (8.4%) patients had PNS grade 3 nuclear sclerosis. Of the 50 control eyes, 42 (84%) had PNS grade 1, 7 (14%) had PNS grade 2, and 1 (2%) had PNS grade 3 nuclear sclerosis. Subjects with PXS presented with a higher grades of nuclear sclerosis than normal subjects and this difference was statistically significant ($P = 0.001$). PNS grades and mean global MLID were negatively correlated in all

A: Raw Image



B: After image segmentation



C: Selection of area of interest and plug-in output

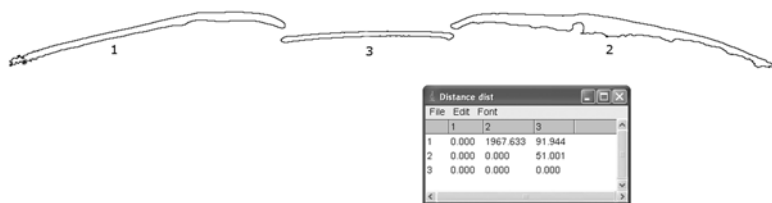


FIGURE 1. An example of an exported Scheimpflug photograph (A) after applying a filter (B) for image segmentation purposes. The area of interest is isolated (C) from the background and the minimum lens-iris distance is automatically calculated by the plugin.

patients when adjusted for age, sex, PD, ACA, ACD, Km [$r = -0.233$, $P = 0.017$; 95% confidence interval (CI), -0.410 to -0.012].

Mean global MLID of female subjects was shorter than the male subjects (Table 3) and this difference was statistically significant ($P = 0.007$). The same pattern was observed in each individual group [mean global MLID in the PXS group (female subjects: $55.24 \pm 18.61 \mu\text{m}$, male subjects: $62.52 \pm 18.59 \mu\text{m}$, 95% CI, -2.41 to 16.99 , $P = 0.138$) and mean global MLID in the control group (female subjects: $72.39 \pm 26.28 \mu\text{m}$, male subjects: $88.25 \pm 29.64 \mu\text{m}$, 95% CI, -0.20 to 31.91 , $P = 0.05$)]. Female subjects were also younger and had a larger mean

PD compared with the male subjects. ($P = 0.002$ and $P = 0.017$, respectively). Other anterior segment parameters, however, did not vary between the sexes. A total of 66% of the male subjects and 70.2% of the female subjects had grade 1 PNS; 26.4% of the male subjects and 26.3% of the female subjects had grade 2 PNS and 7.6% of the male subjects and 3.5% of the female subjects had grade 3 PNS nuclear sclerosis. The PNS grade distribution between the sexes was not statistically significant ($P = 0.641$).

No correlation existed between mean global MLID and ACD, ACA, age, and Km. In the univariate analysis, PD was the only variable found to be correlated with mean global MLID at a statistically significant level ($r = -0.423$,

TABLE 1. Quadrantwise Comparison of Mean Minimum Lens-Iris Distance in Eyes With PXS and Eyes of Controls

| Quadrants | Mean \pm SD | | 95% CI of the Difference | P |
|----------------------------------|-------------------|--------------------|--------------------------|---------|
| | Eyes With PXS | Eyes of Controls | | |
| Superior (μm) | 54.33 \pm 20.10 | 71.50 \pm 35.20 | –28.34 to –5.97 | 0.003 |
| Superotemporal (μm) | 58.70 \pm 23.98 | 76.81 \pm 34.96 | –29.71 to –6.51 | 0.003 |
| Temporal (μm) | 56.88 \pm 23.51 | 76.76 \pm 28.74 | –29.76 to –10.00 | < 0.001 |
| Inferotemporal (μm) | 63.20 \pm 29.94 | 79.54 \pm 30.03 | –27.73 to –4.95 | 0.005 |
| Inferior (μm) | 48.42 \pm 21.82 | 69.58 \pm 28.08 | –30.69 to –11.72 | < 0.001 |
| Inferonasal (μm) | 53.52 \pm 22.17 | 76.69 \pm 31.73 | –33.39 to –12.94 | < 0.001 |
| Nasal (μm) | 62.88 \pm 29.53 | 91.76 \pm 36.11 | –41.29 to –16.48 | < 0.001 |
| Superonasal (μm) | 68.65 \pm 31.48 | 104.92 \pm 41.12 | –50.00 to –22.54 | < 0.001 |
| Global (μm) | 58.39 \pm 18.80 | 80.95 \pm 28.98 | –32.03 to –13.08 | < 0.001 |

CI indicates confidence interval; PXS, pseudoexfoliation syndrome.

$P < 0.001$, 95% CI, -0.565 to -0.256), in all subjects. The correlation was unchanged after adjustment for age, sex, ACA, ACD, PNS, and Km ($r = -0.465$, $P < 0.001$, 95% CI, -0.617 to -0.287). Figure 4 shows the correlation plot and linear regression line between PD versus mean global MLID of the 2 groups. Eyes of controls had a higher correlation coefficient for PD versus mean global lens-iris distance ($r^2 = 0.378$, $P < 0.001$) than eyes with PXS ($r^2 = 0.082$, $P = 0.027$).

DISCUSSION

This study has aimed to elucidate the minimum distance between the lens and the iris of various quadrants, using Scheimpflug photography. Correlation analysis between the anterior segment parameters and the MLID were also assessed. The main findings of the study were significantly shorter MLIDs in eyes with PXS compared with controls and interquadrant differences observed in the overall study population.

The lens and the iris were in closer proximity in eyes with PXS compared with the controls. Several explanations may be proposed for this phenomenon. It is known that even in the early stages of PXS, a precapsular layer (0.5 to 3.5 μm) of pseudoexfoliation material covers the surface of the anterior lens capsule. Pseudoexfoliation material also accumulates on the posterior pigment epithelial layer of the iris and also the iris stroma.¹ These factors may bring the iris and the lens into closer contact, thereby result in the shortening of lens-iris distance. In addition, anterior movement of the crystalline lens due to zonular weakness

may also be responsible for the relative proximity of the lens and the iris in eyes with PXS compared with the controls.^{1,3,11} Eyes with pseudoexfoliation material deposition also have an increased likelihood of developing cataract; chiefly of the nuclear sclerotic variant.¹² Findings in this study was in concordance with these data, as eyes with PXS had higher grades of PNS than controls. In fact, PNS grades were negatively correlated with mean global MLID, with statistical significance, when adjusted for age, sex, PD, ACA, ACD, and Km. The increased bulk of the lens might also have contributed to the proximity of the lens and iris in eyes with PXS, in this study.

There were significant interquadrant variations in mean MLID in the overall study population. In theory, quadrantwise differences in lens-iris distance may be related with quadrantwise differences in crystalline lens position (tilt and decentration) and ciliary body location (which indirectly influence lens position). These factors, supposedly, determine the relative position of the lens to that of the posterior iris. A study which evaluated lens tilt and decentration in both eyes of 11 healthy subjects with phakic eyes found temporal tiltation of the crystalline lens with respect to the fixation axis (on average by 4.6 degrees) and inferior displacement with respect to the pupil center by approximately 0.3 mm.¹³ These data are in concordance with the current study's findings. The mean MLIDs in the superior and nasal quadrants were higher than their opposing quadrants in all patients. A population-based cross-sectional study which evaluated various anterior segment parameters of 461 subjects by ultrasound biomicroscopy have found the location of the ciliary body

TABLE 2. Anterior Segment Parameters and Mean Differences of Minimum Lens-Iris Distances Between Superior-Inferior and Nasal-Temporal Quadrants in Eyes With PXS and Eyes of Controls

| | Mean \pm SD | | 95% CI of the Difference | P |
|--|------------------|-------------------|--------------------------|-------|
| | Eyes With PXS | Controls | | |
| ACD (mm) | 2.45 \pm 0.37 | 2.56 \pm 0.29 | –0.23 to 0.02 | 0.109 |
| PD (mm) | 2.73 \pm 0.50 | 2.73 \pm 0.53 | –0.19 to 0.20 | 0.976 |
| ACA (deg.) | 30.00 \pm 5.53 | 30.92 \pm 5.30 | –2.98 to 1.13 | 0.375 |
| Km (mm) | 7.68 \pm 0.28 | 7.67 \pm 0.25 | –0.09 to 0.11 | 0.846 |
| $\Delta\text{Sup-Inf}$ (μm) | 5.91 \pm 24.24 | 1.91 \pm 19.53 | –4.44 to 12.43 | 0.350 |
| $\Delta\text{Nas-Tem}$ (μm) | 6.00 \pm 27.27 | 15.00 \pm 23.06 | –18.66 to 0.65 | 0.067 |

ACA indicates anterior chamber angle; ACD, anterior chamber depth; Km, average of K1 and K2; PD, pupillary diameter; PXS, pseudoexfoliation syndrome; $\Delta\text{Nas-Tem}$, mean differences of minimum lens-iris distance between the nasal and temporal quadrants; $\Delta\text{Sup-Inf}$, mean differences of minimum lens-iris distance between the superior and inferior quadrant.

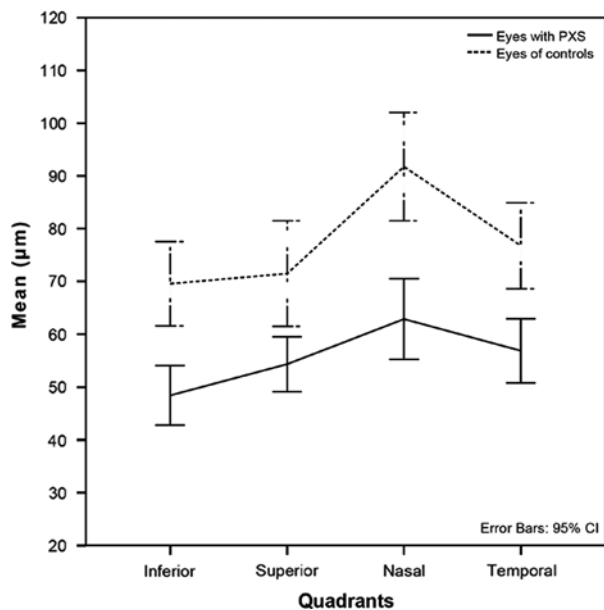


FIGURE 2. Comparison of mean minimum lens-iris distance in the inferior, superior, nasal, and temporal quadrants in eyes with pseudoexfoliation syndrome (PXS) and controls. CI indicates confidence interval.

deepest in the nasal quadrant, followed by the temporal, inferior, and superior quadrant.¹⁴ These findings would suggest a decreasing order of mean lens-iris distance in the same sequence; the same order observed in this study with the exception of a change in places in the vertical quadrants (Fig. 2). Moreover, the superior-inferior variation was even higher in eyes with PXS ($5.91 \pm 24.24 \mu\text{m}$) compared with the controls ($1.91 \pm 19.53 \mu\text{m}$). This contradiction could be explained by the effects of gravity which would cause an inferior displacement of the lens, which is particularly more pronounced in eyes with PXS due to zonular weakness.^{1,3,11,12}

Mean global MLID also differed between male and female subjects, with statistical significance. It is interesting to find this variation despite an intersex difference in mean ACD, as it is generally accepted that females have a shallower ACD compared with males.¹⁵⁻¹⁷ The difference between the intersex distributions of PNS grades also did not have statistical significance. Information derived from this study would suggest this variation to be possibly related with the differences in the mean PD of male and female subjects. It is observed that PD is negatively correlated with MLID and it might be proposed that female subjects exhibited a shorter MLID due to their higher mean PD's compared with male subjects. Relevant to the

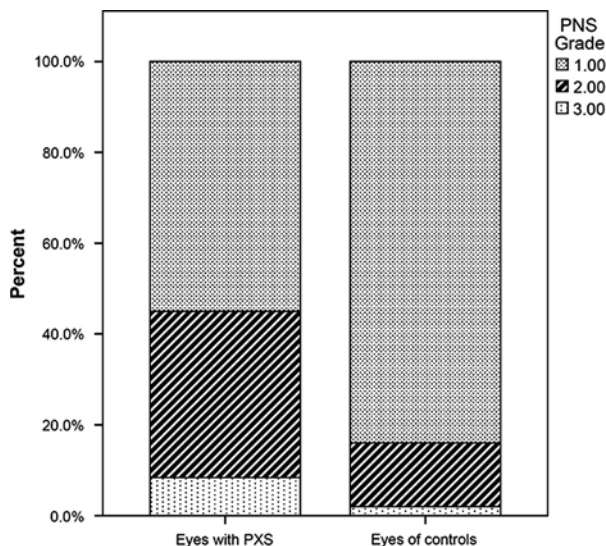


FIGURE 3. Distribution of Oculus Pentacam Nucleus Grading System (PNS) in eyes with pseudoexfoliation syndrome (PXS) and controls.

previous finding, a population-based study has found a more deeply located ciliary body in men compared with women¹⁴ which would be suggested to cause a more posteriorly positioned lens and eventually, a longer distance between the lens and the iris in males. The mean difference between the ages of female and male subjects ($3.78 \pm 1.18 \text{ y}$), although statistically significant, seem to be clinically irrelevant with intersex variations of MLID.

The lens-iris channel is an extremely thin passage between the posterior iris and the anterior lens, which is known to constitute aqueous flow resistance from the posterior to the anterior chamber.¹⁸ The resistance is maximized when the pupil is in a mid-dilated position, referred to as relative pupillary block.¹⁹⁻²¹ In accordance with this information, this study has shown that PD is negatively correlated with MLID at a statistically significant level (Fig. 4). This statement, however, can only be true in a range of PD represented in this study, therefore it cannot be generalized. Eyes with PXS seemingly had a lower correlation coefficient than controls, probably due to inefficient resolution of Scheimpflug photography in an already shortened lens-iris passage.

The current method of calculating lens-iris distance might be implemented in various anterior segment imaging devices thereby enhancing our understanding of in vivo anatomy of the lens and the iris. This would be particularly of benefit in detecting patients at risk for pupillary block

TABLE 3. Demographic and Anterior Segment Characteristics of Female and Male Subjects (PXS+Controls)

| | Mean ± SD | | 95% CI of the Difference | P |
|------------------|-----------------|---------------|--------------------------|-------|
| | Female Subjects | Male Subjects | | |
| Age (y) | 66.43 ± 5.66 | 70.22 ± 6.71 | 1.44 to 6.12 | 0.002 |
| Global MLID (µm) | 62.16 ± 23.40 | 75.63 ± 27.82 | 3.77 to 23.16 | 0.007 |
| ACD (mm) | 2.50 ± 0.35 | 2.50 ± 0.33 | -0.12 to 0.13 | 0.968 |
| ACA (deg.) | 29.94 ± 5.88 | 30.94 ± 4.88 | -1.05 to 3.05 | 0.336 |
| PD (µm) | 2.84 ± 0.49 | 2.61 ± 0.51 | -0.4263 to -0.4267 | 0.017 |

ACA indicates anterior chamber angle; ACD, anterior chamber depth; MLID, minimum lens-iris distance; PD, pupil diameter.

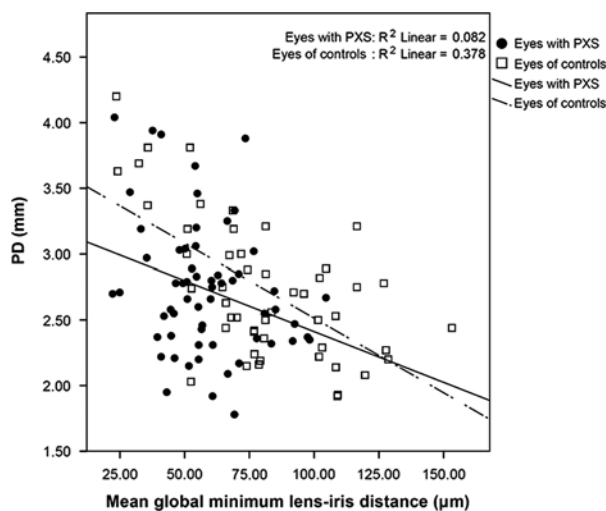


FIGURE 4. Correlation plot and linear regression line of pupillary diameter (PD) versus mean global minimum lens-iris distance in eyes with pseudoexfoliation syndrome (PXS) and controls.

and angle closure. In addition, serial measurements of lens-iris distance (under standardized conditions) in eyes with PXS might reflect the rate of disease progression due to aforementioned reasons, thereby providing a quantitative measure of disease progression.

One of the major limitations of this study is the inadequacy of spatial resolution of Scheimpflug photography to accurately assess lens-iris anatomy and configuration. The axial and lateral resolutions of Pentacam HR, used in this study, are $10\ \mu\text{m}$.²² Scheimpflug photography is also greatly influenced by internal ocular reflections which might have impaired our calculations. In addition, applied filters might also have worsened resolution-related problems. Correlation of MLID with axial length and lens thickness measurements would also be of interest. To our knowledge, this is the first reported study of lens-iris distance measurement using Scheimpflug photography.

REFERENCES

- Ritch R, Schlötzer-Schrehardt U. Exfoliation syndrome. *Surv Ophthalmol.* 2001;45:265–315.
- Konstas AGP, Stewart WC, Stromann GA. Clinical presentation and initial treatment patterns in patients with exfoliation glaucoma versus primary open-angle glaucoma. *Ophthalmol Surg Lasers.* 1997;28:111–117.
- Schlötzer-Schrehardt U, Naumann GO. Ocular and systemic pseudoexfoliation syndrome. *Am J Ophthalmol.* 2006;141:921–937.
- Lanzl IM, Merte RL, Graham AD. Does head positioning influence anterior chamber depth in pseudoexfoliation syndrome? *J Glaucoma.* 2000;9:214–218.
- Bartholomew RS. Lens displacement associated with pseudo-capsular exfoliation. A report on 19 cases in the Southern Bantu. *Br J Ophthalmol.* 1970;54:744–750.
- von der Lippe I, Kühle M, Naumann GO. Pseudoexfoliation syndrome as a risk factor for acute ciliary block angle closure glaucoma. *Acta Ophthalmol.* 1993;71:277–279.
- Mardin CY, Schlötzer-Schrehardt U, Naumann GO. “Masked” pseudoexfoliation syndrome in reoperated eyes with circular posterior synechiae: clinical-electron microscopic correlation. *Arch Ophthalmol.* 2001;119:1500–1503.
- McAlinden C, Khadka J, Pesudovs K. A comprehensive evaluation of the precision (repeatability and reproducibility) of the Oculus Pentacam HR. *Invest Ophthalmol Vis Sci.* 2011;52:7731–7737.
- Korzynska A, Roszkowiak L, Lopez C, et al. Validation of various adaptive threshold methods of segmentation applied to follicular lymphoma digital images stained with 3,3'-Diaminobenzidine and haematoxylin. *Diagn Pathol.* 2013;8:48.
- Brezinski ME. *Optical Coherence Tomography: Principles and Applications.* Burlington, MA: Academic Press; 2006.
- Conway RM, Schlötzer-Schrehardt U, Kühle M, et al. Pseudoexfoliation syndrome: pathological manifestations of relevance to intraocular surgery. *Clin Experiment Ophthalmol.* 2004;32:199–210.
- Puska P, Tarkkanen A. Exfoliation syndrome as a risk factor for cataract development: five-year follow-up of lens opacities in exfoliation syndrome. *J Cataract Refract Surg.* 2001;27:1992–1998.
- Schaeffel F. Binocular lens tilt and decentration measurements in healthy subjects with phakic eyes. *Invest Ophthalmol Vis Sci.* 2008;49:2216–2222.
- Henzan IM, Tomidokoro A, Uejo C, et al. Ultrasound biomicroscopic configurations of the anterior ocular segment in a population-based study the Kumejima Study. *Ophthalmology.* 2010;117:1720–1728.
- Eysteinnsson T, Jonasson F, Arnarsson A, et al. Relationships between ocular dimensions and adult stature among participants in the Reykjavik Eye Study. *Acta Ophthalmol Scand.* 2005;83:734–738.
- Shufelt C, Fraser-Bell S, Ying-Lai M, et al. Los Angeles Latino Eye Study Group. Refractive error, ocular biometry, and lens opalescence in an adult population: the Los Angeles Latino Eye Study. *Invest Ophthalmol Vis Sci.* 2005;46:4450–4460.
- Hashemi H, Khabazkhoob M, Miraftab M, et al. The distribution of axial length, anterior chamber depth, lens thickness, and vitreous chamber depth in an adult population of Shahroud. *Iran BMC Ophthalmol.* 2012;12:50.
- Stamper RL, Lieberman MF, DrakeMiller MV. Primary angle-closure glaucoma. In: Stamper RL, Lieberman MF, DrakeMiller MV, eds. *Becker-Shaffer's Diagnosis and Therapy of the Glaucomas.* 8th ed. Philadelphia, PA: Mosby Elsevier; 2009:194–195.
- Mapstone R. Closed-angle glaucoma. Theoretical considerations. *Br J Ophthalmol.* 1974;58:36–40.
- Mapstone R. Dilating dangerous pupils. *Br J Ophthalmol.* 1977;61:517–524.
- Tiedeman JS. A physical analysis of the factors that determine the contour of the iris. *Am J Ophthalmol.* 1991;111:338–343.
- Reinstein DZ, Gobbe M, Archer TJ. Anterior segment biometry: a study and review of resolution and repeatability data. *J Refract Surg.* 2012;28:509–520.