

## Case Report

# A Sewing Needle as a Urethral Foreign Body: A Case Report and Literature Review

İ Üntan, E Ersekerici

Department of Urology, Ahi Evran University, Training and Research Hospital, Kırşehir, Turkey

**Received:**

09-Mar-2023;

**Revision:**

29-Apr-2023;

**Accepted:**

17-Aug-2023;

**Published:**

30-Oct-2023

**ABSTRACT**

Foreign bodies in the urethra can occur by self-insertion, and patients often hide the symptoms due to embarrassment. Foreign bodies act as a focus for infection and abscess formation and result in perforation or fistula when not detected on time. Foreign bodies can display symptoms such as frequent urination, dysuria, hematuria, urethrorrhagia, and obstruction. This case discusses a self-inserted urethral sewing needle that was removed cystoscopically from an adolescent.

**KEYWORDS:** *Exploratory behavior, foreign bodies, needles, urethra, urethroscopy*

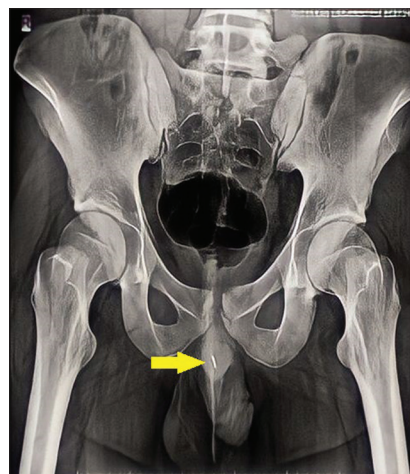
## INTRODUCTION

A great variety of self-inserted foreign bodies through the urethra have been described. The reason for the self-insertion which is relatively more common in men is usually eroticism or psychiatric.<sup>[1]</sup> Self-inserted foreign body cases in the urethra are infrequent.<sup>[2]</sup> Diagnosis can be challenging unless the insertion is confessed. Our presentation aims to report a case of a self-inserted sewing needle through the urethra by an adolescent to allay urethral itching that he felt in the penile root, along with a review of self-inserted sewing needle cases in the available literature.

## CASE PRESENTATION

An 18-year-old healthy single male presented to Kırşehir Ahi Evran University Training and Research Hospital Urology outpatient clinic. He had a limping gait as if he is suffering from epididymitis or orchitis and complained of a stinging sensation in the penis. He had urinary hesitancy and dysuria. Physical examination suspected a needle-like structure being palpated in the bulbar urethra. The palpation area had tenderness and pain. The urinary sediment showed >80 white blood cells/ $\mu$ L and >100 red blood cells/ $\mu$ L. Anteroposterior pelvic radiograph presented a short, straight, wire-shaped radiopacity approximately 15 mm in length in the area corresponding to the root of the penis, which appeared shorter than it

was due to the single dimension [Figure 1]. Cystoscopy was planned for optimal diagnosis and treatment. The patient eventually let the cat out of the bag while being taken to the operation theater and admitted that he used a sewing needle to scratch his urethra and it



**Figure 1:** X-ray of the pelvis demonstrating thin radiopacity in the penile region

**Address for correspondence:** Dr. İ Üntan,

Department of Urology, Ahi Evran University, Training and Research Hospital, Kervansaray Mah. 2019. Sok. No: 1, 40100, Kırşehir, Turkey.  
E-mail: ibrahimuntan@erciyes.edu.tr

This is an open access journal, and articles are distributed under the terms of the Creative Commons Attribution-NonCommercial-ShareAlike 4.0 License, which allows others to remix, tweak, and build upon the work non-commercially, as long as appropriate credit is given and the new creations are licensed under the identical terms.

**For reprints contact:** WKHLRPMedknow\_reprints@wolterskluwer.com

**How to cite this article:** Üntan İ, Ersekerici E. A sewing needle as a urethral foreign body: A case report and literature review. Niger J Clin Pract 2023;26:1588-90.

**Access this article online**

**Quick Response Code:**

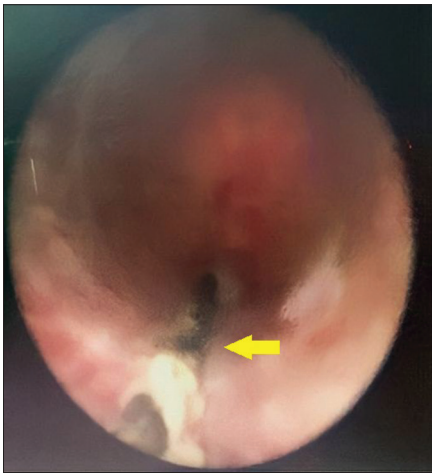

**Website:** www.njcponline.com

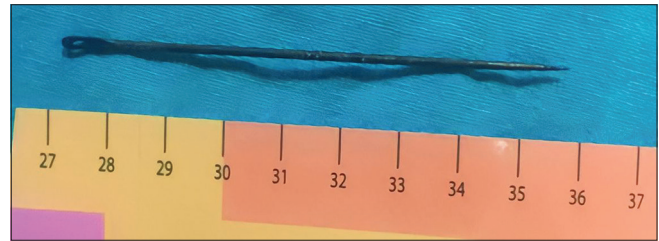
**DOI:** 10.4103/njcp.njcp\_168\_23

**Table 1: Self-inserted sewing-needle cases in the literature**

Author	Age	Symptoms (additional information, if any)	Country	Retrieval method
Al-Zahrani <sup>[1]</sup>	38	Weak urine stream, postvoiding spotting	Saudi Arabia	Urethroscopy
Park <sup>[5]</sup>	13	No symptoms	South Korea	Laparoscopic needle holder after a urethroscopic failure
Prasad Ray <sup>[2]</sup>	12	Hematuria, dysuria	India	Urethroscopy
Singh <sup>[3]</sup>	36	Hard perineal swelling	India	Urethroscopy
Zaghibib <sup>[4]</sup>	14	Dysuria	Tunisia	Urethroscopy
Wang <sup>[7]</sup>	14	Tingling sensation	China	Urethroscopy
Vahidi <sup>[6]</sup>	10	No symptoms	Iran	Forcing transcutaneously

**Figure 2:** Sewing needle observed during urethroscopic visualization

slipped inside. Under general anesthesia, a cystoscope with a 17Fr sheath was introduced into the urethra and a long thin metallic foreign body placed parallel to the urethral axis was observed in the membranous urethra [Figure 2]. The needle was stuck inside the urethra with the eye-side embedded approximately 5 mm in the epithelium in front of the verumontanum, and the tip-side had penetrated the epithelium towards to distal aspect. A grasper was used to move the needle. The needle clutched near its proximal side was moved distally and freed from the embedding mucosa with gentle pressure to the underlying mucosa to prevent the sharp edge from penetrating deeper. Next, the needle was moved proximally and completely liberated. Finally, the needle was grasped by the sharp side and completely extracted from the urethra through a cystoscope. The withdrawn object was a 9-cm oxidized sewing needle [Figure 3]. A urethral catheter was introduced. A preliminary psychiatric evaluation was performed the following day, and no psychiatric disorder was detected. On the second day, the urethral catheter was removed, and the patient was discharged after receiving feedback that his urinary flow was normal. The most common causes of urethral pruritus are urethritis and urinary tract infections; however, the patient did not give us a clue to support any of these. Therefore, the patient was prescribed 100 mg of doxycycline per day empirically.

**Figure 3:** Withdrawn foreign body

Follow-ups implicated that the patient no longer suffered from urethral itching and recovered without complication.

## DISCUSSION

The ingress of foreign bodies into the urethra may be by self-insertion and iatrogenic principally.<sup>[3]</sup> A variety of urethral foreign bodies have been documented, including thermometers, electrical wires, screws, and batteries.<sup>[4]</sup> Hand sewing originated in the Middle East around 4000 BC, and the industrialization of sewing started in Europe and America in the 19<sup>th</sup> century and spread to the whole world. However, in the Near East, Middle East, Far East, and South Asia, household items are sewed traditionally using sewing needles. The literature on self-inserted urethral sewing needles is compatible with this geography [Table 1]. Self-insertion of foreign bodies is rarely seen in children.<sup>[5]</sup> Most patients delay consulting a physician due to embarrassment, causing complications.<sup>[4]</sup> The presentations are usually dysuria and obstruction.<sup>[3]</sup> Physical examination may reveal tenderness and a painful palpable mass at the ventral penile shaft.<sup>[6]</sup> Urinalysis may represent erythrocyturia or leukocyturia.<sup>[4]</sup> Confession prior to examination is essential to avoid nailing the foreign body into the epithelium by palpation.<sup>[3]</sup> X-ray typically gives an idea; however, ultrasonography or computerized tomography may be required for accurate diagnosis.<sup>[7]</sup> Cystoscopic visualization is a precise method to verify the presence of urethral foreign bodies<sup>[3]</sup> In the majority of cases, cystoscopic removal is presumed optimal. Reports on self-inserted and iatrogenic foreign bodies claim that cystoscopic retrieval is possible in approximately 80% of cases<sup>[8]</sup> Open procedure may be performed if cystoscopy or transcutaneous withdrawal

fails to remove the foreign bodies.<sup>[6]</sup> Immediate proper treatment option is recommended to avoid complications.<sup>[5]</sup> The most common complications are urethral damage and associated inflammation, fistula, or stricture.<sup>[1]</sup> A psychiatric evaluation should be recommended to discover any underlying mental health disorders, thus reducing the risk of recurrence.<sup>[2]</sup>

## CONCLUSION

The physician should keep the presence of foreign bodies in mind in patients presenting with frequency, dysuria, hematuria, and obstruction. The presentation of these cases is usually delayed due to the fear of embarrassment. Imaging techniques and palpation are crucial to identify the nature of the foreign body. The best approach for removal of foreign bodies depends directly on their location and nature, patients' age and size, and surgical expertise and available equipment. Most foreign bodies can be retrieved using cystoscopic techniques. Open surgical removal is usually reserved for those in whom cystoscopic techniques or transcutaneous withdrawal are unsuitable or have failed.

## Declaration of patient consent

The authors certify that they have obtained all appropriate patient consent forms. In the form, the patient has given his consent for clinical information to be reported in the journal. The patient understands that their names and initials will not be published and due efforts will be made to conceal their identity, but anonymity cannot be guaranteed.

## Financial support and sponsorship

Nil.

## Conflicts of interest

There are no conflicts of interest.

## REFERENCES

1. Al-Zahrani A, El-Darawani H, Al-Jehani YM, Moghazi K, El-Sadr A. Self-inflicted needle in the urethra retrieved endoscopically from the bladder. *Saudi Med J* 2005;26:2002-3.
2. Prasad Ray R, Ghosh B, Pal DK. Urethral foreign body in an adolescent boy: Report of two rare cases and review of literature. *Int J Adolesc Med Health* 2015;27:463-5.
3. Singh I, Pal AK, Gautam L. Multiple impacted urethral metallic needles and screws (foreign bodies) associated with polyembolokoilamania. *Indian J Surg* 2015;77(Suppl 1):106-8.
4. Zaghbib S, Ouanes Y, Chaker K, Ben Chehida MA, Daly KM, Nouria Y. Urethral self-inserted sewing needle in a 14-year-old boy for autoerotic stimulation. *Urol Case Rep* 2019;25:100894. doi: 10.1016/j.eucr.2019.100894.
5. Park S, Moon KH, Kim SH, Kim DY, Cho YW, Cho SJ, *et al.* Needles as urethral foreign body in a child: Successful removal using a new method with a laparoscopic needle holder. *Urology* 2013;81:188-90.
6. Vahidi S, Karami H, Gholizadeh H. Case report: Removal of a big sewing needle from a boy's urethra from the skin for the first time. *Urol Case Rep* 2021;38:101662. doi: 10.1016/j.eucr.2021.101662.
7. Wang S, Wang J, Xu S, Guo K. Needle urethral self-insertion for nine years in an adolescent boy. *Urol Case Rep* 2021;37:101602. doi: 10.1016/j.eucr.2021.101602.
8. Kong X, Wei C. Clinical features and management of urethral foreign bodies in children: A 10-year retrospective study. *Children (Basel)* 2022;9:1468.