

Brucellar Arthritis Involving Left Sternoclavicular Joint: A Case Report

Senem Sas¹, Hatice Rana Erdem², Burcu Uysal³

¹ Department of Physical Medicine and Rehabilitation, Ahi Evran University Training and Research Hospital, Kirsehir, Turkey

² Department of Physical Medicine and Rehabilitation, School of Medicine, Ahi Evran University, Kirsehir, Turkey

³ Department of Infectious Disease and Clinical Microbiology, Ahi Evran University Training and Research Hospital, Kirsehir, Turkey

Abstract

Brucellosis is a widely spread zoonosis and an important global public health problem, especially in the Mediterranean region. Brucellosis is a systemic infectious disease, and it is transmitted to humans by consumption of raw milk or its by-products as well as by contact with products of infected animals. Clinical findings differ depending on the *Brucella* species, the host, and the duration of illness. The diagnosis of brucellosis is made by positive culture. Since the organism is cultured on blood, the examination is made primarily on the basis of suspicion as well as the high levels of humoral antibody titer. The disease may cause various complications. The most common complications of brucellosis are osteoarticular complications, including arthritis, bursitis, and tendinitis. In this report, brucellar arthritis involving the sternoclavicular joint (STCJ) is presented. In this report we present a rare example of an osteoarticular complication caused by brucellosis.

Keywords: Brucellosis, sternoclavicular joint, osteoarticular complications.

Received: 19.12.2015

Accepted: 24.12.2015

Introduction

Brucellosis is a widely spread zoonosis and an important global public health problem, especially in the Mediterranean region. Brucellosis is a systemic infectious disease, and it is transmitted to humans by consumption of raw milk or its by-products as well as by contact with products of infected animals (1,2).

Brucellosis in humans is characterized mainly by fever. Clinical findings differ depending on the *Brucella* species, the host, and the duration of illness. The disease may cause various complications (1-4). The diagnosis of brucellosis is made by positive culture. Since the organism is cultured on blood, the examination is made primarily on the basis of suspicion as well as the high levels of humoral antibody titer (1,5).

The most common complications of brucellosis are osteoarticular complications, including arthritis, bursitis, and tendinitis. The most severe type of brucellosis is caused by *B. Melitensis* (1). The prevalence of this complication varies from 10% to 80% depending on the *Brucella* species. It was reported that genetic predisposition is linked with HLA-B39 (6).

In this report, brucellar arthritis involving the sternoclavicular joint (STCJ) is presented. It presents a rare example of an osteoarticular complication caused by brucellosis.

Case Report

A 39-year-old woman was admitted to our outpatient clinic of chest diseases with one week long chest pain, swelling, and redness in the left sternoclavicular joint. Cardiac enzymes, troponin, and electrocardiogram (ECG) tests were performed and assessed as a routine procedure. The patient was questioned to determine etiology of chest pain. During the palpation part of the clinical examination, the STCJ was tender over erythema and edema regions. There was no other joint symptoms or clinical findings. The patient reported fever and fatigue. She was asked whether she consumed raw milk or its by-products since brucellar is endemic in Turkey. She reported no consumption of raw milk or its by-products. Hence, STCJ tomography was performed to find the etiology of arthritis. Radiology reported a 2.5 mm hypodense area on the STCJ as seen in Figure 1-2. To determine the soft tissue pathologies, STCJ magnetic resonance (MR) was also performed. The results of the STCJ MR were reported as soft tissue edema and inflammation around the left STCJ. Laboratory values were found as follows: (ESR) 75 mm/h and C-reactive protein 0.6 mg/dl (0-0.5 mg/dl). The patient reported that she suffered from fever and night sweats when the clinical examination repeated one week later. She also mentioned the history of miscarriage of a cow and her contact with its meat. To diagnose brucellosis, the patient was administered the brucellar agglutination test and the result of the test was positive with a value of 1/320.



Correspondence: Senem Şaş, Ahi Evran University Training and Research Hospital, Kirsehir, Turkey.

Conflict of Interest: None

E-mail: senemsas@gmail.com

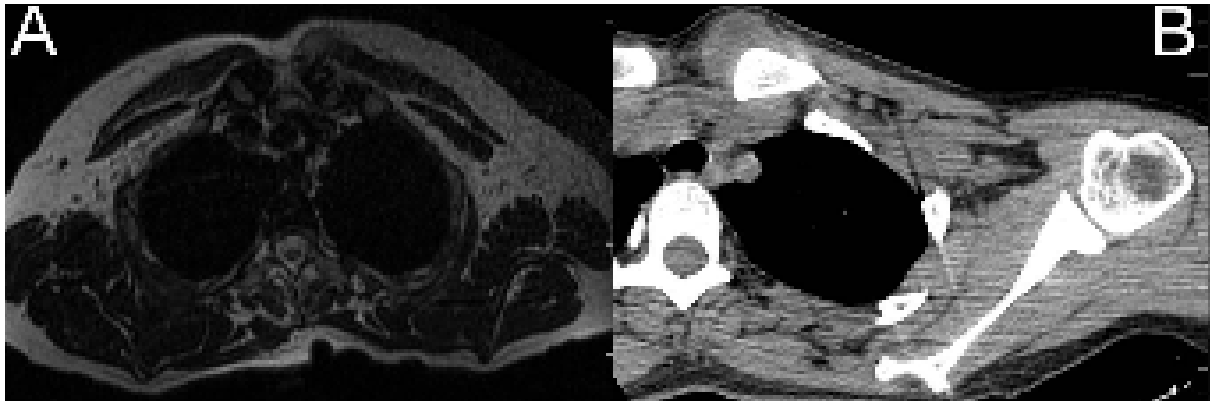
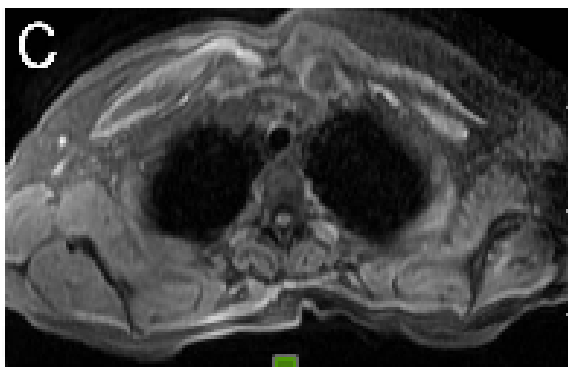

Figure 1. (A,C) Axial T2W image and axial fat saturation T1W image show soft tissue edema and inflammation around left sternoclavicular joint. (B) Soft tissue edema and inflammation around left sternoclavicular joint are seen also axial CT image.



She consulted with the department of infectious diseases. The five weeks treatment involved 900 mg rifampin and 200 mg doxycycline. She was also prescribed ibuprofen 1600 mg daily for two weeks. As a result, rapid recovery of arthritis was observed.

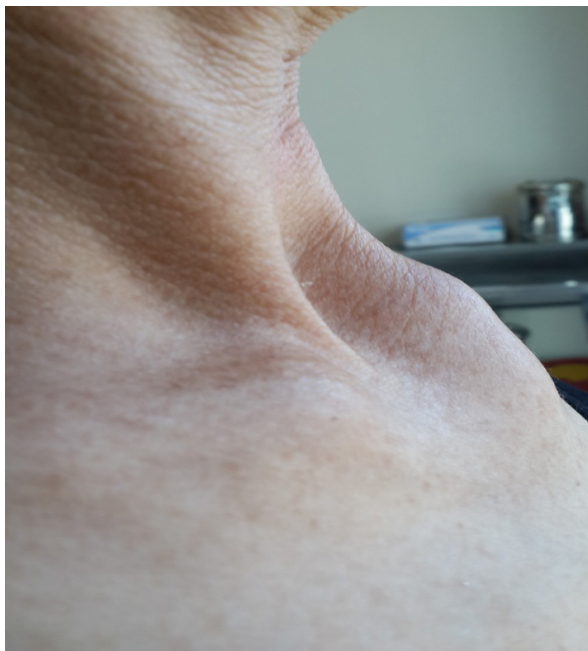

Figure 2. Redness and swelling in sternoclavicular joint.

Discussion

Brucellosis is a zoonosis caused by the species of the genus *Brucella*. Arthritis is commonly presented in the disease. Brucellar arthritis develops by seeding the microorganism or as a reactive arthritis (1,7).

The prevalence of sternoclavicular brucellosis is around 1 case out of every 250 cases of brucellosis or 1 case per 77 cases of osteoarticular brucellosis according to the data reported Mousa et al. (7,8).

Sternoclavicular arthritis is commonly considered to be infectious rather than reactive, and it was reported by Mousa et al. that sternoclavicular arthritis occurs in chronic brucellosis. However, our patient did not have chronic brucellosis.

Sternoclavicular arthritis occurs in 9% of patients of infectious arthritis. The most common microorganisms involved are gram-positive cocci (*Staphylococcus aureus*, hemolytic streptococci, *Streptococcus pneumoniae*) or gram-negative rods, primarily *Pseudomonas*, *Escherichia coli*, *Haemophilus influenzae*, and less commonly *Salmonella* or *Brucella* (9-11).

Adak et al. reported a 28-year old woman with a 4-month history of pain and stiffness in the left temporomandibular and left sternoclavicular joints, and left ankle with brucellosis. They reported oligo arthritis involving the STCJ (12). However, we present a patient with acute monoarthritis on the STCJ. Our patient's disease history was two weeks while the aforementioned patient's disease history was four months. The case presented in this report was diagnosed early because the patient lives in an endemic region for brucellosis.

In a study from Lima covering over a 21-year period, 1729 patients were reported to have been diagnosed with brucellosis. Only seven patients

had sternoclavicular arthritis. Moreover, only five of these seven patients had an acute course with current or past evidence of systemic infection (13).

The Pain in the STCJ may be confused with other articular pathologies, such as cervical spine, shoulder, acromioclavicular articulation, or costochondral arthritis. Furthermore, chest pain from sternoclavicular arthritis imitates cardiac pain, or pulmonary pathologies in addition to tumors (14).

The diagnosis of brucellosis is fairly difficult. The culture of the organism from the joint or bursae helps making a definite diagnosis. Increase in the serum agglutination titer, as well as clinical and

a radiological finding also supports a confident diagnosis (4,5).

Brucella involves the STCJ rarely (8). We considered Tietze's syndrome (costochondritis) for differential diagnosis firstly. However, there was no trauma or occupational predisposition. Moreover, the elevation of acute phase reactants pointed to inflammatory arthritis.

In Summary, most of the patients report the consumption of unpasteurized cheese. On the other hand, there was a history of contact with infected meat in our case. In conclusion, Brucellosis should be considered in patients with sternoclavicular arthritis.

References

1. Young EJ. Brucella species. In: Mandell GL, Bennet JE Dolin R, eds. Principles and Practice of Infectious Disease. Philadelphia, PA: Churchill Livingstone; 2005: 2669-74.
2. Taleski V, Zerva L, Kantardjiev T, Cvetnic Z, Erski-Biljic M, Nikolovski B, et al. An overview of the epidemiology and epizootology of brucellosis in selected countries of Central and Southeast Europe. *Vet Microbiol* 2002;90:147-55.
3. Wernaers P, Handelberg F. Brucellar arthritis of the knee: a case report with delayed diagnosis. *Acta Orthop Belg* 2007;73:795-8.
4. Eales KM, Norton RE, Ketheesan N. Brucellosis in northern Australia. *Am J Trop Med Hyg* 2010;83:876-8
5. Hashemi SH, Keramat F, Ranjbar M, Mamani M, Farzam A, Jamal-Omidi S. Osteoarticular complications of brucellosis in Hamedan, an endemic area in the west of Iran. *Int J Infect Dis* 2007;11:496-500.
6. Bravo MJ, Colmenero JD, Alonso A, Caballero A. HLA-B*39 allele confers susceptibility to osteoarticular complications in human brucellosis. *J Rheumatol* 2003;30: 1051-3.
7. Mousa AR, Muhtaseb SA, Al mudallal DS, Khodeir SM, Marafie AA. Osteoarticular complications of brucellosis: a study of 169 cases. *Rev Infect Dis* 1987;9:531-43.
8. Mousa AM, Muhtaseb SA, Al-Mudallal DS, Marafie AA, Habib FM. Brucellar sternoclavicular arthritis, the forgotten complication. *Ann Trop Med Parasitol* 1988;82:275-81.
9. Womack J. Septic arthritis of the sternoclavicular joint. *J Am Board Fam Med*. 2012;25: 908-91.
10. Belkhir L, Rodriguez-Villalobos H, Vandercam B, Marot JC, Cornu O, Lambert M, et al. Pneumococcal septic arthritis in adults: clinical analysis and review. *Acta Clin Belg* 2014;69:40-6.
11. Ross JJ, Shamsuddin H. Sternoclavicular septic arthritis: review of 180 cases. *Medicine (Baltimore)* 2004;83:139-48
12. Adak B, Tekeoglu I, Kutluhan A, Akdeniz H, Sakarya ME, Ugras S. Brucellar oligoarthritis involving the left temporomandibular, left sternoclavicular and left ankle joints. *Clin Exp Rheumatol* 1997;15:122-3.
13. Berrocal A, Gotuzzo E, Calvo A, Carrillo C, Castañeda O, Alarcón GS. Sternoclavicular brucellar arthritis: a report of 7 cases and a review of the literature. *J Rheumatol* 1993;20:1184-6.
14. Van Tongel A, Karelse A, Berghs B, Van Isacker T, De Wilde L. Diagnostic value of active protraction and retraction for sternoclavicular joint pain. *BMC Musculoskelet Disord* 2014;15:421