

See discussions, stats, and author profiles for this publication at: <https://www.researchgate.net/publication/355356761>

Palmar lipoma causing ulnar neuropathy

Article in *Journal of Turgut Ozal Medical Center* · October 2017

DOI: 10.5455/jtomc.2016.08.095

CITATIONS

0

READS

2

3 authors:



Yakup Ekinci

Kayseri City Training and Research Hospital

34 PUBLICATIONS 51 CITATIONS

[SEE PROFILE](#)



Erdal Uzun

Erciyes Üniversitesi

80 PUBLICATIONS 236 CITATIONS

[SEE PROFILE](#)



Mehmet Yetiş

arya energy

13 PUBLICATIONS 33 CITATIONS

[SEE PROFILE](#)

Some of the authors of this publication are also working on these related projects:



evaluation of risk factors for second hip fractures in elderly patients & effects of hardinge versus moore approach on postoperative outcomes in elderly patients with hip fracture [View project](#)



Pilon fracture radiologic examination [View project](#)

Palmar lipoma causing ulnar neuropathy

Yakup Ekinçi¹, Erdal Uzun², Mehmet Yetis³

¹Develi State Hospital, Orthopedic and Traumatology Clinic, , Kayseri, Turkey

²Kayseri Research and Training Hospital, Orthopedic and Traumatology Clinic, Kayseri, Turkey

³Ahi Evran University Research and Training Hospital Department of Orthopedic and Traumatology, Kırşehir, Turkey

Abstract

Lipomas are the most common benign soft tissue tumors arising from mesenchymal fibroadipose tissue. Often they are observed in the upper limbs, but especially deep palmar hand placement of these tumors is rare and they rarely create symptoms by compressing the surrounding tissue. 52-year-old female patient was admitted to our clinic with palpable stiffness, pain and numbness in his left hand palm. In her history it was learned that she had had an operation because of similar complaints in the same area about 8 months ago in another center. On radiologic examination, about 3 * 4 cm mass was detected surrounding the 5. metacarpal bone in the palmar area. The mass was excised due to clinical findings of neuropathy and ulnar nerve was freed. At follow-up neuropathic symptoms did not encounter and the patient was completely recovered without any complications.

Keywords: Lipoma; Ulnar Neuropathy; Excision..

INTRODUCTION

Lipomas are the most common benign soft tissue tumors (1). Lipomas arise from mesenchymal fibroadipose tissue and are usually circumscribed as superficial, emerge, smooth and painless masses clinically (2,3). Some lipomas may grow significantly and when they get settled in the hand they can be associated with various symptoms. In this report we present a rare deep-seated palmar region lipoma causing ulnar nerve entrapment. Consent form was obtained from the patient.

CASE REPORT

52-year-old female patient was admitted to our clinic with palpable stiffness, pain and numbness in his left hand palm. In her history it was learned that she had had an operation because of similar complaints in the same area about 8 months ago in another center.

On physical examination an old incision scar was observed at palmar side of the same left hand. Deep seated, soft and mobile mass was palpated. Pain and numbness were present in the 4th and 5th finger of left hand consistent with ulnar nerve distribution. There was no pathologic feature on Xray examination.

Received: 29.08.2016

Accepted: 01.09.2016

Corresponding Author

Erdal Uzun

Kayseri Research and Training Hospital, Orthopedic and Traumatology Clinic, Kayseri, Turkey

E-mail: nuzuladre@gmail.com

On ultrasonography (USG) and magnetic resonance imaging (MRI) about 3 * 4 cm was detected in the form of intramuscular homogeneous mass surrounding the 5. metacarpal bone in the palmar area (Figure 1). The symptomatic 3*4 cm mass was excised due to clinical findings of neuropathy and ulnar nerve was freed (Figure 2). At follow-up neuropathic symptoms did not encounter and the patient was completely recovered without any complications.

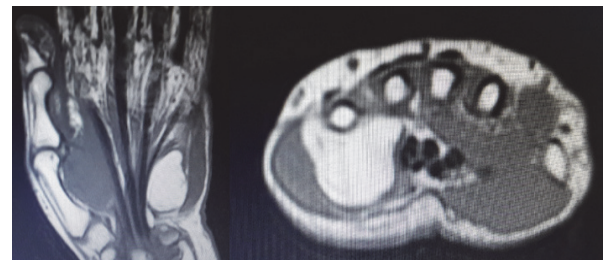


Figure 1. Axial and coronal sections of MRI, showing the palmar mass surrounding metacarpal 5.

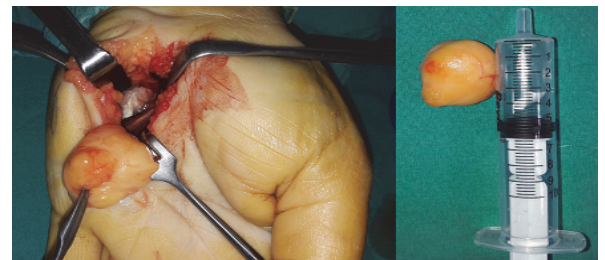


Figure 2. Intraoperative and postoperative image of the excised mass.

DISCUSSION

Bone and soft tissue tumors are frequently encountered pathologies in orthopedic practice. Generally benign tumors are more common than malignant tumors (4). Lipomas in this group are the most common benign soft tissue tumors (1). Especially they are seen as small lesions which don't cause serious complaints (5). Lipomas can occur anywhere in the body which include fat tissue, but despite its obvious fat tissue content lipomas are rare in the hand (2, 6). They can be located in the thenar, hypothenar and intercarpal areas (1). Among the superficial and deep-seated lipomas, the deep-seated ones can cause neurologic findings making pressure over the environmental neurovascular structures when they reached a large size (7). In our case, a hypothenar located lipoma in the palmar area of the hand surrounding the 5th metacarpal bone and compressing the ulnar nerve it caused pain and numbness as ulnar neuropathy symptoms.

Physical examination and USG are usually sufficient in the diagnosis of benign soft tissue tumors, but in the differential diagnosis and treatment of the deep-seated and atypical masses MRI is needed (1). Sensitivity of MRI is about 94% at the diagnosis of lipoma (2).

When the tumors are closely related to the neurovascular structures and tendons, MRI becomes important in the surgical planning and also prevention of complications related to the surgery (8). In our patient, due to prior surgery MRI was used to determine the border of the lesion in detail and evaluate the relationship between soft tissues.

In the differential diagnosis, there are solid masses with smooth border mimicking the lipomas. Biopsy is used in the definitive diagnosis as in all masses.

Basic treatment of lipomas is surgery (9). Asymptomatic cases can be followed, but the basic approach to the lipomas in the hand is excision. Due to the sensitive anatomical structures in the hand, surgery must be done carefully. Partial excisions which are made to protect these structures causes recurrences (10). Although our patient was operated for about 8 months ago and the lesion was benign in nature there became recurrence.

This situation can be probably explained by partial excision of the lesion.

In conclusion, diagnosis and treatment of hand-seated tumors are important. MRI provide guidance in the differential diagnosis of the masses in this area and planning surgery. Surgeons should be very careful due to the sensitive and complex anatomical structure of this area in order to prevent damaging adjacent neurovascular structures and to prevent recurrence in the surgery.

REFERENCES

1. Keçeci B, Öztürk AM, Kaya E, Özdemir O, Coşkunol E. El Yerleşimli lipomatöz tümörlerde eksizyon öncesinde manyetik rezonans görüntülemesi gerekli midir?. *Dirim Tıp Gazetesi* 2009;84(3):84-9.
2. Capelastegui A, Astigarraga E, Fernandez-Canton G, Saralegui I, Larena JA, Merino A. Masses and pseudomasses of the hand and wrist: MR findings in 134 cases. *Skeletal Radiol* 1999;28(9):498-507.
3. Özkan A, Öksüz M, Topkara A. Komresif nöropatiye neden olan palmar dev lipom. *Pam Med J* 2016;9(1):71-3.
4. Çıraklı A, Dabak N, Çıraklı S, Sezgin H, Göçer H, Barış S. Distribution of pediatric bone and soft tissue tumors in the central Black Sea region. *Turk J Pediatr* 2014;56(3):226-31.
5. Bagatur AE, Yalcinkaya M. Unilateral carpal tunnel syndrome caused by an occult palmar lipoma. *Orthopedics* 2009;32(10):43775.
6. Kransdorf MJ. Benign soft tissue tumors in a large referral population: distribution of specific diagnosis by age, sex and location. *AJR Am Roentgenol* 1995;164(2):395-402.
7. Inapathy P, Southgate GW. Giant lipoma of hand: a case report. *Eur J Orthop Surg Traumatol* 2006;16:251-2.
8. Azwa N, Shalimar A, Jamari S. A palmar lipoma with median and ulnar nerve compressive symptoms. *Malaysian Orthopaedic Journal* 2007;1:33-5.
9. Minabe T, Momosawa A, Harii K. Endoscopic and ultrasonic removal of a lipoma on the forehead with no facial scarring: practicality of patient's early return to work. *Scand J Plast Reconstr Surg Hand Surg* 2009;43:22-8.
10. Şimşek T, Söylemez F, Keleş M, Aydın O. A giant lipoma in finger. *J Exp Clin Med* 2010;27:73-6.