



DOI: 10.5137/1019-5149.JTN.16604-15.0

Received: 23.11.2015 / Accepted: 07.12.2015

Published Online: 10.08.2016

Original Investigation

Nerve Tissue Prefabrication Inside the Rat Femoral Bone: Does It Work?

Zuhtu OZBEK¹, Atacan Emre KOÇMAN², Orhan OZATIK³, Erdem SOZTUTAR⁴, Emre OZKARA¹, Aydan KOSE², Ali ARSLANTAS¹, Cengiz CETIN²

¹Eskisehir Osmangazi University, Medical Faculty, Department of Neurosurgery, Eskisehir, Turkey

²Eskisehir Osmangazi University, Medical Faculty, Department of Plastic Surgery, Eskisehir, Turkey

³Ahi Evran University, Medical Faculty, Department of Histology and Embryology, Kırşehir, Turkey

⁴Eskisehir Osmangazi University, Medical Faculty, Department of Anatomy, Eskisehir, Turkey

ABSTRACT

AIM: To investigate whether nerve regeneration can be induced in the tubular bone between distal and proximal cut nerve ends.

MATERIAL and METHODS: Twenty adult Wistar rats were used for the study. Rats were divided into three groups; femoral bone conduit group, nerve transection group, sham group. The sciatic nerve was surgically cut and from both ends inserted into the adjacent femoral bone tunnel in the femoral bone conduit group. The sciatic nerve was cut transversely in the nerve transection group. In the Sham group, only sciatic nerve exploration was performed, without a nerve cut. The groups were evaluated functionally and morphologically.

RESULTS: All results showed that axonal growth existed through the osseous canal.

CONCLUSION: To the best of our knowledge, this is the first study to evaluate neural regeneration inside the bone. We can speculate that the bone marrow provides a convenient microenvironment for peripheral nerve regeneration. In addition to prefabricating peripheral nerves, this novel model may help to establish further strategies for engineering of other tissues in the bone marrow.

KEYWORDS: Bone, Conduit, Sciatic nerve

INTRODUCTION

Recently autologous nerve grafts have become the most essential treatment in defective peripheral nerve injuries. However this method has its inherent drawbacks such as donor site morbidity and shortage of available graft material (13). Efforts have been made to replace autologous nerve grafts with biological or synthetic conduits alternatively. Although empty conduits meet many of the requirements of axonal growth by concentrating trophic factors, reducing fibrotic tissue invasion and providing guided regeneration (2), they do not possess sufficient regenerative capacity for nerve defects due to lack of support and repair cells (9,13,14).

The transplantation of support cells from various sources into the conduits has been proposed as a method to promote peripheral nerve regeneration. Especially cultured Schwann Cells (SCs) from neural origin that play an integral role in regeneration of the peripheral nerves have been implanted into suitable conduits (9,10,16,22). Although SCs transplantation improved nerve regeneration experimentally, its clinical applications remained controversial because of its disadvantages. SCs are difficult to obtain in large amounts which may be attributed to the time-consuming process of isolation, cultivation and expansion of SCs in vitro because of their restricted mitotic activity (12). Another reason may



Corresponding author: Zühtü ÖZBEK

E-mail: zuhtuozbek@gmail.com

be an insufficient biocompatibility of neural conduits with SCs (9). Additionally harvesting autologous SCs requires sacrificing a functioning donor nerve which is another inevitable disadvantage similar to autologous nerve grafting (17,20). In order to promote nerve regeneration in injured peripheral nerves, bone marrow stem cells (BMSCs) can be considered as alternative source of support cells instead of SCs. As demonstrated previously, BMSCs implanted within the conduits can synthesize neurotrophic factors and extracellular matrix elements for peripheral nerve regeneration (2,25). Furthermore it was well documented that BMSCs can differentiate exclusively into SCs *in vivo* (3,6,25) and *in vitro* (7,11,12,16,18,23) and promote axonal regeneration if the appropriate microenvironment or cell culture conditions were constituted.

Establishing the microenvironment is the most important aspect for cell survival (5) which can be best constituted inside the body of the individuals and is more protective than *in vitro* cell cultures. Therefore bone marrow is a suitable microenvironment and also can be defined as an *in vivo* culture medium. While long tubular bones contain bone marrow with undifferentiated BMSC, the purpose of the current study was to employ the tubular bone as a nerve conduit with its native resident cells and natural extracellular matrix (ECM). Thus the present study differs from other nerve regeneration studies which usually combine a given scaffold with ECM and support cells such as those obtained from *in vitro* cultures. Previously the nerve has been utilized to reconstruct a vascularized bone flap (neuroosseous flap) (15). However, the nerve regeneration inside the viable bone has not been tested yet. This study was aimed to investigate whether nerve regeneration can be induced in the tubular bone between the distal and proximal cut nerve ends.

■ MATERIAL and METHODS

Animals

The experimental protocol was approved by the local ethical committee of Osmangazi University. All operations on animals were conducted according to the healthcare guidelines for

the laboratory animals and Universal Declaration on Animal Welfare. The animals were hosted in separate cages with a day and night cycle. Access to free standard rodent food and water was provided for all animals during the experiments. The rats were fasted only 12 hours before the operation without limitation of water.

Twenty adult female Wistar rats weighing 200–250 g were used for the study. Rats were divided in three groups: Group I: Femoral bone conduit group (n=14), Group II: Nerve transection group for negative control (n=3). Group 3: Sham (uncut sciatic nerve) group for positive controls (n=3). The negative and positive controls served only to determine the utility of the immunostaining protocol.

Surgical Procedures

Rats were anesthetized intraperitoneally with sodium pentobarbital (50 mg/kg) during the operations. The right hindlimb of rats were deepilated with creams and surgical field was cleaned up with povidone iodine solution. In the femoral bone conduit group, the sciatic nerve and femoral bone were exposed through a skin and muscle incision. The bone was dissected free further from the surrounding tissue. A semitube 1-cm long and 2-mm wide was created with a high speed drill system using ball-tipped burs on the lateral surface of the femoral bone adjacent to the sciatic nerve (Figure 1A). With the aid of a surgical loupe at x4.5 magnification, the sciatic nerve was cut transversely from the middle. Circumferential noose sutures (5/0 biosyn) were secured to the proximal and distal end of the carved bone. The cut nerve ends were attached to these noose sutures with 8/0 prolene in order to insert both nerve ends into the bony canal (Figure 1B). The final gap between two nerve stumps was measured as approximately 0.7 cm. The open lateral surface of the osseous semitube was covered with a thin silicone sheet (1x0.5 cm) by securing circumferentially with 4/0 prolene looped sutures around the bone to isolate the prefabricated construct from the surrounding tissue (Figure 1C). Therefore the semitube turned into a tube and migration of the soft tissues into the bony canal during the healing period were prevented. Small crescents were excised from the distal and proximal ends of

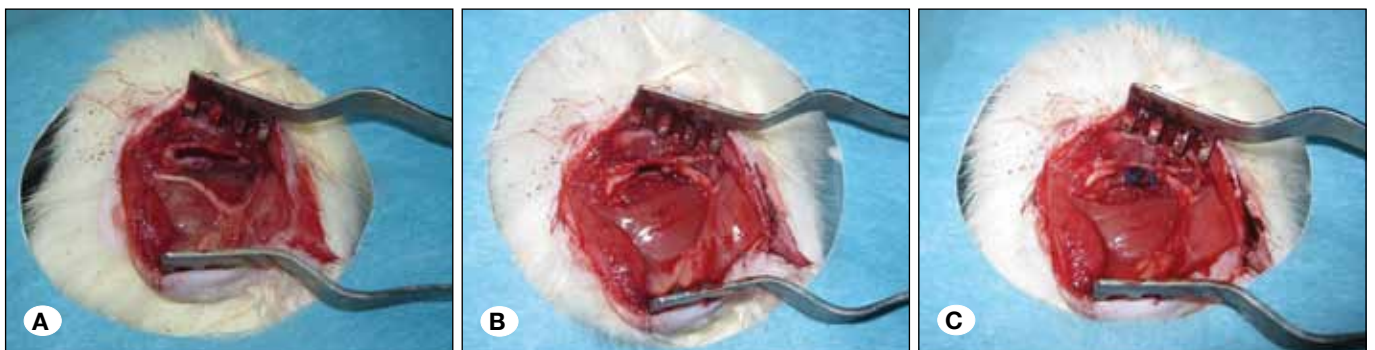

Figure 1: Stages of the surgical procedures. **A)** The sciatic nerve and femoral bone were exposed. The lateral surface of the bone was carved with a drill. **B)** The sciatic nerve was cut from the middle and the proximal and distal stumps were secured to both ends of the canal forming a 0.7 cm gap in between. **C)** A thin silicone sheet was used to cover the open bony canal to prevent the prefabricated structure from invasion of the surrounding tissue.

the secured silicone sheet at the proximal and distal bony entrance sites to prevent the nerve from being constricted. The wound was subsequently closed in layers with 4/0 Vicryl and prolene sutures.

The nerve transection group rats (group II) were prepared for surgery similarly. The sciatic nerve and femoral bone were exposed by the same way. The sciatic nerve was cut transversely from the middle. Proximal and distal stumps were sutured to the muscle tissue adjacent to the femoral bone with 8/0 nylon, creating a gap of approximately 0.7 cm. No conduit was placed between the stumps. Wounds were closed in layers. In the Sham group; only sciatic nerve exploration was performed, without cutting the nerve. Once the surgical procedures were completed, the animals were allowed to recover and to survive for 3 months.

Walking Track Analysis and Sciatic Function Index (SFI)

Walking track analyses were performed on the animals which did not exhibit autocannibalisation and toe loss at the 0th, 4th, 8th, 12th weeks using the stamp and paper method (21). After the measurements of the lengths of the third toe to heel (PL), the first to fifth toe (TS), and the second toe to the fourth toe (IT) on the experimental side (E) and the contralateral normal side (N) in all animals, the sciatic function index (SFI) was calculated by the following formula:

$$\text{SFI} = -38.3 \times (\text{EPL} - \text{NPL}) / \text{NPL} + 109.5 \times (\text{ETS} - \text{NTS}) / \text{NTS} + 13.3 \times (\text{EIT} - \text{NIT}) / \text{NIT} - 8.8$$

SFI scores rank from -100 to 0, which represent total dysfunction and normal nerve function respectively.

Morphological Assessment

Rats were sacrificed after the last walking track analysis at the 12th week with high dose sodium pentobarbital (100 mg/kg) and cardiac blood exsanguination. The right hindlimbs were re-exposed and the formed neural-osseous constructs in group I were harvested en-bloc after careful dissection and osteotomies. Proximal and distals stumps of the transected nerves in group II and normal nerve tissues in group III were also excised. All biopsies were fixed with 10% paraformaldehyde and sent to the associated laboratory for further processing.

Histological Preparation and Morphometric Studies

The prefabricated osseous structures of 10 rat specimens buffered in 10% paraformaldehyde were decalcified with Osteodec® (Bio-Optica, Milano s.p.a, Italy). All tissues were then embedded into the paraffin blocks. Three specimens were sectioned longitudinally. The remaining seven specimens were sectioned horizontally (transversely) at proximal, middle (intraosseous) and distal sites in 5 µm slides. The sections were stained routinely with toluidine blue for light microscopic evaluation. Five random fields at x100 magnification were chosen from the proximal, middle, and distal segments and captured by a digital camera connected to a light microscope (Leica DM3000, Wetzlar, Germany) and a computer. Measurements were made by two blind investigators. Number of axons per 1 mm² were counted, and the axon diameter and myelin sheath thickness were measured on each sample

using an image software program (NeuroLucida software, MBF Bioscience, Williston, VT, USA).

Control nerve tissues (three rat specimens both of transected nerves and normal nerves) were also buffered in 10% paraformaldehyde and processed in the same way except decalcification.

Immunohistochemical Analysis

Unstained sections were further processed for S-100 and Neurofilament (NF) immunohistochemistry. After deparaffinization and rehydration in phosphate-buffered saline (pH 7.4), the nerve sections were incubated with Tris/EDTA buffer (pH 9.0) for 5 minutes and hydrogen peroxide 3% for 10 minutes. Non-specific immunoreactions were blocked with ultra V-Block serum. Sections were then incubated separately in S-100 Protein Ab-1 (Clone 4C4.9, Thermo Scientific, Fremont, CA, USA) or NF protein Ab-1 (Clone 2F11, Thermo Scientific, Fremont, CA, USA) solutions for 1 hour at 24°C temperature. After washing with phosphate-buffered saline solution, they were incubated in biotinylated rabbit IgG solution and HRP (horseradish peroxidase) labeled secondary antibody, each for 1 hour respectively. Finally, the sections were stained with AEC (3-amino-9-ethylcarbazole) chromogene substrate and counterstained with hematoxylin for 10 minutes. Immunohistological sections were also evaluated by two blinded investigators.

Electron Microscopic Studies

Two of the prefabricated structures were cut transversely from the midportion with a high-speed rotator power instrument and disk saw and fixed in 2.5% glutaraldehyde solution. Samples were processed and coated with Gold-Palladium. Images were taken with the scanning electron microscope (SEM) (Jeol 5600, Jeol Inc., Tokyo, Japan).

Statistical Analysis

IBM SPSS version 2.2 (IBM Global Services Limited Company, Istanbul, Turkey) was used for data analysis. The Shapiro-Wilk test of normality was used to assess compliance with the normal distribution of continuous variables in each group. Continuous normally distributed measurements were compared across the groups using One-Way ANOVA with the Tukey method for multiple comparisons. Values were expressed as the mean ± standard deviation (SD). The significance level was set at p < 0.05.

RESULTS

Functional Results

The SFI values of animals with prefabricated nerves were -100.39 ± 6.75 at the 0th week, -100.06 ± 8.03 at the 4th week, -92.03 ± 4.31 at the 8th week and -86.35 ± 5.83 at the 12th week (Figure 2). The SFI values increased gradually over time and the changes were statistically significant between the 4th, 8th and 12th weeks (p < 0.05). Increase in SFI values indicated that proximal and distal stumps of the transected nerve reconnected through the prefabricated femoral bone conduit with axonal sprouting.

Macroscopic Results

In two of prefabricated constructs, no neural tissue in the bone was observed probably due to technical errors such as separation of stumps, inadequate carving of bone, constriction of the nerve etc. However in the other 12 constructs, neural tissue formation was seen obviously in the femoral bone. Two of the constructs were dismoected to reveal neofomed nerves (Figure 3A, B).

Histological and Immunohistological Results

Histological examination in longitudinal sections exhibited regeneration in continuity between proximal and distal nerve stumps through the femoral bone. Neural regeneration through the osseous semitube was evident with all type of stainings. Toluidine blue revealed overall bone and regenerated nerve compatibility (Figure 4A). Expression of S-100 indicated the existence of Schwann-like cells and NF showed axonal

sprouting (Figure 4B, C). Regeneration had weakened in the middle of the conduit but connection between two stumps was already established. In greater magnifications, disorganized fibrous tissue formation was more remarkable than neural regeneration (Figure 5A-C). Misorientation of neural regeneration through bony channels was also seen in histological sections accidentally.

Inspection of the transverse sections presented regenerated axons surrounded by the fibrotic connective tissue in the middle portion of the femoral bone-nerve constructs. Quantitative morphometric analyses showed that the number of axons, axon diameter and myelin sheath thickness decreased from proximal to distal portion and signs of Wallerian degeneration (Table I).

SEM Results

Scanning electron microscopy images of transverse sections of prefabricated constructs confirmed neural regeneration three-dimensionally. It was obvious that bone marrow was separated from the nerve with new bone formation and nerve was attached to the fibrous capsule that formed around the silicone cover (Figure 6).

DISCUSSION

Use of bone as a neural conduit has only historical importance. Gluck, in 1890, has bridged a nerve defect with a conduit made from avascular, decalcified bone with poor functional results (4). Hence the bone was denied to be used as a nerve conduit while autografting remained the gold standard for peripheral nerve repair and many artificial and biological grafts were devised for nerve regeneration until today (4). Indeed the tubular bone is far from an ideal conduit which could not satisfy biological requirements of a neural scaffold such as biodegradability, permeability, biomechanical properties (9). However, the inside of the vascularised bone is biocompatible with its resident BMSCs and ECM and may

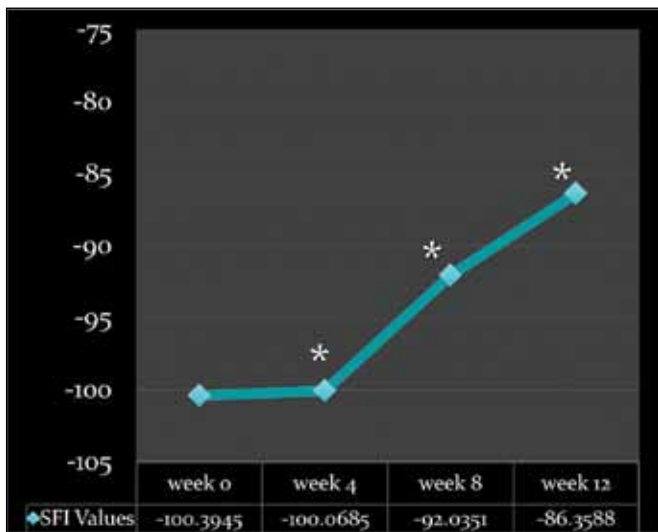


Figure 2: SFI values at 0th, 4th, 8th and 12th weeks (*:p<0.05).

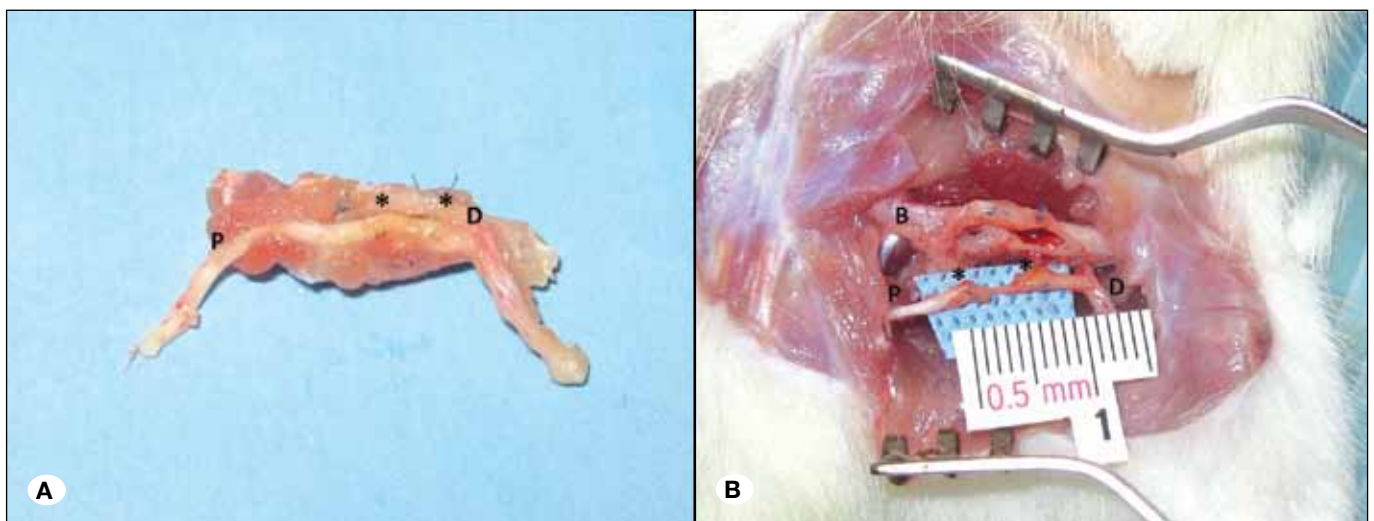


Figure 3: **A)** The prefabricated construct was resected en bloc. **B)** The newly formed part of the nerve (shown between two asterisks*) was dissected from the bony canal. (P: proximal, D: distal, B: Bone).

Table I: Quantitative Morphometric Analyses Showed that the Number of Axons Per mm², Axon Diameter and Myelin Sheath Thickness Decreased from Proximal to Distal Portion

Proximal			Conduit			Distal		
Number of axons (mm ²)	Axon diameter (μm)	Myelin sheath thickness (μm)	Number of axons (mm ²)	Axon diameter (μm)	Myelin sheath thickness (μm)	Number of axons (mm ²)	Axon diameter (μm)	Myelin sheath thickness (μm)
11369±160	2.54±0.36	2.10±0.39	8132±193	1.70±0.25	1.50±0.17	6513±127	1.44±0.10	1.64±0.25

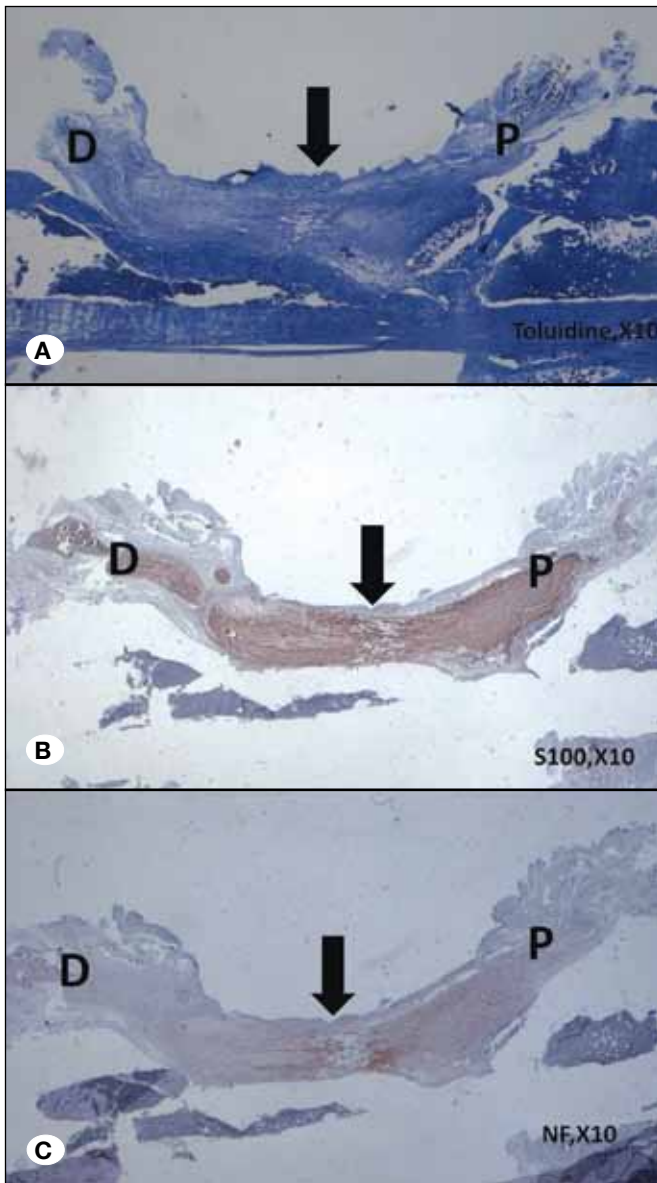


Figure 4: Nerve regeneration from proximal to distal shown in both histological immunohistochemical studies with longitudinal sections **A)** Toluidine blue, x10. **B)** S100, x10. **C)** NF, x10. (P: proximal, D: distal, B: bone, Arrow indicates connection between proximal and distal stumps).

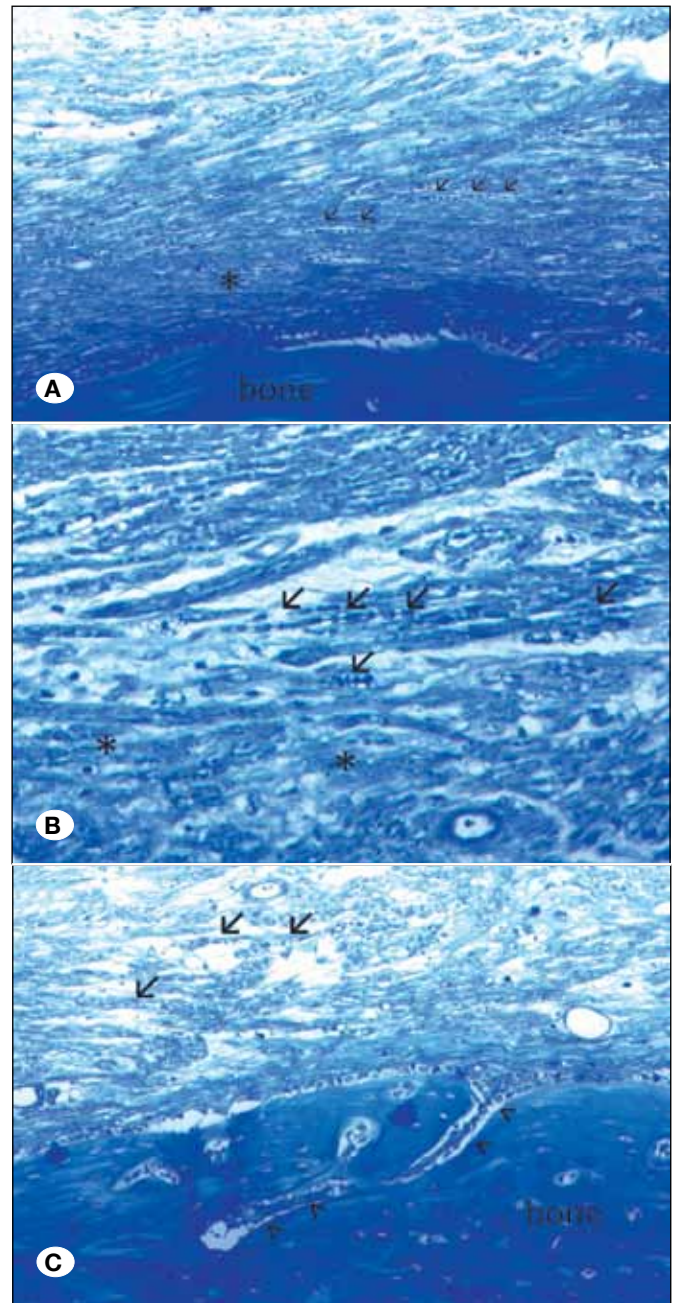


Figure 5: Transverse sections at x20 **(A)** and at x40 **(B, C)** magnifications. Arrows indicate regenerated axons in fibrotic tissue (asterisks*). Arrowhead indicates nerve regeneration into the bone.




Figure 6: Three-dimensional demonstration of neural regeneration in the femoral bone with electron microscopy. (BM: Bone Marrow, B: Bone, N: Nerve, Arrow indicates capsule formation caused by silicon sheet, SEM, x25).

provide a microenvironment for nerve regeneration. BMSCs have pluripotent plasticity to differentiate into different cells including neural cell lineage under convenient conditions (9). Recently, introduction of undifferentiated (2,6,12,20) and transdifferentiated (7,11,16-18) BMSCs into nerve conduits represents a popular approach for peripheral nerve regeneration. It has been demonstrated that BMSCs in the surgical repair of peripheral nerves have improved axonal regeneration and functional recovery. Thus, BMSC transplantation has been proposed as a method for peripheral nerve regeneration. Briefly, bone marrow aspirates were extracted from long bones or flat cortical bones. Then BMSCs were implanted into biological or artificial conduits between nerve defects directly or after expansion and/or differentiation in *in vitro* culture medium (7,9,11,16,18,23).

In the present study, the bone was employed with its resident BMSCs as a compound conduit. While the canal created through the bone acted as a neural tube, BMSCs may play a regulatory role in peripheral nerve regeneration. Actually, the molecular mechanisms responsible for the regenerative effects of BMSCs on peripheral nerve injury are still inconclusive. Two possible mechanisms explaining the potential role of BMSCs on neural regeneration were mainly considered. First BMSCs have been shown to be induced to differentiate into SC-like cells expressing S100 and other neural markers *in vitro* and *in vivo* as mentioned above (7,16-18). However differentiation into SC phenotypes has been found transient (16), associated with less than 5% of BMSCs *in vivo* (6,25) and only 50% of BMSC *in vitro* (17). The second possible mechanism is that BMSCs remained undifferentiated and promote neural regeneration via microenvironmental stabilization, production of neurotrophic factors, and indirect modulation of the cellular behavior of SCs (2,25,27) instead of a true differentiation. The present study implied being unable to determine the fate and the role of resident BMSCs during nerve regeneration

and focused primarily on nerve regeneration in the bone. Expressions of S-100 and NF consequently indicated the evidence of the SCs proliferation and axons inside the bone. Based on findings of the previous studies, we can speculate that resident BMSCs might regulate SC proliferation providing a favorable microenvironment with growth factor production within the bone rather than an actual differentiation into SCs. The number of BMSCs did not seem to be adequate in the prefabricated bone conduit for differentiation, since it is reported that BMSCs are rare in bone marrow and comprise a heterogenous cell population with distinct features of plasticity (19). On the other hand, a small numbers of the resident BMSCs in the femoral bone might differentiate into SCs induced by secretion of various neurotrophic factors with the existence of proximal and distal nerve stumps (25,26,28) and interaction with the ingrowing axons (24) as long as BMSCs are capable of differentiating into SC-like cells *in vivo* (3). The fate of resident BMSCs can be clarified in further investigation with immunolabeling studies.

Evidence of regeneration across the nerve gap occurred in the prefabricated osseous conduits but this does not indicate that the nerve had regenerated adequately. Although SFI values were significantly increased over time, this did not indicate satisfactory functional recovery. In this study, functional tests were conducted to support macroscopic and histologic findings and to demonstrate weak neural conduction through the osseous conduit. Limited recovery of the function may depend on the prolonged route of axonal sprouting and fixation of nerve stumps with tension. In our opinion, if the bone conduit may be enriched with BMSC after *in vitro* expansion for which the bone marrow is the best microenvironment, functional recovery may increase. Further research is mandatory to reveal the biological effect of resident BMSCs in the bone marrow of prefabricated bone conduit on promoting axonal regeneration.

To be honest, clinical indications of using bone as a neural conduit is very rare. It can be used as an alternative approach in defective injuries of the nerve travelling near the long tubular bones for instance sciatic nerve injuries near the femoral bone, or high median nerve injuries along the humeral bone. Alternatively autografts with increased length can be prefabricated by cutting and implanting two ends of a donor sensory nerve (i.e saphenous nerve near the tibia) after an appropriate waiting period. Another indication is prefabricating vascularized and neurotized bone construct for osseous constructions to innervate recipient areas. In mandibular reconstruction, sensate flaps including neural and bony components can be prefabricated to replace mental nerve traversing through the mandibular canal. Constructing the neurotized bone tissue is very important to improve the reparative effect in bone defect in addition to vascularisation (8). Kamburoglu et al. vascularised bone by integrating proximal stump of the nerve (15). In contrast to our study, they did not coapt the distal stump to the bone, so neural regeneration did not occur through the bone. It is clear that the existence of a distal stump promotes potential nerve growth by supplying various neurotrophic factors (1,13,26).

The prominent shortcoming of the present study is lack of an employed control group to compare the efficacy of femoral bone conduit with other methods. Excluding control groups from the study has its inherent reason. The nerve defect was created via cutting the nerve in the middle and suturing it separately to proximal and distal ends of the carved osseous canal instead of removing a piece of nerve as conventionally. Therefore the distance which the regenerated nerve travelled became relatively longer. An autologous graft for the control group would be obtained from isogenic rats, however, sacrifice of extra animals was avoided for ethical reasons. Furthermore we had fixed the nerve ends with some tension to the bone which had a negative impact on nerve healing. This condition cannot be tested in control groups using autografts or other conduits.

The purpose of this study was to evaluate the availability of the long bones as a neural conduit and their impact on the peripheral nerve regeneration. The results showed that axonal growth existed through the osseous canal, but functional recovery was less evident. However, the combination therapy with neurotrophic factors, seed cells etc., might further increase the nerve regeneration inside the bone.

■ CONCLUSION

We demonstrated the peripheral nerve regeneration inside the bone marrow, as it provided a convenient microenvironment. However the role of BMSCs remained speculative. To the best of our knowledge, this is the first study to evaluate the neural regeneration inside the viable bone. We suggest that bone marrow provides a more convenient *in vivo* culture medium than *in vitro* cell cultures. In addition to prefabricating peripheral nerves, this novel model may help to establish further strategies for engineering of other tissues in the bone marrow.

■ REFERENCES

- Bajrović F, Bresjanac M, Sketelj J: Long-term effects of deprivation of cell support in the distal stump on peripheral nerve regeneration. *J Neurosci Res* 39(1):23-30, 1994
- Chen CJ, Ou YC, Liao SL, Chen WY, Chen SY, Wu CW, Wang CC, Wang WY, Huang YS, Hsu SH: Transplantation of bone marrow stromal cells for peripheral nerve repair. *Exp Neurol* 204:443-453, 2007
- Chen X, Wang XD, Chen G, Lin WW, Yao J, Gu XS: Study of *in vivo* differentiation of rat bone marrow stromal cells into schwann cell-like cells. *Microsurgery* 26(2):111-115, 2006
- Colen KL, Choi M, Chiu DT: Nerve grafts and conduits. *Plast Reconstr Surg* 124(6 Suppl):386-394, 2009
- Costa HJ, Ferreira Bento R, Salomone R, Azzi-Nogueira D, Zanatta DB, Paulino Costa M, da Silva CF, Strauss BE, Haddad LA: Mesenchymal bone marrow stem cells within polyglycolic acid tube observed *in vivo* after six weeks enhance facial nerve regeneration. *Brain Res* 13(1510):10-21, 2013
- Cuevas P, Carceller F, Dujovny M, Garcia-Gómez I, Cuevas B, González-Corrochano R, Diaz-González D, Reimers D: Peripheral nerve regeneration by bone marrow stromal cells. *Neurol Res* 24(7):634-638, 2002
- Dezawa M, Takahashi I, Esaki M, Takano M, Sawada H: Sciatic nerve regeneration in rats induced by transplantation of *in vitro* differentiated bone-marrow stromal cells. *Eur J Neurosci* 14(11):1771-1776, 2001
- Fan J, Bi L, Jin D, Wei K, Chen B, Zhang Z, Pei G: Microsurgical techniques used to construct the vascularized and neurotized tissue engineered bone. *Biomed Res Int* 2014: 281872, 2014
- Gu X, Ding F, Yang Y, Liu J: Construction of tissue engineered nerve grafts and their application in peripheral nerve regeneration. *Prog Neurobiol* 93(2):204-230, 2011
- Hadlock TA, Sundback CA, Hunter DA, Vacanti JP, Cheney ML: A new artificial nerve graft containing rolled Schwann cell monolayers. *Microsurgery* 21(3):96-101, 2001
- Hou SY, Zhang HY, Quan DP, Liu XL, Zhu JK: Tissue-engineered peripheral nerve grafting by differentiated bone marrow stromal cells. *Neuroscience* 140(1):101-110, 2006
- Hu J, Zhu QT, Liu XL, Xu YB, Zhu JK: Repair of extended peripheral nerve lesions in rhesus monkeys using acellular allogenic nerve grafts implanted with autologous mesenchymal stem cells. *Exp Neurol* 204(2):658-666, 2007
- Ichihara S, Inada Y, Nakamura T: Artificial nerve tubes and their application for repair of peripheral nerve injury: An update of current concepts. *Injury* 39 Suppl 4:29-39, 2008
- Ijkema-Paassen J, Jansen K, Gramsbergen A, Meek MF: Transection of peripheral nerves, bridging strategies and effect evaluation. *Biomaterials* 25(9):1583-1592, 2004
- Kamburoglu HO, Safak T, Ersoy US, Ocal E, Evrenos MK, Sonmez E, Peksoy I, Atilla P, Nur Cakar A: A new flap design: Prefabricated neuro-osseous flap. *Ann Plast Surg* 70(3):317-323, 2013
- Keilhoff G, Goihl A, Langnase, K, Fansa H, Wolf G: Transdifferentiation of mesenchymal stem cells into Schwann cell-like myelinating cells. *Eur J Cell Biol* 85:11-24, 2006
- Ladak A, Olson J, Tredget EE, Gordon T: Differentiation of mesenchymal stem cells to support peripheral nerve regeneration in a rat model. *Exp Neurol* 228(2):242-252, 2011
- Mimura T, Dezawa M, Kanno H, Sawada H, Yamamoto I: Peripheral nerve regeneration by transplantation of bone marrow stromal cell-derived Schwann cells in adult rats. *J Neurosci* 101:806-812, 2004
- Mohammadi R, Azizi S, Delirez N, Hobbenaghi R, Amini K: Comparison of beneficial effects of undifferentiated cultured bone marrow stromal cells and omental adipose-derived nucleated cell fractions on sciatic nerve regeneration. *Muscle Nerve* 43(2):157-163, 2011
- Mohammadi R, Azizi S, Delirez N, Hobbenaghi R, Amini K, Malekhetabi P: The use of undifferentiated bone marrow stromal cells for sciatic nerve regeneration in rats. *Int J Oral Maxillofac Surg* 41(5):650-656, 2012
- Ozmen S, Ayhan S, Latifoglu O, Siemionow M: Stamp and paper method: A superior technique for the walking track analysis. *Plast Reconstr Surg* 109(5):1760-1761 2002
- Schlosshauer B, Muller E, Schroder B, Planck H, Muller HW: Rat Schwann cells in bioresorbable nerve guides to promote and accelerate axonal regeneration. *Brain Res* 963:321-326, 2003

23. Shimizu S, Kitada M, Ishikawa H, Itokazu Y, Wakao S, Dezawa M: Peripheral nerve regeneration by the in vitro differentiated-human bone marrow stromal cells with Schwann cell property. *Biochem Biophys Res Commun* 359(4):915-920, 2007
24. Siemionow M, Demir Y, Mukherjee AL: Repair of peripheral nerve defects with epineural sheath grafts. *Ann Plast Surg* 65(6):546-554, 2010
25. Wang D, Liu XL, Zhu JK, Jiang L, Hu J, Zhang Y, Yang LM, Wang HG, Yi JH: Bridging small-gap peripheral nerve defects using acellular nerve allograft implanted with autologous bone marrow stromal cells in primates. *Brain Res* 10(1188):44-53, 2008
26. Wang H, Zhang H, Liu M, Wang N: Distal segment extracts of the degenerated rat sciatic nerve induce bone marrow stromal cells to express Schwann cell markers in vitro. *Neurosci Lett* 7(544):89-93, 2013
27. Wang J, Ding F, Gu Y, Liu J, Gu X: Bone marrow mesenchymal stem cells promote cell proliferation and neurotrophic function of Schwann cells in vitro and in vivo. *Brain Res* 25(1262):7-15, 2009
28. Yang J, Wu H, Hu N, Gu X, Ding F: Effects of bone marrow stromal cell-conditioned medium on primary cultures of peripheral nerve tissues and cells. *Neurochem Res* 34(9):1685-1694, 2009