



Granulomatous Mastitis Concurrence with Breast Cancer

Hasan Çalış¹ , Asuman Kilitçi² 

¹Department of General Surgery, Ahi Evran University, Kırşehir, Turkey

²Department of Medical Pathology, Ahi Evran University, Kırşehir, Turkey

ABSTRACT

Idiopathic Granulomatous Mastitis (IGM) is a rare, chronic, non-malignant and non-life-threatening breast disease. IGM may mimic carcinoma of the breast. This case report is about concurrence of chronic granulomatous mastitis with breast cancer. The important aspect of this case is that it is the 4th case where IGM and breast cancer are present concurrently.

Keywords: Granulomatous Mastitis, breast, cancer, carcinoma in situ

Cite this article as: Çalış H, Kilitçi A. Granulomatous Mastitis Concurrence with Breast Cancer. Eur J Breast Health 2018; 14: 58-60.

Introduction

Idiopathic Granulomatous Mastitis (IGM) is a rare, chronic, non-malignant and non-life-threatening breast disease (1). Clinically and radiologically, it mimics carcinoma of the breast. The most common complaints of patients are unilaterally emerging breast pain or painless masses (2, 3). This case highlights the possibility that the concurrence of chronic granulomatous mastitis with breast cancer may be explained just as an adjunct situation or a coincidence and may be the difficulty in distinguishing one from the other.

Case Presentation

A 77-year-old female was admitted to our clinic with complaints of breast pain, accompanied by edema and thickening of the skin at 9 o'clock of the right breast, close to the areola. Initial physical examination revealed axillary lymphadenopathy approximately 2 cm in diameter. The breast ultrasound and mammography studies were performed. The ultrasonography revealed a fibroglandular tissue increase with no distinctive borders and an inflammatory appearance and right axillary 2x2 cm non-reactive lymphadenopathy (Figure 1). Mammography showed amorphous mass, axillary lymphadenopathy and focal asymmetric opacity with calcifications in the retroareolar and outer quadrant of right breast (Figure 2, 3). A core biopsy of the right breast was then done. Microscopic examination displayed chronic inflammation and macrophage, giant histiocyte and epithelioid-like cellular infiltration, with cytologic features suggestive of a granulomatous process (Figure 4). Further histopathological analysis showed an evidence of invasive ductal carcinoma 5 mm in diameter and extensive high grade in situ ductal carcinoma foci (Figure 5, 6). The invasive tumor was estrogen and progesterone receptor negative; e-cadherin and c-erb positive (+++). Also, the following methods were performed on the tissue samples obtained from the patient; alkaline-acid resistance factors for tuberculosis bacteria (AARB) and Lowenstein-Jensen culture, Ehrlich Ziehl-Neelsen (EZN) staining and Periodic acid-Schiff (PAS) staining for the investigation of fungal infections. All culture and stains for infectious organisms remained negative. Later, modified radical mastectomy performed because there were widespread high degree carcinoma in situ foci in the non-tumor areas. 18 axillary lymph nodes were present in the axillary dissection specimen, ductal carcinoma metastasis was reported in 2 lymph node which was 2.3 cm in diameter (Figure 7). No granulomatous structures were observed in the axillary lymph nodes. The patient is being followed in an adjuvant chemotherapy program.

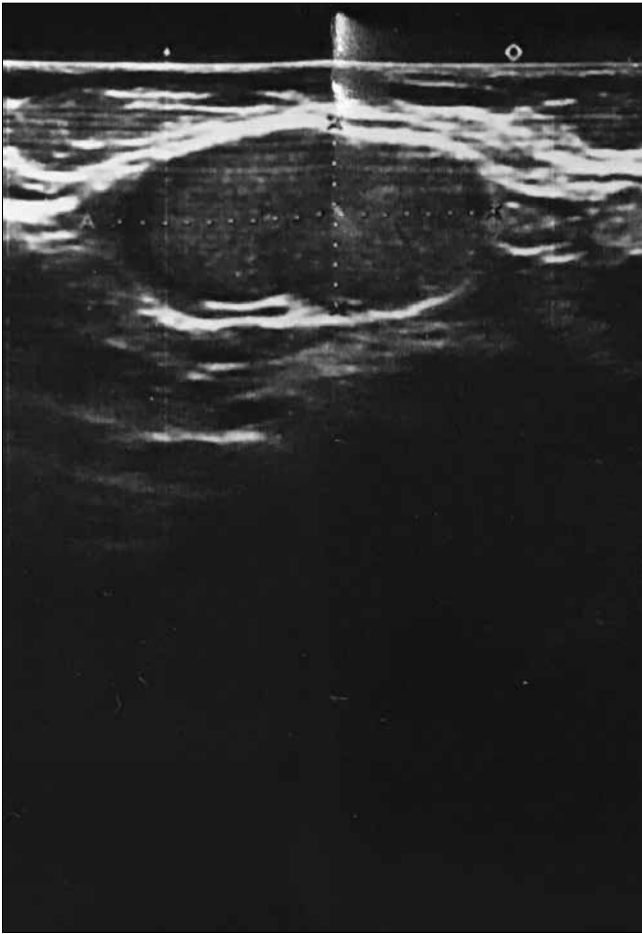

Figure 1. Ultrasonography revealed a fibroglandular tissue increase and axillar lymphadenopathies

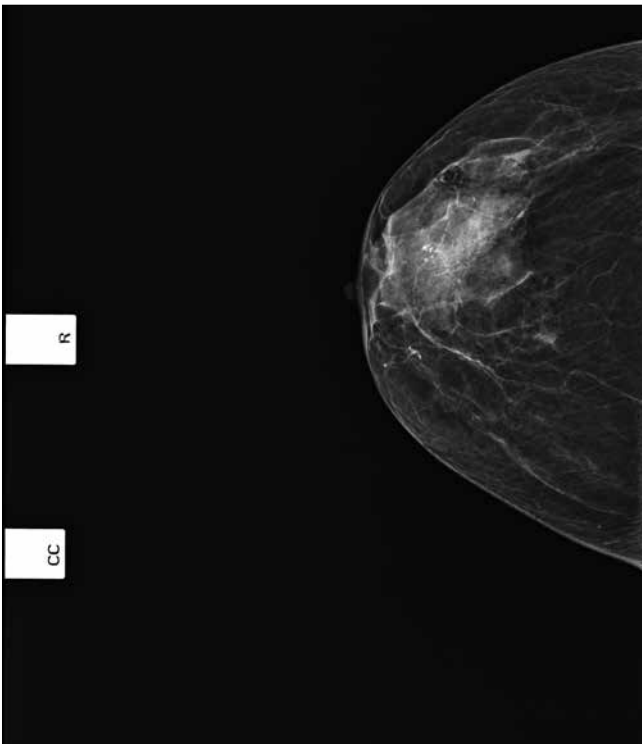


Figure 2. Mammography showed opacity with calcifications in the retroareolar and outer quadrant

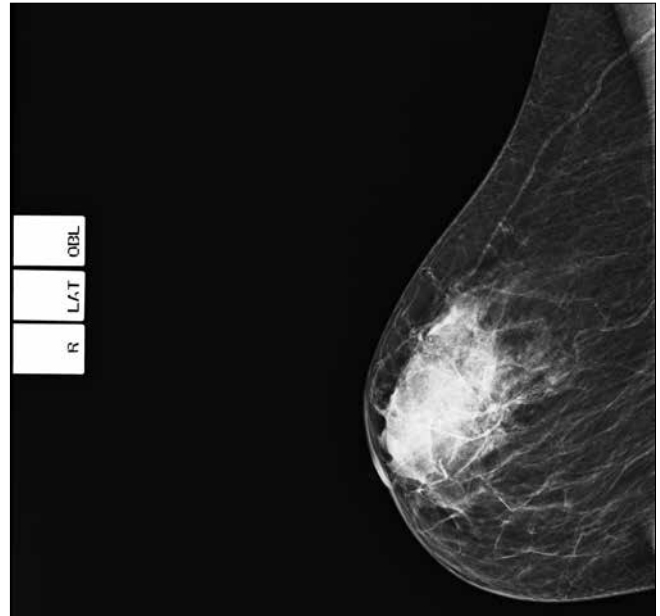


Figure 3. Mammography showed opacity with calcifications in the retroareolar and outer quadrant

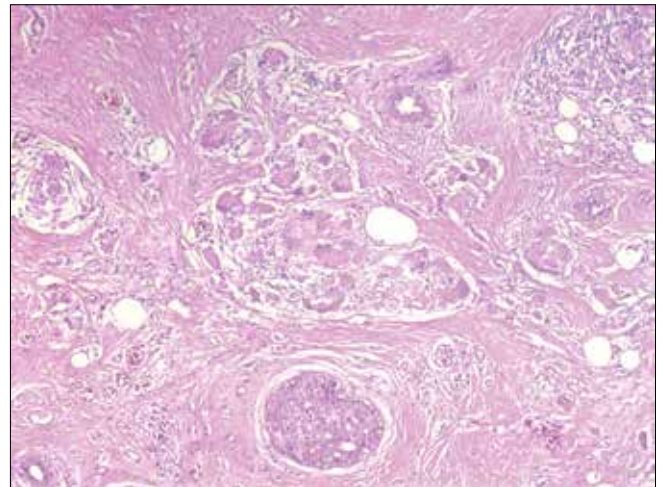


Figure 4. The presence of multinucleated giant cells within non-caseating granulomatous inflammation (H&E, X50)

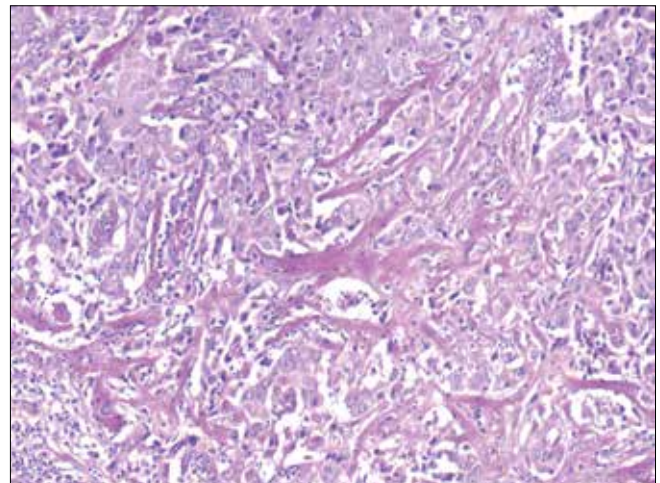


Figure 5. Foci of invasive breast carcinoma and high grade in situ ductal carcinoma (H&E, X100), (H&E, X50)

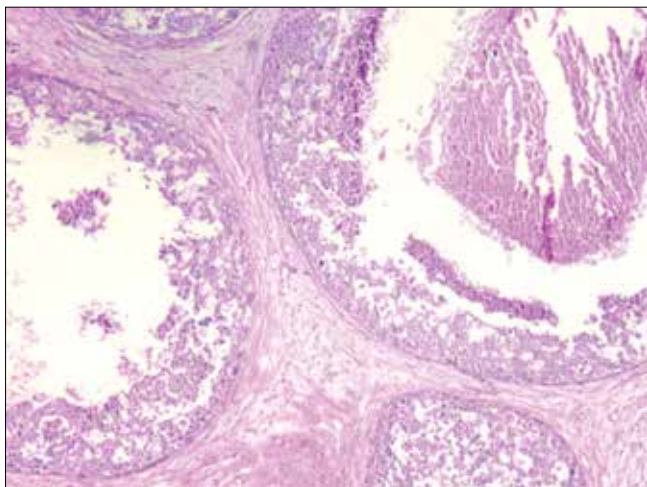


Figure 6. Foci of invasive breast carcinoma and high grade in situ ductal carcinoma (H&E, X100), (H&E, X50)

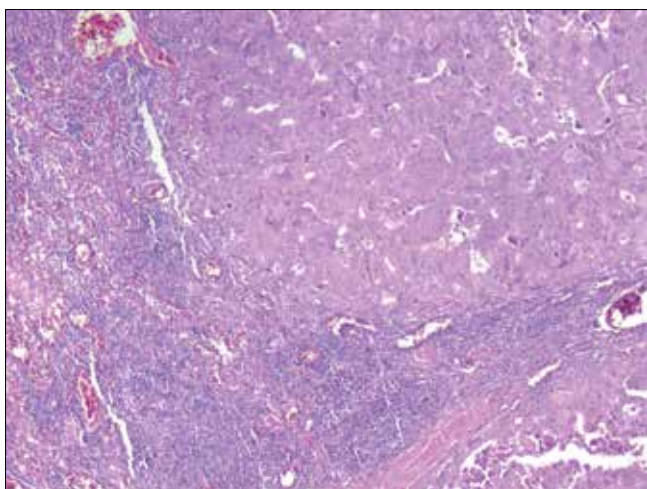


Figure 7. Invasive breast carcinoma metastasis in lymph node (H&E, X50)

Discussion and Conclusion

Idiopathic Granulomatous Mastitis is a non-malignant, chronic, non-life-threatening and rare breast disease (1). The patients visit us mainly due to a mass in one breast. They may consult us due to hyperaemia, sensitivity, areolar retraction, fistula and ulceration complaints in the breast as well (2, 4). The mass may mimic breast cancer by pulling the skin tissue above it, or may penetrate the pectoralis major muscle via nipple retraction and may cause lymphadenopathy. Routine radiologic evaluation, ultrasound and mammography may not discern IGM from breast cancer. Similarly, the probability of MRG discerning the inflammatory process from a tumoral process is very low (4, 5). Our patient's ultrasonographic evaluation revealed a fibroglandular tissue increase with no distinctive borders and an inflammatory appearance and right axillar 2x2 cm metastatic lymphadenopathy. Mammography showed focal asymmetric opacity with calcifications in the retroareolar and outer quadrant of right breast. Inflammatory breast carcinoma and IGM were considered during the pre-diagnosis. The excisional biopsy

result was reported as invasive ductal carcinoma, high grade ductal carcinoma in situ and granulomatous mastitis. Only 3 cases in, which IGM and breast cancer were present concurrently, have been presented in the literature (6-8). The important aspect of this case is that it is the 4th case where IGM and breast cancer are present concurrently.

On the other hand, granulomatous mastitis is usually seen in women during their reproductive or breast feeding period (9). Our patient is 77 years old and that is another important point.

We must be careful in identifying and diagnosing breast cancer in a patient with background history of IGM. Clinical, radiological and pathological investigations have to be performed together for breast cancer developing due to the chronic progresses of IGM or concurrent breast cancer.

Informed Consent: Written informed consent was obtained from patient.

Peer-review: Externally peer-reviewed.

Author Contributions: Concept - H.Ç.; Design - H.Ç., A.K.; Supervision - H.Ç., A.K.; Resources - H.Ç.; Materials - H.Ç., A.K.; Data Collection and/or Processing - H.Ç., A.K.; Analysis and/or Interpretation - H.Ç., A.K.; Literature Search - H.Ç.; Writing Manuscript - H.Ç.; Critical Review - H.Ç., A.K.; Other - H.Ç., A.K.

Conflict of Interest: No conflict of interest was declared by the authors.

Financial Disclosure: The authors declared that this study has received no financial support.

References

1. Kessler E, Wolloch Y. Granulomatous mastitis: A lesion clinically simulating carcinoma. *Am J Clin Pathol* 1972; 58: 642-646. (PMID: 4674439) [\[CrossRef\]](#)
2. Al-Khaffaf B, Knox F, Bundred NJ. Idiopathic granulomatous mastitis: a 25-year experience. *J Am Coll Surg* 2008; 206: 269-273. (PMID: 18222379) [\[CrossRef\]](#)
3. Bani-Hani KE, Yaghan RJ, Matalka II, Shatnawi NJ. Idiopathic granulomatous mastitis: time to avoid unnecessary mastectomies. *Breast J* 2004; 10: 318-322. (PMID: 15239790) [\[CrossRef\]](#)
4. Diesing D, Axt-Flidner R, Hornung D, Weiss JM, Diedrich K, Friedrich M. Granulomatous mastitis. *Arch Gynecol Obstet* 2004; 269: 233-236. (PMID: 15205978) [\[CrossRef\]](#)
5. Sakurai T, Oura S, Tanino H, Yoshimasu T, Kokawa Y, Kinoshita T, Okamura Y. A case of granulomatous mastitis mimicking breast carcinoma. *Breast Cancer* 2002; 9: 265-268. (PMID: 12185341) [\[CrossRef\]](#)
6. Limaïem F, Khadhar A, Hassan F, Bouraoui S, Lahmar A, Mzabi S. Coexistence of lobular granulomatous mastitis and ductal carcinoma: a fortuitous association? *Pathologica* 2013; 105: 357-360. (PMID: 24734318)
7. Handley WS. Chronic Mastitis and breast cancer: a family history of five sisters. *Br Med J* 1938; 7: 113-138. [\[CrossRef\]](#)
8. Mazlan L, Suhaimi SN, Jasmin SJ, Latar NH, Adzman S, Muhammad R. Breast carcinoma occurring from chronic granulomatous mastitis. *Malays J Med Sci* 2012; 19: 82-85. (PMID: 22973142)
9. Ayeva-Derman M, Perrotin F, Lefrancq T, Roy F, Lansac J, Body G. Idiopathic granulomatous mastitis: review of the literature illustrated by 4 cases. *J Gynecol Obstet Biol Reprod (Paris)* 1999; 28: 800-807. (PMID: 10635482)