

See discussions, stats, and author profiles for this publication at: <https://www.researchgate.net/publication/325607922>

# The Effect of Ramadan Fasting on Choroidal and Retinal Thickness Measurements: A Pilot Study Ramazan Orucunun Koroid ve Retina Kalınlığı Üzerine Etkisi: Pilot Çalışma

Article · June 2018

CITATIONS

0

READS

818

10 authors, including:



Ali Kurt

Ahi Evran Üniversitesi

47 PUBLICATIONS 142 CITATIONS

SEE PROFILE



Raşit Kılıç

Gaziosmanpaşa University

62 PUBLICATIONS 145 CITATIONS

SEE PROFILE

Some of the authors of this publication are also working on these related projects:



Exfoliation syndrome [View project](#)



Glaucoma [View project](#)

# The Effect of Ramadan Fasting on Choroidal and Retinal Thickness Measurements: A Pilot Study

## Ramazan Orucunun Koroid ve Retina Kalınlığı Üzerine Etkisi: Pilot Çalışma

Ali KURT<sup>1</sup>, Raşit KILIÇ<sup>1</sup>

### ABSTRACT

**Purpose:** To evaluate the effects of hunger and thirst on peripapillary retinal nerve fiber layer (RNFL) and choroidal thickness (CT) parameters during Ramadan fasting.

**Material and Method:** We included 42 eyes of 21 fasting healthy volunteers in the study. RNFL and CT measurements were obtained using spectral domain optical coherence tomography (SD-OCT). Subfoveal and perifoveal CT were measured using enhanced depth imaging optic coherence tomography. Perifoveal CT was measured at a distance of 500 µm, 1000 µm, and 1500 µm nasally and temporally from the foveal center in each eye.

**Results:** CT was statistically thinner in the fasting state than in the nonfasting state at the subfoveal location ( $C_{SF}$ ) ( $363.61 \pm 72.67$  µm and  $370.88 \pm 74.07$  respectively,  $p < 0.001$ ), at 500 µm temporal to the fovea ( $C_{T500}$ ) ( $352.68 \pm 73.26$  and  $362.85 \pm 74.74$  µm respectively,  $p < 0.001$ ), at 1000 µm temporal to the fovea ( $C_{T1000}$ ) ( $347.71 \pm 73.52$  and  $357.76 \pm 73.43$  µm respectively,  $p < 0.001$ ), at 1500 µm temporal to the fovea ( $C_{T1500}$ ) ( $334.98 \pm 77.45$  and  $344.27 \pm 78.87$  µm respectively,  $p < 0.001$ ), at 500 µm nasal to the fovea ( $C_{N500}$ ) ( $347.71 \pm 72.84$  µm and  $355.95 \pm 70.55$  µm respectively,  $p = 0.001$ ), at 1000 µm nasal to the fovea ( $C_{N1000}$ ) ( $325.71 \pm 77.20$  µm and  $334.02 \pm 75.74$  µm respectively,  $p = 0.003$ ), and at 1500 µm nasal to the fovea ( $C_{N1500}$ ) ( $298.22 \pm 76.79$  µm and  $305.22 \pm 78.24$  µm respectively,  $p = 0.002$ ). There was no statistically significant difference between fasting and nonfasting RNFL thickness.

**Conclusions:** Subfoveal and perifoveal CT values were significantly thinner in fasting than in nonfasting subjects. It is possible that decreased choroidal vascular bed volume during fasting caused the reduction in choroidal thickness.

**Keywords:** Choroidal thickness; enhanced depth imaging; fasting; optical coherence tomography; retinal nerve fiber layer; Ramadan fasting.

### ÖZ

**Amaç:** Ramazan orucu sırasında açlık ve susuzluğun peripapiller retina sinir lifi tabakası (RSLT) ve koroid kalınlığı (KK) üzerine etkisini değerlendirmeyi amaçladık.

**Gereç ve Yöntem:** Çalışmaya 21 oruçlu sağlıklı gönüllünün 42 gözü dahil edildi. Retina sinir lifi tabakası ve KK ölçümleri spectral domain optik koherens tomografi (OKT) kullanılarak yapıldı. Subfoveal ve perifoveal KK ölçümleri artırılmış derin görüntüleme (enhanced depth imaging-EDI) mod OKT ile ölçüldü. Perifoveal KK ölçümleri, herbir gözün fovea merkezinden 500 µm, 1000 µm, ve 1500 µm nazal ve temporal mesafelerde yapıldı.

**Bulgular:** Koroid kalınlığı oruçluken oruçlu değilken ki duruma göre sırasıyla subfoveal ( $363.61 \pm 72.67$  µm ve  $370.88 \pm 74.07$  µm, sırasıyla,  $p < 0.001$ ), fovea merkezinden 500 µm temporalı ( $352.68 \pm 73.26$  µm ve  $362.85 \pm 74.74$  µm, sırasıyla,  $p < 0.001$ ), fovea merkezinden 1000 µm temporalı ( $347.71 \pm 73.52$  µm ve  $357.76 \pm 73.43$  µm, sırasıyla,  $p < 0.001$ ), fovea merkezinden 1500 µm temporalı ( $334.98 \pm 77.45$  µm ve  $344.27 \pm 78.87$  µm, sırasıyla,  $p < 0.001$ ), fovea merkezinden 500 µm nazalı ( $347.71 \pm 72.84$  µm ve  $355.95 \pm 70.55$  µm, sırasıyla,  $p = 0.001$ ), fovea merkezinden 1000 µm nazalı ( $325.71 \pm 77.20$  µm ve  $334.02 \pm 75.74$  µm, sırasıyla  $p = 0.003$ ) ve fovea merkezinden 1500 µm nazal ( $298.22 \pm 76.79$  µm ve  $305.22 \pm 78.24$  µm, sırasıyla  $p = 0.002$ ) lokalizasyonlarda anlamlı derecede daha ince tespit ettik. Oruçluken ve oruçlu değilken ki durum arasında RSLT kalınlığı açısından istatistiki anlamlı fark saptanmadı.

**Sonuç:** Subfoveal ve perifoveal KK değerleri oruçlu bireylerde oruçlu değilken ki durumlarına göre anlamlı derecede daha incedir. Bu durum muhtemelen oruç esnasında koroidal vasküler yataktaki volüm azalmasının KK'nın incelmesine neden olmasındandır.

**Anahtar Kelimeler:** Koroidal kalınlık, artırılmış derin görüntüleme, optik koherens tomografi, retina sinir lifi tabakası, Ramazan orucu.

\* This study was presented as a poster at the XXXIV Congress of the European Society of Cataract and Refractive Surgeons (2016).

\* Bu çalışma, Avrupa Katarakt ve Refraktif Cerrahlar Derneği'nin (2016) XXXIV Kongresinde poster olarak sunulmuştur.

1- Yrd. Doç. Dr., Ahi Evran Üniversitesi Tıp Fakültesi, Göz Kliniği, Kırşehir, Türkiye

Geliş Tarihi - Received: 21.09.2017

Kabul Tarihi - Accepted: 21.10.2017

Ret-Vit 2018; 27: 146-150

Yazışma Adresi / Correspondence Address:

Ali KURT

Ahi Evran Üniversitesi Tıp Fakültesi, Göz Kliniği, Kırşehir, Türkiye

Phone: +90 531 992 8604

E-mail: dralikurt@gmail.com

## INTRODUCTION

Ramadan is the 9<sup>th</sup> month of the Lunar (354 days) calendar and therefore takes place 11 days earlier every year, to coincide with any of the four seasons. Muslims refrain from eating and drinking from dawn to dusk, i.e. for 12-17 h each day, during this months.<sup>1</sup>

Evaluation of the peripapillary retinal nerve fiber layer (RNFL) and choroid thickness (CT) using spectral-domain (SD) optical coherence tomography (OCT) has recently been reported to provide valuable information. Changes in the RNFL and CT have been found to be associated with the pathogenesis in various ocular and systemic disorders.<sup>2-8</sup>

The CT can be influenced by caffeine consumption, spending time at high altitude, and the menstrual cycle in healthy individuals while smoking can affect both CT and RNFL thickness.<sup>9-13</sup>

The aim of our study was to evaluate the effects of hunger and thirst on RNFL thickness and CT during Ramadan fasting. As far as we are aware, this is the first study to evaluate the effect of an approximately 16-hour period without food or drink on RNFL thickness and CT.

## MATERIAL AND METHOD

We compared the RNFL and CT values of fasting and nonfasting healthy subjects. The cross-sectional study was conducted at the Ophthalmology Department of Ahi Evran University Training and Research Hospital on 42 eyes of 21 healthy volunteers. RNFL thickness and CT were evaluated on a random day between the 1<sup>st</sup> and 3<sup>rd</sup> weeks of Ramadan. Written consent was obtained from all subjects after they were informed about the study. The study was conducted according to the principles of the Helsinki Declaration. Enhanced depth imaging (EDI) OCT (Heidelberg

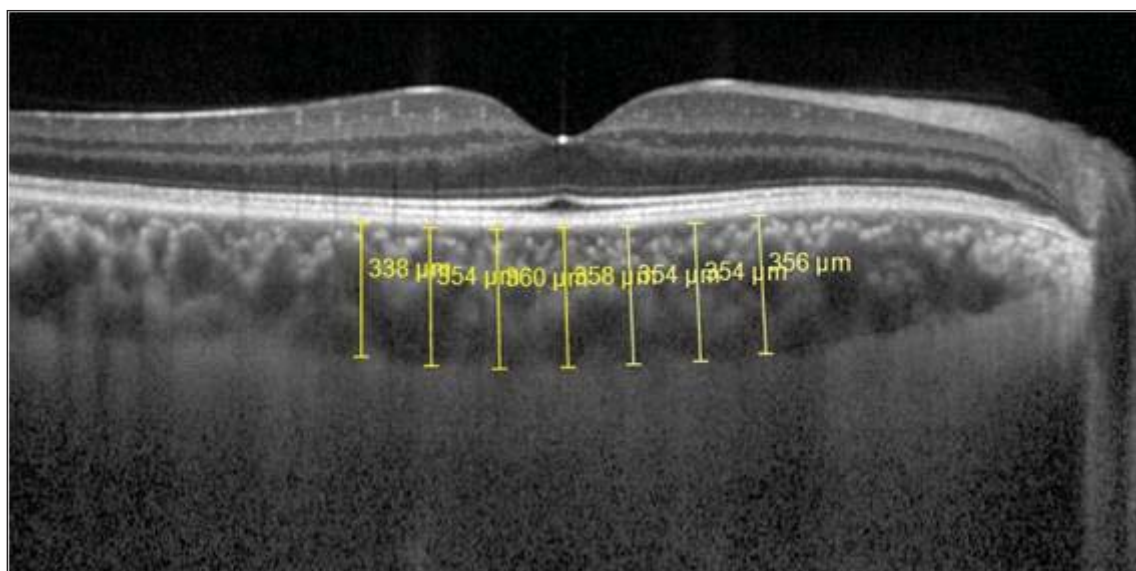
Engineering, Heidelberg, Germany) was used at the foveal center and at 500  $\mu\text{m}$ , 1000  $\mu\text{m}$ , and 1500  $\mu\text{m}$  away from the foveal center temporally and nasally in each eye. CT was measured using the EDI-OCT data from subfoveal horizontal sections by the first ophthalmologist (AK) in all subjects and the second ophthalmologist (RK) controlled the reliability of the measurements.

The measurements were obtained at 3 PM to eliminate the diurnal RNFL thickness and CT fluctuation.<sup>2,14</sup> The choroidal depth was manually measured as the distance between the outer reflective retinal pigment epithelium (RPE) layer and the inner sclera border (Figure 1).

The peripapillary RNFL thickness was automatically segmented using the Spectralis software, version 6.3.3.0.

All patients underwent a full ophthalmological examination including best-corrected visual acuity (BCVA) with the Snellen chart, intraocular pressure measurement with Goldmann applanation tonometry, biomicroscopy and dilated fundus examination. Axial length (AXL) measurements were carried out using optical low coherence reflectometry (Lenstar LS 900, Haag-Streit AG, Koenig, Switzerland). Only patients with a BCVA of 20/20 were included in the study. We also determined and recorded the weight of all subjects while fasting and a month after the end of Ramadan.

Exclusion criteria were a spherical equivalent value greater than  $\pm 1.0$  D, a history of ocular surgery, ocular trauma, anterior or posterior segment disease, smoking and alcohol use, current hemodialysis, migraine, pregnancy, systemic disorders such as hypertension and diabetes mellitus, and using any ocular drug or systemic medication. These factors were considered to influence the choroid and/or peripapillary RNFL thickness.<sup>2,6-7,9,11</sup>



**Figure 1.** Manual measurement of choroidal thickness in an EDI-OCT image.

### OCT Scan Protocol

The EDI-OCT procedure we used has previously been described by Spaide.<sup>15</sup> A Heidelberg SD-OCT device (Heidelberg Engineering, Heidelberg, Germany) with software version 6.3.3.0 was used. The device has a superluminescent diode with a wavelength of 870 nm and can obtain 40,000 A-scans per second with axial and transverse resolutions of 7 and 14  $\mu\text{m}$  respectively. A foveal area  $1 \times 30$  degrees in size was used to obtain two high-quality horizontal line scans through the fovea, averaging 100 scans per section. The signal-to-noise ratio was maximized with the automatic real-time averaging mode to ensure high-quality images. The CT measurements were then obtained from these images by manually measuring choroidal depth (the distance between the outer reflective RPE layer and the inner sclera border). The sections were measured horizontally across the fovea at 500- $\mu\text{m}$  intervals using the digital calipers provided by the Heidelberg Spectralis software up to measurement points 1500  $\mu\text{m}$  temporal and 1500  $\mu\text{m}$  nasal to the fovea (Figure 1).

A total of 100 averaged consecutive circular B-scans (diameter of 3.5 mm, 768 A-scans) was used to measure RNFL thickness. RNFL thickness was measured around the disc while eye movement was compensated for using an online tracking system. The Spectralis software version 6.3.3.0 automatically segmented the RNFL thickness (from the inner margin of the internal limiting membrane to the outer margin of the RNFL layer), providing a global average (G) and the average thickness for each of the 6 sectors: temporal (T), temporal-superior (TS), temporal-inferior (TI), nasal (N), nasal-superior (NS), and nasal-inferior (NI) (Figure 2).

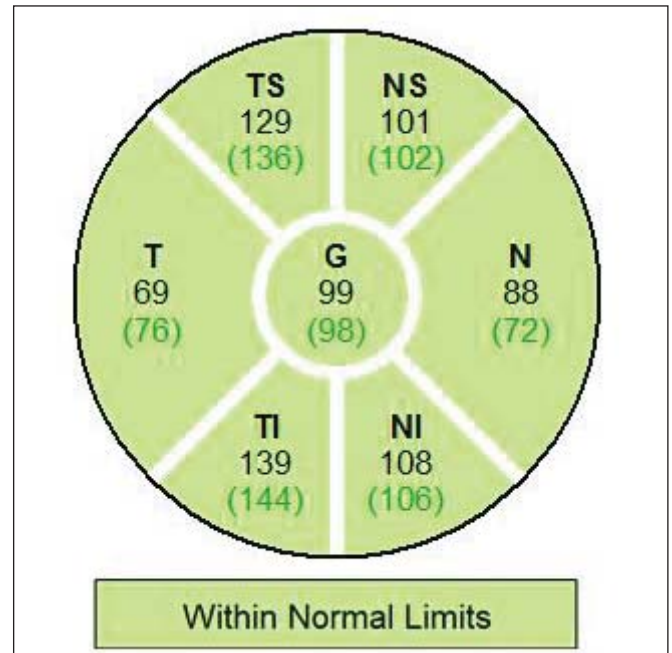
RNFL thickness and CT values of the fasting subjects were recorded and then repeated a month later from the same points using the set references mode.

### Statistical Analysis

Continuous variables were expressed as mean  $\pm$  standard deviation (SD). Normal distribution of the values was verified with the Kolmogorov-Smirnov test before statistical analysis. The Paired t test was used for parametric values and the Wilcoxon test for non-parametric values. A p value  $< 0.05$  was considered statistically significant.

### RESULTS

The 21 healthy individuals consisted of 12 (57.14%) males and 9 (42.86%) females, with a mean age of  $35.15 \pm 3.92$  (26-40) years. There was no statistically significant difference between the weights during fasting and a month after the end of Ramadan with values of  $61.58 \pm 6.91$  (52-72.60) kg and  $61.32 \pm 6.82$  (52.10-72.80) kg respectively ( $p=0.316$ ). Mean AXL measurements during fasting and one month



**Figure 2.** Sample retinal nerve fiber layer scan produced by the Spectralis device. The retinal nerve fiber layer thickness in microns is represented by the numbers under the name of each sector while the mean thickness obtained from adult subjects in Spectralis' normative database are provided in parentheses.

after Ramadan were  $23.95 \pm 0.89$  mm and  $23.95 \pm 0.90$  mm respectively. This difference was also not found as statistically significant ( $p=0.443$ ). The CT was statistically thinner in the fasting state than the nonfasting state at the subfoveal location ( $C_{SF}$ ) ( $p<0.001$ ),  $C_{T500}$  ( $p<0.001$ ),  $C_{T1000}$  ( $p<0.001$ ),  $C_{T1500}$  ( $p<0.001$ ),  $C_{N500}$  ( $p=0.001$ ),  $C_{N1000}$  ( $p=0.003$ ), and  $C_{N1500}$  ( $p=0.002$ ). There was no statistically significant difference between the RNFL thickness values in the fasting and nonfasting state (Table 1).

### DISCUSSION

Ramadan fasting may alter a variety of physiological parameters which themselves influence the ocular system.<sup>1,16</sup> Some previous studies have reported mostly anterior segment changes in healthy individuals during fasting but there are only a few studies on posterior segment changes.<sup>1</sup> A study found significantly increased anterior chamber depth during fasting compared with baseline measurements with the values returning to baseline a month after Ramadan.<sup>17</sup> Axial length was reported to be significantly decreased during fasting, again returning to baseline values a month after Ramadan.<sup>17,18</sup> In the present study, however, there was no significant difference between fasting and nonfasting groups according to AXL measurements. The corneal thickness presented a diurnal variation with smaller values

<b>Table 1. RNFL and CT values of the subjects</b>			
<b>Location</b>	<b>In Fasting State n=42</b>	<b>Nonfasting State n=42</b>	<b>P value</b>
<b>G (min-max) <math>\mu\text{m}</math></b>	101.90 $\pm$ 10.88 (85-126)	101.37 $\pm$ 10.48 (84-124)	0.097
<b>TS (min-max) <math>\mu\text{m}</math></b>	142.95 $\pm$ 20.77 (107-186)	141.76 $\pm$ 19.67 (110-185)	0.083
<b>NS (min-max) <math>\mu\text{m}</math></b>	115.59 $\pm$ 23.14 (79-168)	115.12 $\pm$ 22.72 (80-171)	0.301
<b>TI (min-max) <math>\mu\text{m}</math></b>	152.12 $\pm$ 17.79 (115-200)	151.80 $\pm$ 18.41 (116-119)	0.589
<b>NI (min-max) <math>\mu\text{m}</math></b>	119.05 $\pm$ 26.21 (70-178)	119.27 $\pm$ 23.83 (79-169)	0.855
<b>T (min-max) <math>\mu\text{m}</math></b>	73.88 $\pm$ 10.64 (58-101)	73.85 $\pm$ 11.06 (58-104)	0.937
<b>N (min-max) <math>\mu\text{m}</math></b>	71.98 $\pm$ 11.81 (54-109)	71.56 $\pm$ 10.71 (51-107)	0.281
<b>CSF (min-max) <math>\mu\text{m}</math></b>	363.61 $\pm$ 72.67 (231-488)	370.88 $\pm$ 74.07 (228-498)	<b>&lt;0.001*</b>
<b>CT500 (min-max) <math>\mu\text{m}</math></b>	352.68 $\pm$ 73.26 (202-4919)	362.85 $\pm$ 74.74 (223-496)	<b>&lt;0.001*</b>
<b>CT1000 (min-max) <math>\mu\text{m}</math></b>	347.71 $\pm$ 73.52 (172-492)	357.76 $\pm$ 73.43 (182-493)	<b>&lt;0.001*</b>
<b>CT1500 (min-max) <math>\mu\text{m}</math></b>	334.98 $\pm$ 77.45 (146-489)	344.27 $\pm$ 78.87 (142-494)	<b>&lt;0.001*</b>
<b>CN500 (min-max) <math>\mu\text{m}</math></b>	347.71 $\pm$ 72.84 (219-494)	355.95 $\pm$ 70.55 (220-488)	<b>&lt;0.001*</b>
<b>CN1000 (min-max) <math>\mu\text{m}</math></b>	325.71 $\pm$ 77.20 (197-494)	334.02 $\pm$ 75.74 (203-478)	<b>0.003*</b>
<b>CN1500 (min-max) <math>\mu\text{m}</math></b>	298.22 $\pm$ 76.79 (185-444)	305.22 $\pm$ 78.24 (187-447)	<b>0.002*</b>

G, global average RNFL thickness; T, temporal RNFL thickness; TS, temporal-superior RNFL thickness; TI, temporal-inferior RNFL thickness; N, nasal RNFL thickness, NS, nasal-superior RNFL thickness, NI, nasal-inferior RNFL thickness; CSF, subfoveal choroidal thickness; CT<sub>500</sub>, choroidal thickness at 500  $\mu\text{m}$  temporal to the fovea; CT<sub>1000</sub>, choroidal thickness at 1000  $\mu\text{m}$  temporal to the fovea; CT<sub>1500</sub>, choroidal thickness at 1500  $\mu\text{m}$  temporal to the fovea; CN<sub>500</sub>, choroidal thickness at 500  $\mu\text{m}$  nasal to the fovea; CN<sub>1000</sub>, choroidal thickness at 1000  $\mu\text{m}$  nasal to the fovea; CN<sub>1500</sub>, choroidal thickness at 1500  $\mu\text{m}$  nasal to the fovea; n, number of eyes.

in the evening and no significant difference between the fasting and control periods. However, the major differences were observed in anterior chamber depth and IOP with a shallower anterior chamber and larger diurnal IOP difference in the evening during the fasting period than the control period, both statistically significant.<sup>18</sup>

Fasting for more than 12 hours during Ramadan makes it possible to investigate the posterior chamber response to hunger and thirst. Inan et al.<sup>19</sup> used color Doppler ultrasound imaging to study the effects of dehydration and fasting on the blood velocity recordings from the orbital vasculature and reported that the peak systolic velocity in the ophthalmic artery ( $48.90 \pm 14.66$  vs.  $58.28 \pm 14.65$  cm/s), central retinal artery ( $16.88 \pm 4.30$  vs.  $24.24 \pm 6.45$  cm/s), and temporal

short posterior ciliary artery ( $23.42 \pm 6.19$  vs.  $26.68 \pm 7.52$  cm/s) was higher in nonfasting than in fasting healthy subjects. The peak diastolic velocity of the central retinal artery ( $6.69 \pm 2.15$  vs.  $9.32 \pm 3.08$  cm/s) was also higher in nonfasting subjects.

We found statistically significantly lower subfoveal and perifoveal CT values in the fasting state. We speculate that the choroidal circulation and flow control are the same as for the systemic circulation and that decreased choroidal vascular bed volume while fasting would therefore decrease the choroidal thickness. The changes in CT during fasting were significant while those in RNFL thickness were not, possibly because of the autoregulation system in the retina, which is not as highly vascularized as the choroid.

Mansouri et al.<sup>20</sup> had 28 healthy subjects drink 1000 ml of water in 5 minutes (the water-drinking test) and then measured the CT at the macula and optic disc 15, 30, 45 and 120 minutes later using swept-source OCT. They found a maximum peripapillary and macular CT increase of 5.7% and 4.3% respectively.

The choroid thickness decreased but RNFL measurements did not show a significant change after hemodialysis in another study and this was explained with the decreased body weight due to the removal of fluid<sup>21</sup> They believed that the change in CT without a significant change in RNFL thickness following hemodialysis was due to the fact that the choroid is highly vascularized but the subjects in the study also suffered from systemic disorders such as diabetes. Similarly, another study reported significant choroidal thinning in non-diabetic end stage chronic renal failure patients on hemodialysis with a high ultrafiltration volume.<sup>22</sup>

In conclusion, subfoveal and perifoveal CT values were significantly lower in the fasting than the nonfasting state. As far as we are aware, there has been no previous report of choroidal thickness alterations in healthy subjects undergoing religious fasting. Further studies are needed to determine the effects of conditions that affect vascular volume (such as fasting) on ocular disorders affecting the choroid such as age-related macular degeneration and polypoidal choroidal vasculopathy.

#### Declaration of interest

This study was allowed by Ahi Evran Ahi Evran University Medical School Training and Research Hospital. None of the authors have relevant financial interests, activities, relationships, and affiliations as well as declarations of no conflicts of interest.

#### REFERENCES / KAYNAKLAR

- Javadi MA, Assadi M, Einollahi B, Rabei HM, Afarid M, Assadi M. The effects of Ramadan fasting on the health and function of the eye. *J Res Med Sci.* 2014;19(8):786-91.
- Laviers H, Zambarakji H. Enhanced depth imaging-OCT of the choroid: a review of the current literature. *Graefes Arch Clin Exp Ophthalmol.* 2014; 252(12):1871-83.
- Bussell II, Wollstein G, Schuman JS. OCT for glaucoma diagnosis, screening and detection of glaucoma progression. *Br J Ophthalmol.* 2014;98(2):15-9.
- Tetikoglu M, Temizturk F, Sagdik HM, Aktas S, Ozcura F, Ozkan Y, et al. Evaluation of the Choroid, Fovea, and Retinal Nerve Fiber Layer in Patients with Rheumatoid Arthritis. *Ocul Immunol Inflamm.* 2015; 30:1-5.
- Mehraban A, Samimi SM, Entezari M, Seifi MH, Nazari M, Yaseri M. Peripapillary retinal nerve fiber layer thickness in bipolar disorder. *Graefes Arch Clin Exp Ophthalmol.* 2016;254(2):365-71.
- Nalcacioglu-Yuksekkaya P, Sen E, Yilmaz S, Elgin U, Gunaydin S, Aycan Z. Decreased retinal nerve fiber layer thickness in patients with congenital isolated growth hormone deficiency. *Eur J Ophthalmol.* 2014;24(6):873-8.
- Martinez A, Proupim N, Sanchez M. Retinal nerve fibre layer thickness measurements using optical coherence tomography in migraine patients. *Br J Ophthalmol.* 2008;92(8):1069-75.
- Salobrar-Garcia E, Hoyas I, Leal M, de Hoz R, Rojas B, Ramirez AI, et al. Analysis of Retinal Peripapillary Segmentation in Early Alzheimer's Disease Patients. *Biomed Res Int.* 2015;2015:636548.
- Dervişoğulları MS, Totan Y, Yüce A, Kulak AE. Acute effects of caffeine on choroidal thickness and ocular pulse amplitude. *Cutan Ocul Toxicol.* 2015;10:1-6.
- Fischer MD, Schatz A, Seitz IP, Schommer K, Bartz-Schmidt KU, Gekeler F, et al. Reversible Increase of Central Choroidal Thickness During High-Altitude Exposure. *Invest Ophthalmol Vis Sci.* 2015;56(8):4499-503.
- Sizmaz S, Küçükerdönmez C, Pinarci EY, Karalezli A, Canan H, Yilmaz G. The effect of smoking on choroidal thickness measured by optical coherence tomography. *Br J Ophthalmol.* 2013;97(5):601-4.
- Ulaş F, Doğan U, Duran B, Keleş A, Ağca S, Celebi S. Choroidal thickness changes during the menstrual cycle. *Curr Eye Res.* 2013;38(11):1172-81.
- Dervişoğulları MS, Totan Y, Tenlik A, Yüce A, Güler E. Effect of smoking on retina nerve fiber layer and ganglion cell-inner plexiform layer complex. *Cutan Ocul Toxicol.* 2015;34(4):282-5.
- Ashraf H, Nowroozzadeh MH. Diurnal variation of retinal thickness in healthy subjects. *Optom Vis Sci.* 2014;91(6):615-23.
- Spaide RF, Koizumi H, Pozzoni MC. Enhanced depth imaging spectral-domain optical coherence tomography. *Am J Ophthalmol.* 2008;146(4):496-500.
- Emami-Naini A, Roomizadeh P, Baradaran A, Abedini A, Abtahi M. Ramadan fasting and patients with renal diseases: A mini review of the literature. *J Res Med Sci.* 2013;18(8):711-6.
- Nowroozzadeh MH, Mirhosseini A, Meshkibaf MH, Roshannejad J. Effect of Ramadan fasting in tropical summer months on ocular refractive and biometric characteristics. *Clin Exp Optom.* 2012;95(2):173-6.
- Baser G, Cengiz H, Uyar M, Seker Un E. Diurnal Alterations of Refraction, Anterior Segment Biometrics, and Intraocular Pressure in Long-Time Dehydration due to Religious Fasting. *Semin Ophthalmol.* 2015;21:1-6.
- Inan UU, Yücel A, Ermis SS, Oztürk F. The effect of dehydration and fasting on ocular blood flow. *J Glaucoma.* 2002;11(5):411-5.
- Mansouri K, Medeiros FA, Marchase N, Tatham AJ, Auerbach D, Weinreb RN. Assessment of choroidal thickness and volume during the water drinking test by swept-source optical coherence tomography. *Ophthalmology.* 2013;120(12):2508-16.
- Yang SJ, Han YH, Song GI, Lee CH, Sohn SW. Changes of choroidal thickness, intraocular pressure and other optical coherence tomographic parameters after haemodialysis. *Clin Exp Optom.* 2013;96(5):494-9.
- Ulaş F, Doğan Ü, Keleş A, Ertılav M, Tekçe H, Celebi S. Evaluation of choroidal and retinal thickness measurements using optical coherence tomography in non-diabetic haemodialysis patients. *Int Ophthalmol.* 2013;33(5):533-9.