



## Retroperitoneal Ciliated Foregut Cyst: A Rare Malformation Retroperitoneal Silyalı Foregut Kisti: Nadir Bir Malformasyon

Asuman Kilitçi<sup>1</sup>, Haldun Umudum<sup>2</sup>, Osman Memiş<sup>3</sup>

Foregut cyst (FC) is an uncommon, benign, solitary cyst comprising four layers: ciliated pseudostratified columnar epithelium, subepithelial connective tissue, smooth muscle layer, and outer fibrous capsule. FCs are classified as bronchogenic, enterogastric, or undifferentiated. Friedreich first described the lesion in 1857 and predicted its congenital origin. We present an FC that developed in the retroperitoneum and was difficult to separate from other retroperitoneal cystic mass lesions. A 27-year-old female presented with flank pain. Abdominal computed tomography revealed a cystic lesion, measuring approximately 7.8 cm in diameter, located near the posterior stomach, superior pole of the left kidney, and pancreas. Total cystectomy was performed. Macroscopic examination revealed a 7.8x6 cm unilocular cyst enclosed by a thin capsule, which contained a viscous, yellowish fluid. No solid component was observed in the lesion. The surgeon confirmed no continuity of the cyst into the surrounding organs. Microscopy revealed the cyst to comprise four layers. In focal areas, seromucous glands were observed in the wall. There was no evidence of malignancy. With these findings, this case was diagnosed as retroperitoneal ciliated FC. FC located in the abdomen or retroperitoneum is extremely rare, and few cases have been described in literature. Intraabdominal and retroperitoneal locations have been explained by the presence of pleuroperitoneal canals in the early embryonic stage. FC should be considered in the differential diagnosis of retroperitoneal cystic masses including lymphangiomas, cystic pancreatic tumors, pseudocysts, and hematomas.

**Keywords:** Retroperitoneum, foregut cyst, malformation

Foregut kisti (FC), silyalı psödostratifiye kolumnar epitel, subepitelyal bağ dokusu, düz kas tabakası ve dış fibröz kapsül olmak üzere dört tabakadan oluşan nadir, benign, soliter bir kisttir. FC'ler bronkojenik, enterogastrik ve diferansiye olmayan olarak sınıflandırılır. Friedreich lezyonu ilk kez 1857'de tanımlamış ve doğuştan kökenini öngörmüştür. Retroperitoneal bölgede ortaya çıkan ve diğer retroperitoneal kistik kitle lezyonlarından ayrılması zor bir FC sunuyoruz. 27 yaşındaki bayan, yan ağrısı ile başvurdu. Karın BT'sinde, mide posterioru, sol böbrek üst kutbu ve pankreas arasına yerleşmiş yaklaşık 7,8 cm çapında kistik bir lezyon izlendi. Total kistektomi yapıldı. Makroskopik incelemede, ince bir kapsülle çevrili, visköz, sarımsı sıvı bulunan 7,8x6 cm uniloküle bir kist ortaya çıktı. Lezyonda katı bir bileşen yoktu. Cerrah kistin çevresindeki organlarla devam etmediğini doğruladı. Mikroskopik kistin dört tabakadan oluştuğunu gösterdi. Fokal alanlarda, duvarda seromüköz bezler görüldü. Malignite bulgusu yoktu. Bu bulgularla olguya retroperitoneal silyalı foregut kisti tanısı verildi. Karında veya retroperitoneumda yer alan FC son derece nadirdir ve İngilizce literatürde az sayıda olgu bildirilmiştir. Karın içi ve retroperitoneal yerleşim yerleri, erken embriyonik evredeki plevroperitoneal kanalların varlığı ile açıklanmıştır. Lenfanjiomlar, kistik pankreas tümörleri, psödokistler, hematomlar ve retroperitoneal kistik kitlelerin ayırıcı tanısında FC düşünülmelidir.

**Anahtar Kelimeler:** Retroperiton, foregut kisti, malformasyon

**ORCID IDs of the authors:** A.K. 0000-0002-5489-2222; H.U. 0000-0002-4550-1971; O.M. 0000-0002-1124-9691

This study was presented as an poster presentation in the 29<sup>th</sup> European Congress of Pathology, 2-6 September 2017, Amsterdam, Holland

<sup>1</sup>Department Of Pathology, Ahi Evran University Training and Research Hospital, Kırşehir, Turkey

<sup>2</sup>Department Of Pathology, Ufuk University Medical Faculty, Ankara, Turkey

<sup>3</sup>Department Of General Surgery, Ahi Evran University Training and Research Hospital, Kırşehir, Turkey

**Yazışma Adresi**

**Address for Correspondence:**

Asuman Kilitçi

E-mail: dr.asuk@gmail.com

Geliş Tarihi/Received: 08.02.2017

Kabul Tarihi/Accepted: 20.08.2017

© Telif Hakkı 2018 Makale metnine istanbulmedj.org web sayfasından ulaşılabilir.

© Copyright 2018 by Available online at istanbulmedj.org

### Introduction

Foregut cyst (FC) arises via abnormal budding of the tracheobronchial tree during the third to seventh weeks of intrauterine life. Although various classifications with overlapping groups added confusion regarding nomenclature, according to pathological findings, FCs are classified as bronchogenic, enterogenous, and undifferentiated (1). "Bronchogenic cysts" (BCs) comprise cartilage and seromucinous glands in addition to ciliated pseudostratified epithelium in the cyst walls. The presence of a ciliated pseudostratified epithelium, two well-differentiated muscular layers, and associated ganglion cells in the cyst wall suggests an "enterogenous type." If the cyst wall contains a mixed combination of the above components, the FC is designated as "undifferentiated FC" (2), which comprises the liver, pancreas, upper digestive tract, tracheobronchial tree, or gallbladder, probably by migration (3). Retroperitoneal FC is thought to originate in aberrantly migrated primitive ventral foregut cells, which are multipotential (4). FC is a relatively rare cystic disease arising in the retroperitoneum, and only few cases have been published in medical literature.

Here, we describe a FC that highlights the difficulty in distinguishing it from other cystic masses found in the retroperitoneal area.

### Case Report

A 27-year-old female was admitted with complaints of epigastric discomfort and flank pain. On physical examination, it was evaluated as nonspecific abdominal pain without palpable

abdominal mass. She was referred by her urologist for abdominal computed tomography (CT). Abdominal CT revealed a mass lesion in the left retroperitoneum. It revealed a cystic lesion, measuring approximately 7.8 cm in diameter, connected to the posterior stomach, superior pole of the left kidney, and pancreas. Laboratory studies were normal. The patient underwent an open resection of the cyst, which was easily dissected. Preoperative diagnosis indicated a mesenteric cyst. The patient's postoperative course was unremarkable. The cystic mass was sent to the pathology laboratory. Macroscopic examination revealed a 7.8×6 cm cyst comprising one loculus and surrounded by a thin wall, including a viscous, yellowish fluid (Figure 1). The cyst lining was smooth, and the wall was 0.3-cm thick. The solid part was not observed. Anatomical continuity of the cyst into surrounding organs was not confirmed by the surgeon. Microscopy revealed an inner layer of mature, ciliated, pseudostratified epithelium without cartilage, subepithelial connective tissue, smooth muscle layer, and outer fibroadipose tissue layer. In focal areas, mucous glands were observed in the cyst wall (Figure 2-4). No mitoses were identified in epithelial cells, and there was no evidence of pleomorphism or nuclear atypia, suggesting malignant neoplasm. The ciliated epithelial cells and seromucous glands were strongly immunoreactive for cytokeratin (CK)7, CK5/6, EMA, and thyroid transcription factor 1 (TTF-1); focal immunoreactive for CEA; and non-immunoreactive for p53, CDX-2, CK20, and Ber-Ep4 (Figure 5, 6). By these findings, a FCM diagnosis was made. Clinical examination showed no evidence of recurrence in the 22 months following surgery. Consent was obtained from the patient participating in this study.

## Discussion

FCs are lesions common in the mediastinum; however, they are rarely found in the peripancreatic or perirenal regions. According to a study, their intraabdominal and retroperitoneal locations are associated with abnormal canalization, the development of which is attributable to the existence of two patent pleuroperitoneal canals (5). A histological distinction arises during the budding and developmental stage (3).

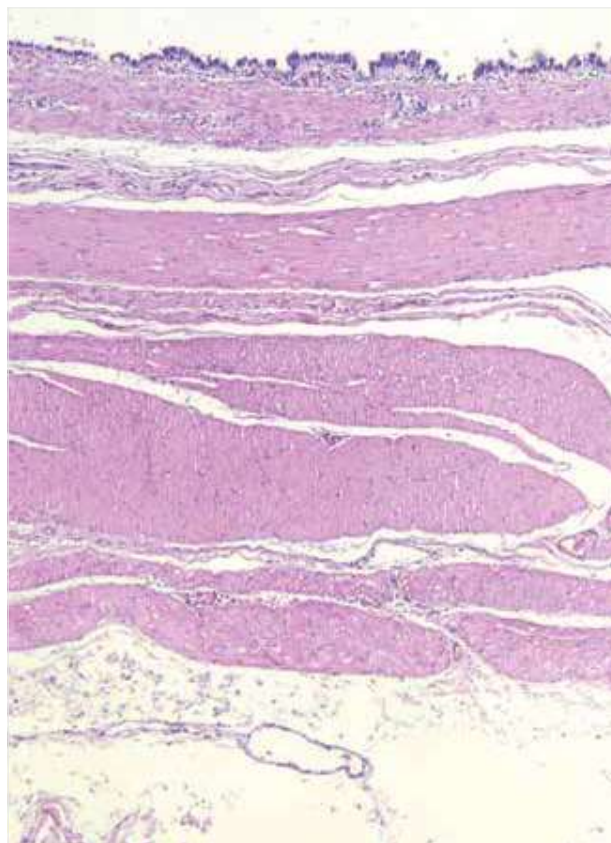
The lesion is mostly asymptomatic and incidentally found upon radiologic imaging during surgical exploration or autopsy. Patients



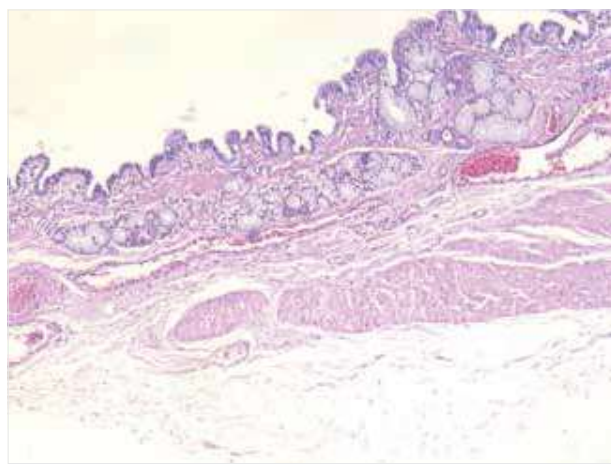
**Figure 1.** Gross image of the resected specimen reveals a unilocular cyst enclosed by a thin capsule. The cyst lining was smooth.

with FC may present with abdominal or flank pain, with or without accompanying nausea and vomiting (2, 6).

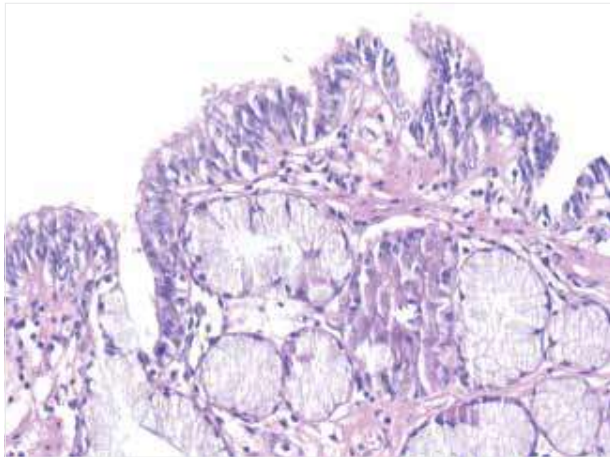
Based on histological features, our case could not be severely classified, and was thought to be appropriately designated "undifferentiated FC." Contrary to the bronchogenic and enterogenous cysts, it lacks distinctive features of cartilage or two well-developed smooth muscle layers. Our case demonstrated that the innermost tissue is the epithelium containing ciliated and



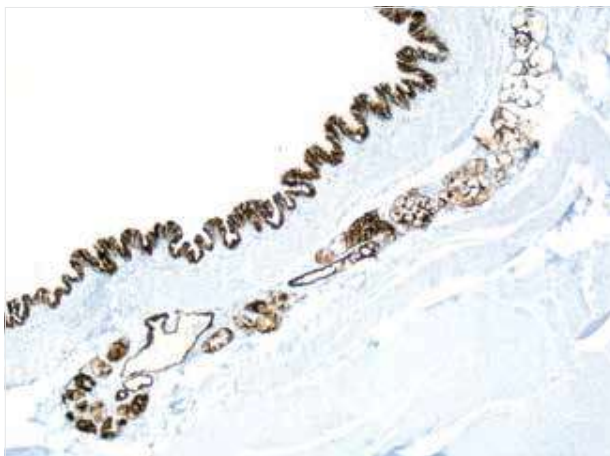
**Figure 2.** Four distinct layers of the cyst: inner lining epithelial cell layer, subepithelial connective tissue, smooth muscle layer, and outer fibroadipose tissue layer (Hematoxylin and eosin, ×50).



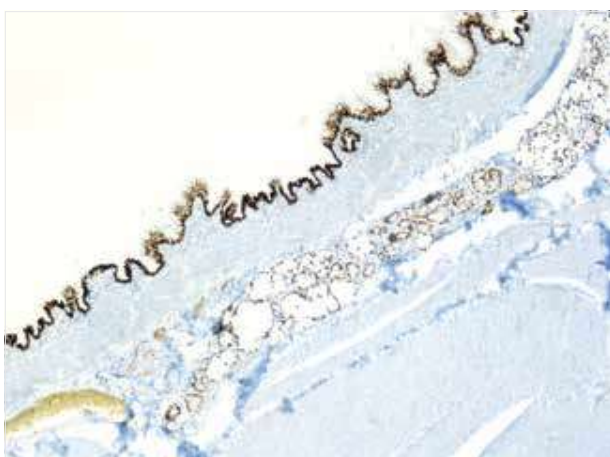
**Figure 3.** Four distinct layers of the cyst: inner lining epithelial cell layer, subepithelial connective tissue, smooth muscle layer, and outer fibroadipose tissue layer (Hematoxylin and eosin, ×50).



**Figure 4.** Cystic lining cells consisting pseudostratified ciliated columnar epithelium with abundant goblet cells (H&E, ×200).



**Figure 5.** Immunohistochemistry of the cyst epithelium and seromucous glands revealing strong positivity for cytokeratin 7 (CK7, ×50).



**Figure 6.** Pseudostratified ciliated columnar epithelium and seromucous glands stained nuclear positive for thyroid transcription factor 1 (TTF-1) by immunohistochemistry (×50).

mucous cells. The subepithelial connective tissue comprised irregular and thick smooth muscle and outer fibrous tissue (Figure 2, 3).

Ciliated FC may demonstrate squamous metaplasia. Squamous cell carcinoma can arise from a focus of squamous metaplasia of epithelial cells. There are few reports on the occurrence of squamous cell carcinoma in ciliated FC (7). Our case comprised ciliated cuboidal or columnar cells without squamous metaplasia. Histologic examination and accurate pathologic diagnosis are essential to avoid unnecessary additional treatment.

Retroperitoneal FCs may be confused with retroperitoneal cystic lymphangiomas, cystic pancreatic tumors, sarcomas, pseudocysts, hematomas, and abscesses (3). The differential diagnosis is mainly with BC, which is usually discovered in the posterior part of the mediastinum, because both cystic lesions derive from a common embryonic origin. In BC, pinching consists at a state of bronchial differentiation when cartilage exists, as FCs originate from pinching of the bud after bronchiolar differentiation, resulting in lack of the cartilage tissue (8). The presence of cartilage and respiratory glands in addition to ciliated columnar epithelium in the cyst wall may provide a clue to the BC in surgical excision materials (9). Cartilage or glandular components may not always be seen in BC. In reports, all BCs showed immunoreactivity for CK7 and were non-immunoreactive for CK20 and CDX2. In rare cases, rare cells expressed TTF-1 (10). In this case, the immunoreactivity for TTF-1 was diffuse positive. Even though the cyst location and immunoprofile ensured valuable clues, it did not strictly suffice to exclude the incomplete form of BC. Owing to the combined morphological features of incomplete BC and FC, we chose the term “undifferentiated FC.”

Although FCs have characteristic imaging findings, radiological appearances are generally unspecific and may mimic cystic tumors. Upon ultrasonographic evaluation, the most consistent findings in ciliated FC are the presence of hypoechoic unilocular cysts and echogenic materials in the lumen. CT scans show these lesions as hypodense in nature in most reported cases. Magnetic resonance imaging is useful in revealing the cyst’s continuity to adjacent organs (11). Discrimination may be difficult by imaging methods alone; hence, serological and aspiration cytology may be used. Despite these studies, a specific preoperative diagnosis cannot always be defined. Our case did not present specific imaging appearances.

Though containing various entities, retroperitoneal tumors are presented to have total 80% malignancy (12). Benignancy cannot be predicted. Laparoscopy has potential serious complications causing perforation, bleeding, or fistulation. Hence, the first therapy option is open surgical resection. In this case, open surgery was chosen.

**Informed Consent:** Written informed consent was obtained from patient who participated in this case.

**Peer-review:** Externally peer-reviewed.

**Author Contributions:** Concept - A.K., H.U., O.M.; Design - A.K., H.U., O.M.; Supervision - A.K., H.U., O.M.; Resource - A.K., H.U.; Materials - A.K., O.M.; Data Collection and/or Processing - A.K., H.U.; Analysis and/or Interpretation - A.K.; Literature Search - A.K., H.U.; Writing - A.K., H.U., O.M.; Critical Reviews - A.K., H.U.

**Conflict of Interest:** No conflict of interest was declared by the authors.

**Financial Disclosure:** The authors declared that this study has received no financial support.

**Hasta Onamı:** Yazılı hasta onamı bu çalışmaya katılan hastadan alınmıştır.

**Hakem Değerlendirmesi:** Dış Bağımsız.

**Yazar Katkıları:** Fikir - A.K., H.U., O.M.; Tasarım - A.K., H.U., O.M.; Denetleme - A.K., H.U., O.M.; Kaynaklar - A.K., H.U.; Malzemeler - A.K., O.M.; Veri Toplanması ve/veya işlemesi - A.K., H.U.; Analiz ve/veya Yorum - A.K.; Literatür taraması - A.K., H.U.; Yazıyı Yazan - A.K., H.U., O.M.; Eleştirel İnceleme - A.K., H.U.

**Çıkar Çatışması:** Yazarlar çıkar çatışması bildirmemişlerdir.

**Finansal Destek:** Yazarlar bu çalışma için finansal destek almadığını belirtmiştir.

## References

1. Tsai IT, Yu CC, Lee FY, Wu CC. Retroperitoneal Foregut Cyst. *J Cancer Res Pract* 2013; 29: 160-4.
2. Galan K, Myers JA, Deziel D. Subdiaphragmatic foregut cyst: case report, differential diagnosis, and review of the literature. *JSLs* 2008;12: 183-7.
3. Kajiya Y, Nakajo M, Ichinari N, Yamazumi K, Otuji T, Tanaka T. Retroperitoneal Foregut Cyst. *Abdom Imaging* 1997; 22: 111-3. [\[CrossRef\]](#)
4. Yamato E, Nakayama H, Ozaki N, Kitamura Y, Funatsuka M, Ueda M et al. Laparoscopically resected foregut cyst adjacent to the right adrenal gland. *Diagn Ther Endosc* 1998; 5: 53-6. [\[CrossRef\]](#)
5. Sumiyoshi K, Shimizu S, Enjoi M, Iwashita A, Kawakami K. Bronchogenic cyst in the abdomen. *Virchows Arch A Pathol Anat Histopathol* 1985; 408: 93-8. [\[CrossRef\]](#)
6. Yang JD, Moon WS. Ciliated hepatic foregut cyst. *The Korean J Hepatol* 2012; 18: 98-100. [\[CrossRef\]](#)
7. Vick DJ, Goodan ZD, Deavers MT, Cain J, Ishak KG. Ciliated hepatic foregut cyst: A Study Of Six Cases And Review Of The Literature. *Am J Surg Pathol* 1999; 23: 671-7. [\[CrossRef\]](#)
8. Chatelain D, Chailley-Heu B, Terris B, Molas G, Le Cae A, Vilgrain V et al. The ciliated hepatic foregut cyst, an unusual bronchiolar foregut malformation: A histological, histochemical, and immunohistochemical study of 7 cases. *Hum Pathol* 2000; 31: 241-6. [\[CrossRef\]](#)
9. Wheeler DA, Edmondson HA. Ciliated hepatic foregut cyst. *Am J Surg Pathol* 1984; 8: 467-70. [\[CrossRef\]](#)
10. Liu L, Zhang Y, Zhang Z, Si L. Perianal bronchogenic cyst: a report of two cases. *Indian J Pathol Microbiol* 2013; 56: 411-2.
11. Kadoya M, Matsui O, Nakanuma Y, Yoshikawa J, Arai K, Takashima T. et al. Ciliated hepatic foregut cyst: radiologic features. *Radiology* 1990; 175: 475-7.
12. Armstrong JR, Cohn I. Primary malignant retroperitoneal tumors. *Am J Surg* 1965; 110: 937-43.

Cite this article as: Kilitçi A, Umudum H, Memiş O. Retroperitoneal ciliated foregut cyst: a rare malformation. *İstanbul Med J* 2018; 19: 62-5.