



Effects of Thymoquinone and Citalopram on Oxidative Stress in Gastric and Duodenum Tissue in Reserpinized Rats

Dilek Kuzay

ABSTRACT

Objective: Medicaments used in the therapy of GIS diseases have many detrimental impacts. Therefore, antioxidant effective molecules can help in the treatment process. This study aimed to examine the oxidant and antioxidant activity of thymoquinone (TQ) and citalopram in gastric and duodenum tissues of reserpinized rats.

Materials and Methods: In the study, we split the rats in six groups of six rats each: 1) Control (C) 1; 2) Control (C) 2; 3) reserpine (R); 4) Reserpine+citalopram (R+C); 5) Reserpine+thymoquinone (R+T); 6) Reserpine+citalopram+thymoquinone (R+C+T). Reserpine (0.2 mg/kg) was intraperitoneally administered. TQ (10 mg/kg) and citalopram (10 mg/kg) were intragastrically administered 30 min before reserpine injection. The rats were treated for 14 consecutive days. At the end of the experiment, we examined total antioxidant status and total oxidant status in gastric tissue; and total nitric oxide, malondialdehyde, and glutathione levels in duodenum tissue.

Results: There was a reduction on total oxidant status in gastric tissue in the R+C group in comparison with the R group ($p<0.01$). The decrease in total oxidant status in the R+C+T and R+T groups was more significant ($p<0.01$). An increase in total antioxidant status was observed in the R+C, R+T, and R+C+T groups when compared to the R group ($p<0.01$). In comparison to the R group, there was a reduction in malondialdehyde and nitric oxide levels and a rise in glutathione level in duodenum tissue in the R+C+T and R+T groups ($p<0.01$).

Conclusion: Reserpine increased oxidative stress and decreased antioxidant capacity in gastric and duodenum tissues. TQ and citalopram+TQ treatment decreased oxidative stress and increased antioxidant capacity in gastric and duodenum tissues. TQ and citalopram+TQ treatments proved to be more effective in protection from oxidative stress caused by reserpine in gastric and duodenum tissues than citalopram treatment.

Keywords: Thymoquinone, reserpine, oxidative stress, stomach, duodenum

Cite this article as:
Kuzay D. Effects of Thymoquinone and Citalopram on Oxidative Stress in Gastric and Duodenum Tissue in Reserpinized Rats. Erciyes Med J 2019; 41(3): 295-9.

INTRODUCTION

Prostaglandins (PGs) and nitric oxide (NO) protect gastric mucosa in physiological conditions. Breakdown of the balance between the defensive mechanisms of mucosa and aggressive factors (e.g., secretion of gastric acids, oxidants, free radicals) and exogenous factors (e.g., *Helicobacter pylori* infection, nonsteroidal anti-inflammatory drugs and some other drugs) causes gastrointestinal (GI) disorders (1, 2). Ulcers are widespread GI disorders that affect almost 10% of the world population (3). Reactive oxygen species (ROS) such as superoxide anions, hydroxyl radicals, hydrogen peroxide, and peroxynitrite are potent oxidizing agents that damage cellular membranes with lipid peroxidation (LPO) as a major consequence. It appears that oxidative stress is responsible for pathogenesis of several GI disease (4).

Reserpine, first obtained from the root of the *Rauvolfia serpentina* in 1952, revolutionized the treatment of hypertension. However, long-term overdose use of reserpine causes depression and sexual dysfunction (5). Besides, long-term use of reserpine increases cholinergic tonus; and by suppressing adrenergic activity, it leads to gastric mucosal lesion with an increase in gastric acid production and motility (6). Some studies indicate that reserpine has strong oxidant activity in plasma and tissues (7–9). In spite of all these effects, reserpine is still used in China as it is more effective and cheaper along with other hypotensive drugs such as compound hypotensive tablets (CHTs) and compound reserpine tablets (5).

Selective serotonin reuptake inhibitors (SSRIs) such as citalopram act both centrally and peripherally to increase the availability of physiologically released serotonin (5-hydroxytryptamine; 5HT). 5-HT, a neurotransmitter in the enteric nervous system, is considered to responsible for control of GI motility. Myriad of studies have examined the act of 5-HT in the control of gastric motility (10). However, whether citalopram has any gastroprotective activity in terms of antioxidant and oxidative system has not been investigated.

Department of Physiology, Ahi Evran University Faculty of Medicine, Kırşehir, Turkey

Submitted
07.03.2019

Accepted
11.06.2019

Available Online Date
10.08.2019

Correspondence
Dilek Kuzay,
Department of Physiology,
Ahi Evran University,
Faculty of Medicine,
40100 Kırşehir, Turkey
Phone: +90 312 280 3900
e-mail: dilekkuzay@gmail.com

©Copyright 2019 by Erciyes
University Faculty of Medicine -
Available online at
www.erciyesmedj.com

Thymoquinone (TQ) is the main component obtained from *Nigella sativa*. TQ is an antioxidant and cytoprotective compound that inhibits LPO. TQ has several favorable effects (hepatoprotective, antidiabetic, antibacterial) and is associated with the modulation of the immune system (4, 11).

Even though many drugs are used for the treatment of GI disorders, all these drugs have adverse impacts and they are not remedial. Therefore, antioxidant and anti-inflammatory treatments may be considered as encouraging method, and it would be possible to diminish the detrimental impacts of ROS by antioxidant drugs. Therefore, our study aimed to research the oxidant and antioxidant activity of TQ and citalopram in gastric and duodenum tissues of reserpinized rats.

MATERIALS and METHODS

Animals

Adult male Wistar Albino rats (weighing 250 ± 20 g) were obtained from the laboratory animal center. Animals were maintained in a standard 12 h light/dark cycle in cages with ad libitum access to food and water. They were allowed to acclimate to the environment for 14 days.

Experimental Design

In this experiment, 36 rats were used. The rats were separated into six groups of six animals in each group:

1. Control (C) 1, the negative control group was injected with 1% Tween 80 ($0.5 \text{ mL} \cdot \text{kg}^{-1} \cdot \text{d}^{-1}$ once daily, ip.) for 14 days.
2. Control (C) 2, the negative control group was injected with 1% Tween 80 ($0.5 \text{ mL} \cdot \text{kg}^{-1} \cdot \text{d}^{-1}$, ip) and tap water (1 mL, once daily, ig) for 14 days.
3. Reserpine (R), was injected with reserpine ($0.5 \text{ mL} \cdot \text{kg}^{-1} \cdot \text{d}^{-1}$, once daily, ip.) for 14 days.
4. Reserpine+citalopram (R+C), was injected with reserpine ($0.5 \text{ mL} \cdot \text{kg}^{-1} \cdot \text{d}^{-1}$, once daily, ip) and citalopram (1 mL, once daily, ig) for 14 days.
5. Reserpine+TQ (R+T), was injected with reserpine ($0.5 \text{ mL} \cdot \text{kg}^{-1} \cdot \text{d}^{-1}$, once daily, ip) and TQ (1 mL, once daily, ig) for 14 days.
6. Reserpine+citalopram+thymoquinone (R+C+T), was injected with reserpine ($0.5 \text{ mL} \cdot \text{kg}^{-1} \cdot \text{d}^{-1}$, once daily, ip) and citalopram (1 mL, once daily, ig) and TQ (1 mL, once daily, ig) for 14 days.

Reserpine was dissolved in 1% Tween 80 and was intraperitoneally injected 0.2 mg/kg . TQ (10 mg/kg) and citalopram (10 mg/kg) were dissolved in tap water and intragastrically administered 30 min before each reserpine injection. The drugs were prepared freshly each day and injected in a volume of 1 mL/kg . Administration was conducted from 8:00 to 10:00. Reserpine, TQ (CAYMAN Chemical, USA), citalopram hydrobromide (Sigma-Aldrich, USA), and Tween 80 (Biomatic, USA) were used in this study.

Tissue Preparation

The rats were sacrificed by taking blood from their hearts under anesthesia with intra-muscular (IM) rompun (5 mg/kg) + ketamine (45 mg/kg). After decapitation, stomach and duodenum removed

from subjects were frozen in liquid nitrogen and stored at -80°C until examination.

Determination of Tissue Total Antioxidant Status (TAS) and Total Oxidant Status (TOS)

TAS and TOS (YL BİONT, China) were used in this study. Sample was incised and weighed up. The sample was then thawed and kept at $2^\circ\text{C} - 8^\circ\text{C}$. A certain amount of PBS (PH 7.4) was added, and the sample was thoroughly homogenized by hand or homogenizer. The sample was centrifuged (at 2000–3000 rpm) for approximately 20 min. The supernatants were carefully collected and stored at -80°C until use. The levels of TAS and TOS in gastric tissue were measured by ELISA kits.

Determination of Tissue Lipid Peroxide Level

To quantify LPO, the formation of thiobarbituric acid reactive substances (TBARS) was measured as designated formerly. Tissue samples were homogenized in ice-cold trichloroacetic acid (1 g tissue plus 10 ml 10% trichloroacetic acid) in a tissue homogenizer.

After several stages of chemical reaction, absorbance of the samples was spectrophotometrically measured at 535 nm. The expression of lipid peroxide levels was made with respect to malondialdehyde (MDA) equivalents with an extinction coefficient of $1.56 \cdot 10^5 \text{ mol}^{-1}$. The lower limit of detection of TBARS was $0.03 \mu\text{mol/l}$ (12).

Determination of Tissue Glutathione Levels

The glutathione (GSH) levels were defined using the previously described procedure. Briefly, tissue samples were homogenized in ice-cold trichloroacetic acid (1 g tissue plus 10 ml 10% trichloroacetic acid) in a tissue homogenizer. After several stages of chemical reaction, absorbance at 412 nm was measured. The GSH levels were estimated with an extinction coefficient of $13.600 \text{ mol}^{-1} \text{ cm}^{-1}$. The bottom limit of detection of GSH was $0.5 \mu\text{mol/l}$ (12).

Determination of Tissue Total NO Levels

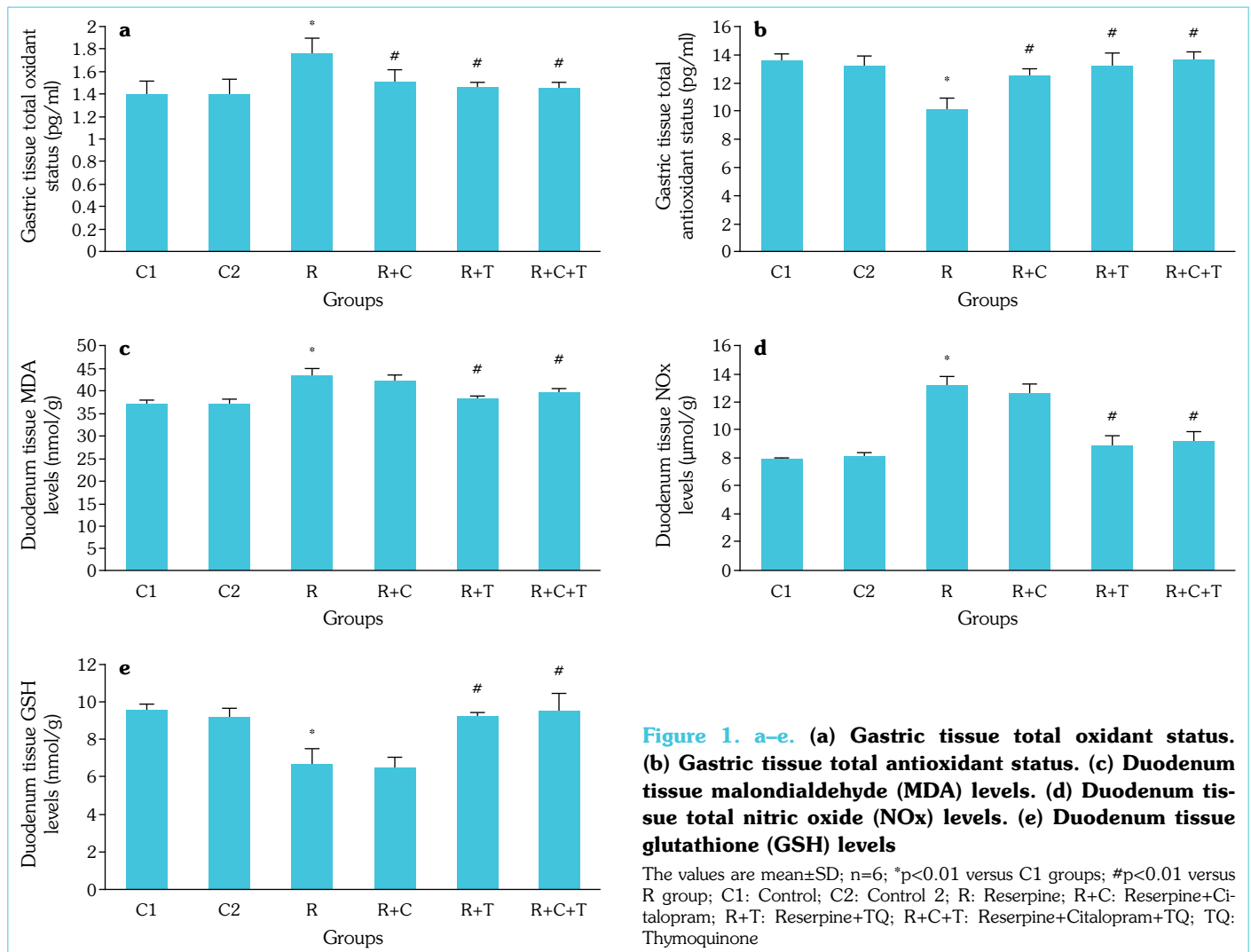
To obtain duodenum NOx levels from ELISA reader, vanadium chloride (VCl₃)/Griess assay was used. Before the detection of NOx, tissues were homogenized in five volumes of phosphate buffer saline (pH=7) and then centrifuged at $2000 \times g$ for 5 min. After several stages of chemical reaction, the samples were measured at 540 nm using ELISA reader (13).

Statistical Analysis

All data were expressed as mean \pm standard deviation (SD). Data were analyzed using the Statistical Package for Social Sciences 15.0 software program. One-way ANOVA was performed to test for differences among the groups. Leven's test statistic was used to variance homogeneous. Shapiro–Wilk's test was used to assess the data normality. Variances were homogeneous, and parametrical test was used because the normality test results were $p > 0.05$. Tukey test was used for post hoc analysis because the variances were homogeneous. $P < 0.05$ was considered statistically significant.

RESULTS

When compared to the C1 group, there was a rise in TOS levels and a reduction in TAS levels in the R group gastric tissue ($p < 0.01$). The TOS levels in gastric tissue decreased in the R+C



group when compared to the R group ($p < 0.01$). The reduction in TOS levels in the R+C+T and R+T was more significant ($p < 0.01$). When compared to the R group, an increase in TAS levels in the R+C, R+T, and R+C+T groups was observed ($p < 0.01$). No statistically important differences were observed among the R+C+T and R+T groups in terms of TOS and TAS levels in gastric tissue ($p > 0.05$) (Fig. 1a, b).

There was a rise in MDA and NOx levels and a reduction in GSH level in duodenum tissue in the R group in comparison to the C1 group ($p < 0.01$). When compared to the R group, there was a reduction in MDA and NOx levels and a rise in GSH level in duodenum tissue in the R+C+T and R+T groups ($p < 0.01$). No differences were observed between the R+C group and R group in terms of NOx, MDA, and GSH levels in duodenum tissue ($p > 0.05$). No statistically important differences were observed among the R+C+T and R+T groups in terms of NOx, MDA, and GSH levels in duodenum tissue ($p > 0.05$) (shown in Fig. 1c-e).

DISCUSSION

In this study, a daily single dose ip. reserpine injection of 0.2 mg/kg for 14 days caused a rise in TOS levels and a reduction in TAS

levels in gastric tissue. At the end of 14 days, MDA and NOx levels increased and GSH levels decreased in duodenum tissue.

In literature, there is a study that examines the relation between oxidative stress caused by reserpine and GIS damage (14). The results of this study support our findings. It was observed that in rats injected with 10 mg/kg ip. reserpine, serum MDA and LPO levels increased; and superoxide dismutase (SOD), glutathione peroxidase (GSH-Px), and catalase (CAT) levels decreased. It was reported that the breakdown of oxidant-antioxidant balance in gastric tissue and plasma could cause gastric tissue damage (14). There are other studies in literature that investigate different activity mechanisms of reserpine. One study reported that a daily single dose ip. reserpine injection of 0.5 ml/kg for 14 days decreased the number of G cells responsible for gastrin release and D cells responsible for somatostatin release in gastric antrum and jejunum; however, the increased amount of acid released due to the increase in G cells / D cells proportion caused ulcer (15). It was also reported that 25 mg/kg ip. reserpine injection increased hepatocyte growth factor (HGF) and cyclooxygenase-2 (COX-2) expression, and thus, inducing local inflammation, it caused ulcer (16). It was observed that 6 mg/kg ip. reserpine injection induced inflammatory mediators and thus caused ulcerative colitis (17). Besides, in another study, it was

reported that reserpine-induced depression-like behaviors and that depression and ulcerative colitis are correlated (18).

In this study, citalopram treatment decreased TOS levels and increased TAS levels in gastric tissue in reserpinized rats. No important differences were observed in duodenum tissue NOx, MDA, and GSH levels. In literature, there is a study that investigates the gastroprotective effects of citalopram administered orally at a dose of 10 mg/kg twice a day for 14 days in rats that were exposed to cold restraint stress (CRS). In CRS model, there was an increase in gastric tissue LPO and nitrite levels and a decrease in PGE₂ levels. In citalopram-treated rats, LPO, nitrite, and PGE₂ levels approached those of the control group. It was found that citalopram decreased inducible nitric oxide synthase (iNOS) levels induced especially by stress. Moreover, it was reported that citalopram stimulated endogenous PGE synthesis through K_{ATP} channel and PGE had protective and acid release regulating effects regarding gastric mucosa by improving the amount and blood flow of mucosa (19). One study reported that tricyclic antidepressants, SSRIs (such as citalopram), and serotonin norepinephrine reuptake inhibitors (SNRI) inhibited IFN- γ , IL-6, and NO production through cAMP-dependent protein kinase A (PKA) pathway and thus had anti-inflammatory activity (17). Another study reported that fluoxetine, an SSRI drug, protects from mucosal damage by increasing prostoglandin and mucus production (20).

In this study, TQ treatment caused a decrease in gastric tissue TOS levels and a rise in TAS levels in reserpinized rats. TQ treatment decreased duodenum tissue MDA and NOx levels and caused an increase in GSH levels. In one study, in a gastric ulcer model formed with acetylsalicylic acid induction, the effects of orogastric gavage implementation of TQ at a dose of 20 mg/kg were investigated. TQ treatment caused a decrease in gastric tissue iNOS, TOS, and oxidative stress index and an increase in TAS, GSH-Px, SOD, and total thiol levels. In contrast to our findings, TQ treatment caused an increase in NO and endothelial eNOS levels (21). For hypoxia/reoxygenation-induced gastric damage, rats were treated with 10 and 20 mg/kg TQ. Following the treatment, there was a decrease in increased levels of MDA and MPO and an increase in decreased levels of GSH and SOD. Again in contrast to our findings, an increase in NOx levels was observed after TQ treatment; 20 mg/kg TQ treatment ensured a more effective improvement than 10 mg/kg TQ treatment (22). In these studies, a single dose of TQ was given. But in our study, TQ was given 14 consecutive days. TQ may increase eNOS activity as an acute effect and increase total NOx levels. However, it may reduce total NOx levels by inhibiting both iNOS and eNOS activity in long-term use.

In accordance with our results, in another study, the effects of four-day 15 mg/kg TQ treatment in rats with diclofenac-induced gastroenteropathy were examined. Diclofenac induction caused a decrease in gastric and duodenum tissue TAS levels and increase in ROS/RNS proportion. While increasing gastric and duodenum tissue TAS levels, TQ treatment did not cause a change in ROS/RNS proportion (23). In rats with acute alcohol-induced gastric mucosa damage, the effects of 10 mg/kg TQ were investigated. Alcohol induction caused a rise in gastric tissue MDA and CAT levels and a decrease in GSH, glutathione-S-transferase (GST), and SOD levels. TQ treatment decreased MDA and CAT levels while it increased GSH, GST, and SOD levels (24).

CONCLUSION

Reserpine caused an increase in gastric and duodenum tissue oxidative stress and a decrease in antioxidant capacity. Citalopram+TQ and TQ treatment decreased gastric and duodenum tissue oxidative stress and increased antioxidant capacity in reserpinized rats. Citalopram treatment decreased gastric tissue oxidative stress and increased antioxidant capacity. TQ and citalopram+TQ treatments were more effective in decreasing reserpine-induced gastric tissue oxidative stress when compared to citalopram treatment. While TQ was effective on both gastric and duodenum tissues, citalopram was effective on only gastric tissue. Further studies are required to explain the protective mechanisms of citalopram and TQ from a damage formed in gastric and duodenum tissues and to determine whether these drugs can be used clinically.

Ethics Committee Approval: The Ethics Committee on Animal Care of Gazi University (Project number G.Ü.ET-16.012) approved all experimental procedures. Every effort was made to minimize animal suffering. All procedures performed in studies involving animals were in accordance with the ethical standards of the institution or practice at which the studies were conducted.

Peer-review: Externally peer-reviewed.

Conflict of Interest: There is no conflict of interest including any financial, personal or other relationships with other people or organizations that could inappropriately influence, or be perceived to influence this work.

Financial Disclosure: The Ahi Evran University Scientific Research Project Directorate of Turkey has funded this project [TIP.A3.17.001].

REFERENCES

- Pahwa R, Neeta, Kumar V, Kohli K. Clinical manifestations, causes and management strategies of peptic ulcer disease. *Int J Pharm Sci Drug Res* 2010; 2(2): 99–106.
- Malferteiner P, Chan FK, McColl KE. Peptic ulcer disease. *Lancet* 2009; 374(9699): 1449–61. [[CrossRef](#)]
- Venkateswararao C, Venkataramana K. A pharmacological review on natural antiulcer agents. *JGTPS* 2013; 4: 1118–31.
- Kanter M, Coskun O, Uysal H. The antioxidative and antihistaminic effect of *Nigella sativa* and its major constituent, thymoquinone on ethanol-induced gastric mucosal damage. *Arch Toxicol* 2006; 80(4): 217–24. [[CrossRef](#)]
- Ma XJ, Lu GC, Song SW, Liu W, Wen ZP, Zheng X, et al. The features of reserpine-induced gastric mucosal lesions. *Acta Pharmacol Sin* 2010; 31(8): 938–43. [[CrossRef](#)]
- Işbil Büyükcoşkun N, Güleç G, Özlük K. Protective effect of centrally-injected glucagon-like peptide-1 on reserpine-induced gastric mucosal lesions in rat: possible mechanisms. *Turk J Gastroenterol* 2006; 17(1): 1–6.
- Cui R, Kang Y, Wang L, Li S, Ji X, Yan W, et al. Testosterone Propionate Exacerbates the Deficits of Nigrostriatal Dopaminergic System and Downregulates Nrf2 Expression in Reserpine-Treated Aged Male Rats. *Front Aging Neurosci* 2017; 9: 172. [[CrossRef](#)]
- Abdel-Majeed S, Mohammad A, Shaima AB, Mohammad R, Mousa SA. Inhibition property of green tea extract in relation to reserpine-induced ribosomal strips of rough endoplasmic reticulum (rER) of the rat kidney proximal tubule cells. *J Toxicol Sci* 2009; 34(6): 637–45.
- Al-Bloushi S, Safer AM, Afzal M, Mousa SA. Green tea modulates reserpine toxicity in animal models. *J Toxicol Sci* 2009; 34(1): 77–87.
- Janssen P, Van Oudenhove L, Casteels C, Vos R, Verbeke K, Tack

- J. The effects of acute citalopram dosing on gastric motor function and nutrient tolerance in healthy volunteers. *Aliment Pharmacol Ther* 2011; 33(3): 395–402. [\[CrossRef\]](#)
11. Darakhshan S, Bidmeshki Pour A, Hosseinzadeh Colagar A, Sisakht-nezhad S. Thymoquinone and its therapeutic potentials. *Pharmacol Res* 2015; 95-96: 138–58. [\[CrossRef\]](#)
 12. Kustimur S, Kalkanci A, Akbulut G, Gonul B, Bulduk E, Aksakal FN, et al. The effect of vaginal candidiasis on the levels of the oxidative biomarkers in plasma and tissue samples of diabetic rats. *Mycopathologia* 2007; 164(5): 217–24. [\[CrossRef\]](#)
 13. Miranda KM, Espey MG, Wink DA. A rapid, simple spectrophotometric method for simultaneous detection of nitrate and nitrite. *Nitric Oxide* 2001; 5(1): 62–71. [\[CrossRef\]](#)
 14. Yi R, Wang R, Sun P, Zhao X. Antioxidant-mediated preventative effect of Dragon-pearl tea crude polyphenol extract on reserpine-induced gastric ulcers. *Exp Ther Med* 2015; 10(1): 338–44. [\[CrossRef\]](#)
 15. Yao YL, Xu B, Zhang WD, Song YG. Gastrin, somatostatin, and experimental disturbance of the gastrointestinal tract in rats. *World J Gastroenterol* 2001; 7(3): 399–402. [\[CrossRef\]](#)
 16. Cantarella G, Martinez G, Di Benedetto G, Loreto C, Musumeci G, Prato A et al. Protective effects of amylin on reserpine-induced gastric damage in the rat. *Pharmacological Research* 2007; 56: 27–34. [\[CrossRef\]](#)
 17. Fattahian E, Hajhashemi V, Rabbani M, Minaiyan M, Mahzouni P. Anti-inflammatory Effect of Amitriptyline on Ulcerative Colitis in Normal and Reserpine-Induced Depressed Rats. *Iran J Pharm Res* 2016; 15(Suppl): 125–37.
 18. Jurjus AR, Khoury NN, Reimund JM. Animal models of inflammatory bowel disease. *J Pharmacol Toxicol Methods* 2004; 50(2): 81–92.
 19. Saxena B, Singh S. Investigations on gastroprotective effect of citalopram, an antidepressant drug against stress and pyloric ligation induced ulcers. *Pharmacol Rep* 2011; 63(6): 1413–26. [\[CrossRef\]](#)
 20. Ji CX, Fan DS, Li W, Guo L, Liang ZL, Xu RM, et al. Evaluation of the anti-ulcerogenic activity of the antidepressants duloxetine, amitriptyline, fluoxetine and mirtazapine in different models of experimental gastric ulcer in rats. *Eur J Pharmacol* 2012; 691(1-3): 46–51. [\[CrossRef\]](#)
 21. Zeren S, Bayhan Z, Kocak FE, Kocak C, Akcilar R, Bayat Z, et al. Gastroprotective effects of sulforaphane and thymoquinone against acetylsalicylic acid-induced gastric ulcer in rats. *J Surg Res* 2016; 203(2): 348–59. [\[CrossRef\]](#)
 22. Magdy MA, Hanan el-A, Nabila el-M. Thymoquinone: Novel gastroprotective mechanisms. *Eur J Pharmacol* 2012; 697(1-3): 126–31.
 23. Aycan İÖ, Elpek Ö, Akkaya B, Kırac E, Tuzcu H, Kaya S, et al. Diclofenac induced gastrointestinal and renal toxicity is alleviated by thymoquinone treatment. *Food Chem Toxicol* 2018; 118: 795–804.
 24. Kanter M, Demir H, Karakaya C, Ozbek H. Gastroprotective activity of *Nigella sativa* L oil and its constituent, thymoquinone against acute alcohol-induced gastric mucosal injury in rats. *World J Gastroenterol* 2005; 11(42): 6662–6. [\[CrossRef\]](#)