

## Investigation of the Protective Effects of Acetyl L-Carnitine on Cisplatin-Induced Uterus Toxicity

### Sisplatin ile İndüklenmiş Uterus Toksisitesinde Asetil L-Karnitinin Koruyucu Etkisinin Araştırılması

Sermin Seyhan<sup>1</sup>, Gulistan Sanem Saribas<sup>2</sup>, Neslihan Coskun Akcay<sup>3</sup>, Seren Gulsen Gurgun<sup>4</sup>, Seda Nur Akyol<sup>5</sup>, Guleser Goktas<sup>6</sup>, Ibrahim Murat Hirfanoğlu<sup>7</sup>, Deniz Erdogan<sup>1</sup>, Candan Ozogul<sup>1</sup>

<sup>1</sup>Gazi University Faculty of Medicine, Department of Histology and Embryology, Ankara, Turkey

<sup>2</sup>Ahi Evran University Faculty of Medicine, Department of Histology and Embryology, Kirsehir, Turkey

<sup>3</sup>Hacettepe University Faculty of Medicine, Department of Obstetrics and Gynecology, Ankara, Turkey

<sup>4</sup>Celal Bayar University School of Vocational Health Services, Department of Histology and Embryology, Manisa, Turkey

<sup>5</sup>Zekai Tahir Burak Women's Health Education and Research Hospital, IVF operating room, Ankara, Turkey

<sup>6</sup>Baskent University Faculty of Medicine, Department of Histology and Embryology, Ankara, Turkey

<sup>7</sup>Faculty of Medicine, Department of Pediatrics, Neonatology Unit, Gazi University, Ankara, Turkey

#### ABSTRACT

**Objective:** The aim of the study was to investigate the prophylactic effects of acetyl L-carnitine against to uterus induced by cisplatin.

**Methods:** Twenty-four female Wistar albino rats were divided into four groups: group I (control) was administered with saline; group II was administered with acetyl L-carnitine; group III was administered with cisplatin; group IV was pretreated with acetyl L-carnitine before cisplatin intraperitoneal injection. After 72h of cisplatin injection uterine tissue was removed. Histological and immunohistochemical investigations were performed, respectively.

**Results:** We found that the number of TUNEL and caspases positive cells were increased in the endometrial epithelium, subepithelial connective tissue, endometrial glands and stroma in group III compare to the other groups. Furthermore inflammation and edema were observed in uterus of rats in group III.

**Conclusion:** We can concluded that pretreatment of acetyl L-carnitine administration has protective effect on histological alteration of uterus caused by cisplatin.

**Key Words:** Acetyl L-carnitine, apoptosis, caspases, cisplatin, TUNEL, uterus

**Received:** 11.13.2017

**Accepted:**09.03.2018

#### ÖZET

**Amaç:** Bu çalışmanın amacı, asetil L-karnitin, sisplatinin neden olduğu uterus hasarına karşı profilaktik etkilerini araştırmaktır.

**Yöntem:** Yirmi dört adet Wistar albino cinsi dişi sıçanlar dört gruba ayrıldı: 1. gruba (kontrol) salin uygulaması yapıldı; 2. gruba asetil L-karnitin uygulaması yapıldı; 3. gruba sisplatin uygulaması yapıldı; 4. grup ise sisplatinin intraperitoneal enjeksiyonu öncesinde asetil L-karnitin ile ön tedaviye tabi tutuldu. Sisplatin enjeksiyonundan 72 saat sonra uterus dokusu çıkarıldı. Histolojik ve immünohistokimyasal incelemeler yapıldı.

**Bulgular:** TUNEL ve kaspaz pozitif hücre sayılarının, diğer gruplara göre 3. grupta endometriyal epitelde, subepitelyal bağ dokusunda, endometriyal bezlerde ve stromada arttığını bulduk. Ayrıca 3. Gruptaki ratların uterusunda inflamasyon ve ödem gözlenmiştir.

**Sonuç:** Asetil L-karnitin ön tedavi uygulamasının, sisplatin kaynaklı uterus histolojisinin değişikliği üzerinde koruyucu etkisi olduğu sonucuna vardık.

**Anahtar Sözcükler:** Asetil L-karnitin, apoptoz, kaspazlar, sisplatin, TUNEL, uterus

**Geliş Tarihi:** 13.11.2017

**Kabul Tarihi:**03.09.2018

**Address for Correspondence / Yazışma Adresi:** Gulistan Sanem Saribas, Faculty of Medicine, Department of Histology and Embryology, Ahi Evran University, Kirsehir, Turkey  
E-mail: sanemarik@gmail.com

©Telif Hakkı 2018 Gazi Üniversitesi Tıp Fakültesi - Makale metnine <http://medicaljournal.gazi.edu.tr/> web adresinden ulaşılabilir.

©Copyright 2018 by Gazi University Medical Faculty - Available on-line at web site <http://medicaljournal.gazi.edu.tr/>

doi:<http://dx.doi.org/10.12996/gmj.2018.81>

## INTRODUCTION

The anticancer drugs, have toxic effects on various organs and tissues, affecting the life quality such as growth problems, ovarian and testicular damage, cardiovascular problems, neuronal developmental problems, secondary malign tumors with decreasing cancer-related mortality rates (1-4).

Cisplatin is one of the broad spectrum antineoplastic agents commonly used in the treatment of many cancer types. Cisplatin causes toxicity with many mechanisms such as hypoxia, mitochondrial damage, inflammation and fibrosis. When cisplatin is taken into the cell, many signaling pathways are activated and apoptosis or necrosis is observed in the cell, besides preventing the proliferation of cancerous cells as well as causing damage to healthy cells due to their structural similarities (5). Cisplatin causes reduction of cellular and nuclear synthetic activity of DNA and RNA in particular, and also damages mitochondrial DNA. Numerous cisplatin mechanisms have been proposed, including cytotoxicity induced by reactive oxygen species, activation of mitogen-activated protein kinase intracellular signaling pathways, caspases and TNF mediated apoptosis, inhibition of ATPase and other intracellular enzymes. After the cisplatin treatment gonadotoxicity is one of the major clinical side effects (6-9). New strategies have been developed to prevent the toxic effects of cisplatin, particularly by contributing to the production of free oxygen radicals, and antioxidants that protect against cell damage by neutralizing free radicals in terms of concurrent preventive treatments have been retained on premise approach (10).

Carnitine is a vitamin-like compound with proven antioxidant properties that regulates the amount of acetylated Coenzyme (CoA), which allows the passage of long chain fatty acids to the mitochondrial matrix to go to beta oxidation during the energy production of the cell, and plays a role in other cellular metabolic events. L- isoform of carnitine is synthesized endogenously and taken from outside. It is a protective agent which has a critical role in mitochondrial functions. L-carnitine, which is arrange the acilCoA / CoA rate and keep in toxic materials inside the mitochondria. Therefore, systemic L-carnitine treatment with cisplatin injection, may prevent the toxic effects by occurring cisplatin (11). Acetyl L-carnitine is an analogue of short chain ester of L-carnitine (12).

Experimental studies have reported that carnitine treatment decreased the hepatotoxicity, cardiotoxicity, neurotoxicity and intestine toxicity which are cause of cisplatin injection (13-15). Studies in different cell types showed that carnitine is a potent antioxidant to prevent cell membrane permeability changes, apoptosis, mitochondrial dysfunction and lipid peroxidation (15).

So, we aimed to investigate the protective effects of acetyl L-carnitine on cisplatin-induced adverse effects in uterus in our study.

## MATERIAL and METHODS

### *Animals and experimental design*

Animals were acquired from the Laboratory Animal Breeding and Experimental Research Centre of Gazi University (GUDAM) and the protocol of the experiment was approved by Ethical Committee of Gazi University and were performed in accordance with the guidelines for the care and use of laboratory animals.

Twenty-four female Wistar albino rats, weighing 200–250 g, were used for the study and were maintained under standart laboratory conditions (12 hr light/dark cycle, 20±2°C, relative humidity 50±15%) for three days. Standard food pellets and tap water were provided ad libitum.

The animals were randomly divided into four groups each containing six rats: Group I (control) treated with saline, Group II treated with acetyl L-carnitine (200 mg/kg), Group III treated with cisplatin (13 mg/kg) and Group IV pre-treated with acetyl L-carnitine (200 mg/kg) before cisplatin (13 mg/kg) treatment. Acetyl L-carnitine (Sigma<sup>®</sup>, Germany, 600 mg dissolved in saline solution 3 mL) was injected subcutaneously into the rats in Groups II and IV and simultaneously saline was injected subcutaneously at the same dose into the rats in Groups I and III. Cisplatin (Cisplatin-Ebewe<sup>®</sup>, Liba, Istanbul, Turkey) was injected 30 min after acetyl L-carnitine/saline injection via intraperitoneal infusion for one hour only the first day into the rats in Groups III and IV. The doses and application methods of cisplatin and acetyl L-carnitine were decided on the basis of the clinical doses converted into animal doses using surface area and as proposed by Tufekci et al and Coskun et al (16, 17). The intervention stated above lasted to the end of the experiment. After 72 h cisplatin treatment (the fourth day) all rats were euthanized by ketamine hydrochloride (40 mg/kg) (Ketalar, Eczacibasi, Istanbul, Turkey) and xylazine hydrochloride (5 mg/kg) (Rompun, Bayer, Istanbul, Turkey) and uterine tissues were taken for the histological analysis.

### *Histological investigations*

Uterine tissue samples were fixed in 10% neutral buffered formalin and embedded with paraffin after routine histological procedures were fulfilled for histological analysis. Paraffin sections of formalin-fixed tissue were sectioned at a thickness of 4 µm for staining with hematoxylin and eosin (H&E). The slides were examined by using a light microscope (Leica DM 4000, Germany).

### *TUNEL assay*

The terminal deoxynucleotidyl transferase dUTP nick endlabelling (TUNEL) method was performed to assess DNA fragmentation. 4 µm-thick uterine tissue cross sections were incubated at 61°C. After deparaffinisation, sections were incubated with 20 µg/mL proteinase K (Roche Diagnostics, GmbH) at 37°C for 25 min and any endogenous peroxidase activity was blocked by incubating in 3% hydrogen peroxide (Lab Vision, Fremont, USA) for 15 min. TUNEL kit (450 µL label solution, 50 µL enzyme solution) (Roche, In Situ Cell Death Detection Kit) was incubated with for 60 min at 37°C in a humid and dark environment. The sections were incubated with converter POD (Roche Diagnostics, Indianapolis, USA) solution in a humid environment at 37°C for 30 min. Subsequent staining with diaminobenzidine substrate solution (DAB) was used to determine TUNEL-positive cells. Mayer's haematoxylin was used as a background stain. Cross-sections were evaluated under a light microscope (Leica DM 4000 Germany) using a computer-supported imaging system to take photos using the Leica Q Vin 3 program (Wetzlar, Germany).

### *Immunohistochemical procedure*

The avidin-biotin peroxidase method was performed for the immunohistochemical studies to investigate anti-caspase 3, 8 and 9 activities. After deparaffinisation, to expose receptor areas within the tissue that were blocked by formaldehyde, tissues were exposed to antigen retrieval in citrate buffer (pH 6.0) (Lab Vision, Fremont, USA) under a high temperature. Following the antigen retrieval procedure, the tissues were allowed to cool down at room temperature for 20 min and then rinsed with distilled water and exposed to 3% hydrogen peroxide (Lab Vision, Fremont, USA) for 15 min. Ultra V block (Lab Vision, Thermo Scientific) was applied for 5 min to prevent nonspecific binding. Following the blocking stage, sections were kept at room temperature for 45 min without being washed and exposed to anti-caspase-9 antibody (caspase-9/LAP6 Ab-4, Rabbit Polyclonal) (Labvision, Thermo Scientific, Fremont), anti- cleaved caspase-3 antibody (caspase 3 (CPP32) Ab-4, Rabbit Polyclonal) (Labvision, Thermo Scientific, Fremont) and primer antibodies that were diluted 1:100. An anti-caspase-8 primer antibody (Rabbit Polyclonal, Labvision, Thermo Scientific, Fremont) was incubated overnight at +4°C. Peroxidase-conjugated secondary antibody (Lab Vision, Thermo Scientific) was applied for 10 min. and reacted for 20 min with streptavidin peroxidase enzyme (Lab Vision, Thermo Scientific) complex for 10 min. Color reaction was developed by incubation with DAB (Spring Bioscience) for approximately 5-10 min to ensure an immune reaction. Mayer's haematoxylin was used as a background stain. Cross-sections were evaluated with imaging system.

### *Statistical analyses*

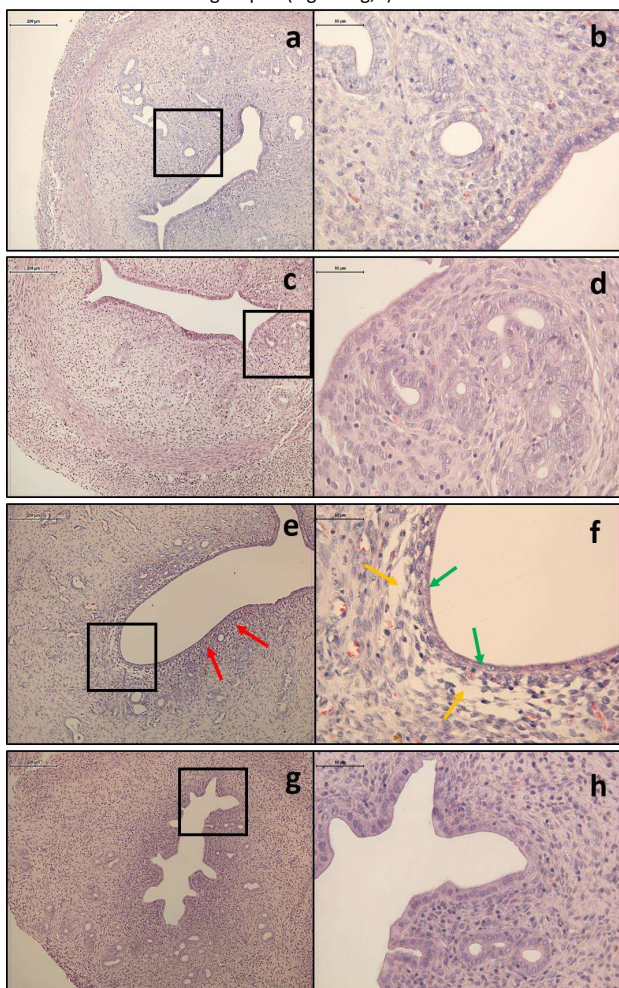
All statistical analyses were performed with Statistical Package for the Social Sciences (SPSS) statistical software (SPSS for Windows, version 16.0). Results are presented as mean ± standart deviation. P values of < 0.05 were considered to indicate statistical significance. The differences between rat weights were statistically evaluated using the Wilcoxon signed rank test. TUNEL-positive and caspase 3, 8 and 9 immunoreactive cells were counted in 10 randomly selected areas (magnification x400) on uterine walls in six cross-sections from each group. Statistical differences between the means of the various groups were evaluated using the Mann Whitney U test.

## RESULTS

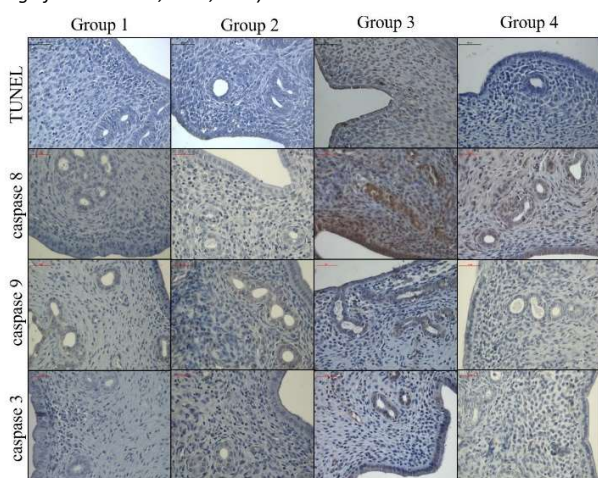
### *Histological results*

We found that the rat uterus showed normal histological structures with H&E staining in group I (Figure 1a,b) and group II (Figure 1c,d). We observed the inflammatory cell infiltration in the endometrial epithelium, intraepithelial area and subepithelial connective tissue in uterus of rats from group III. Cellular debris in the lumen of the endometrial glands and edema in the subepithelial connective tissue were observed in group III.

Furthermore we observed the epithelium that lined the surface of uterus was the single squamous epithelium (Figure 1e,f). When we compare the group IV and group III, intraepithelial lymphocytes were rarely observed in the lumen of endometrial glands and subepithelial edema was not observed in the endometrium of uterus in group IV (Figure 1g,h).



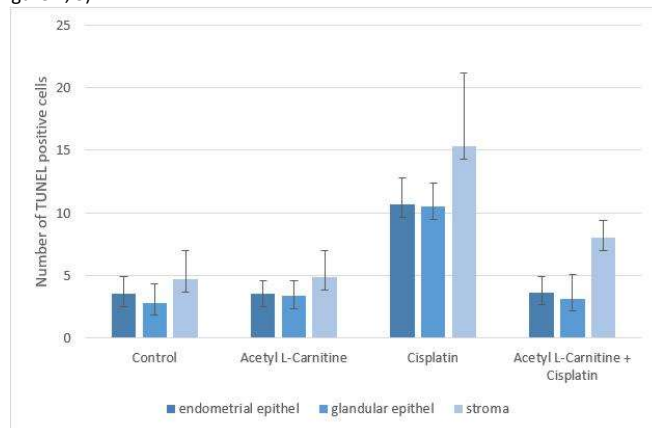
**Figure 1.** Normal microscopic appearance of the uterine tissue in group I (a,b) and group II (c,d). Group III showed inflammatory cell infiltration (red arrows) (e), subepithelial edema (yellow arrows) and squamous epithelium (green arrows) (f). While group IV showed similar results to control group (g,h) (Magnification: x100; x400; H&E).



**Figure 2.** Immunohistochemical and apoptotic findings of all the groups (DAB, Haematoxylin) (Magnification, x400).

### TUNEL results

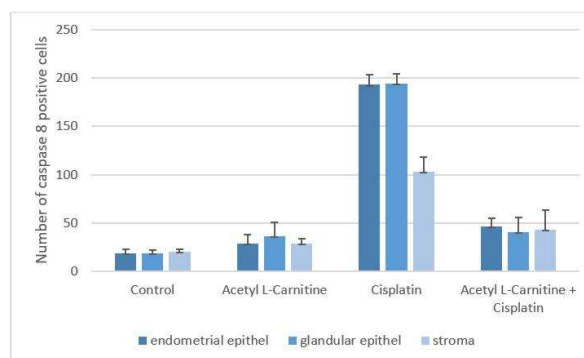
Mean values of the TUNEL-positive cells were determined in uterus epithelium, endometrial glands and endometrial stroma. The number of TUNEL-positive cells were significantly increased in group III (between groups I-III:  $p_{epithelium}=0.004$ ,  $p_{gland}=0.004$ ,  $p_{stroma}=0.008$ ; between groups II-III:  $p_{epithelium}=0.004$ ,  $p_{gland}=0.004$ ,  $p_{stroma}=0.006$ ; between groups IV-III:  $p_{epithelium}=0.004$ ,  $p_{gland}=0.004$ ,  $p_{stroma}=0.030$ ) compare to other groups. When the mean number of cells with DNA fragmentation was analyzed in group IV, the results were similar with group I and II in endometrial epithelium and endometrial glands ( $p>0.005$ ). On the other hand the mean number of cells with DNA fragmentation was significantly increased in the uterus stroma (between groups IV-I:  $p_{epithelium}=0.804$ ,  $p_{gland}=0.806$ ,  $p_{stroma}=0.029$ ; and between groups IV-II:  $p_{epithelium}=0.804$ ,  $p_{gland}=0.743$ ,  $p_{stroma}=0.019$ ). Additionally, the mean number of cells with DNA fragmentation in group IV were lower than in group III ( $p_{epithelium}=0.004$ ,  $p_{gland}=0.004$ ,  $p_{stroma}=0.030$ ) (Figure 2, 3).



**Figure 3.** The mean number of TUNEL positive cells

### Immunohistochemical results

We evaluated cytoplasmic reactivity of caspase 8 in uterine epithelium, gland epithelium and stroma. When we compare with group I and III ( $p_{epithelium}=0.004$ ,  $p_{gland}=0.004$ ,  $p_{stroma}=0.004$ ) and group I and IV ( $p_{epithelium}=0.004$ ,  $p_{gland}=0.006$ ,  $p_{stroma}=0.006$ ) the results were statistically significant. The number of caspase 8-positive cells was higher in group III and IV than group I. Caspase-8 activity was significantly higher in Group III compare with group IV ( $p_{epithelium}=0.004$ ,  $p_{gland}=0.004$ ,  $p_{stroma}=0.004$ ) (Figure 2, 4).



**Figure 4.** The mean number of caspase-8 positive cells

These findings suggest that cisplatin may induce apoptosis that was triggered by caspase 8 in extrinsic pathway and also pretreatment of acetyl L-carnitine may partially prevent apoptosis triggered by caspase 8. We evaluated cytoplasmic reactivity of caspase 9 in uterine epithelium, gland epithelium and stroma. When group I was compared with group III ( $p_{\text{epithelium}}=0.004$ ,  $p_{\text{gland}}=0.004$ ,  $p_{\text{stroma}}=0.004$ ) and group IV ( $p_{\text{epithelium}}=0.012$ ,  $p_{\text{gland}}=0.005$ ,  $p_{\text{stroma}}=0.029$ ) the results were statistically significant. The number of caspase 9-positive cells was higher in group III and IV than group I. Caspase-9 activity was significantly higher in Group III compared with group IV ( $p_{\text{epithelium}}=0.004$ ,  $p_{\text{gland}}=0.004$ ,  $p_{\text{stroma}}=0.004$ ) (Figure 2, 5).

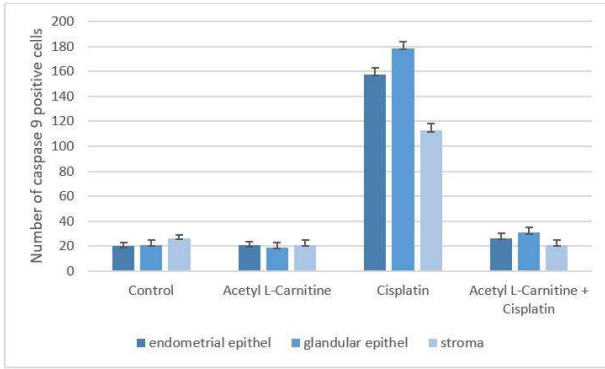


Figure 5. The mean number of caspase-9 positive cells

These findings suggest that the number of proapoptotic cells that leads to apoptosis by the caspase 8-induced extrinsic pathway was higher than that induced by the caspase 9 intrinsic pathway. Also, acetyl L-carnitine pretreatment partially prevented triggered apoptosis. We evaluated cytoplasmic and nuclear reactivity of caspase 3 in uterine epithelium, gland epithelium and stroma. Caspase 3 activity was significantly higher in group III compared with group I ( $p_{\text{epithelium}}=0.004$ ,  $p_{\text{gland}}=0.004$ ,  $p_{\text{stroma}}=0.225$ ). On the other hand, there was no statistically significant difference between group IV and group I ( $p_{\text{epithelium}}=0.197$ ,  $p_{\text{gland}}=0.168$ ,  $p_{\text{stroma}}=0.936$ ). Caspase 3 activity was significantly higher in group III compared with group IV ( $p_{\text{epithelium}}=0.004$ ,  $p_{\text{gland}}=0.004$ ,  $p_{\text{stroma}}=0.872$ ) (Figure 2, 6).

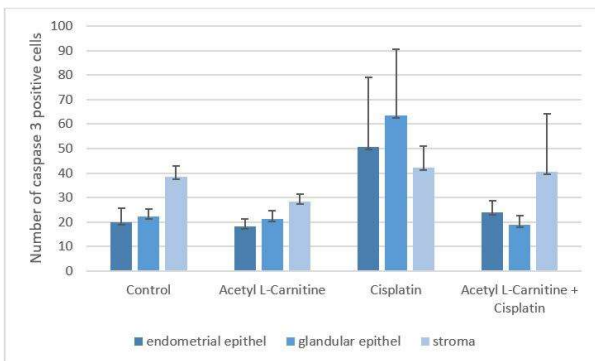


Figure 6. The mean number of caspase-3 positive cells

These findings suggest that cisplatin treatment initiated apoptotic process by activated pro-caspase 3 in endometrial epithelium and gland epithelium. Also acetyl L-carnitine pretreatment partially prevented triggered apoptosis.

## DISCUSSION

Chemotherapeutic agents used in modern cancer treatments are one of the most promising treatment methods nowadays but in long term uses they may cause growth problems, cardiovascular problems, neuronal developmental problems, secondary malign tumors, destroying the balance between oxidants and antioxidants. In this case, after treatment quality of life is decreased (1-4).

Cisplatin, which is an antineoplastic agent, is effective against various neoplasms such as urogenital system carcinomas, central nervous system tumors, advanced ovarian cancers, head, neck, testis, bladder and small cell lung tumors (18).

The main target of cisplatin is nuclear DNA. Also, other intracellular components such as cysteine and methionine are also closely related. DNA-cisplatin adduction may lead to delayed cell cycle progression or inhibition of DNA repair. Cisplatin-induced apoptosis includes many intracellular signal pathways, including activated protein kinase cascades (6).

Besides these effects against tumor cells, cisplatin has known a dose-limiting side effects such as nephrotoxicity, neuropathy, ototoxicity and gonadotoxicity in long-term use, due to structural similarities between healthy and tumor cells (5, 19, 20, 21). Especially formation of reactive oxygen radicals (ROS) and mitochondrial oxidative damage play a critical role to development of cisplatin toxicity (19).

In this study, we investigated the toxic effects of cisplatin on uterus. The toxic effects of cisplatin was demonstrated in various tissue, it was administered intraperitoneally (13 mg/kg/dose during one hour) to rats. After cisplatin treatment our results showed that, endometrial epithelial cells lost their prismatic cell shape form and turned into squamous epithelium. Infiltration of inflammatory cells were observed in subepithelial area, intraepithelial area and subepithelial connective tissue. Furthermore cellular debris in the lumen of the endometrial glands and edema in the subepithelial connective tissue were seen.

Sugiyama et al. found that, while cisplatin reducing the levels of GSSH and free radical scavenging enzymes such as SOD, GSH-Px at tissue, it is leading to an increase in oxygen radicals, especially  $O_2^-$  (22). Another in vivo studies with rats showed that cisplatin reduce the function of some antioxidant enzymes such as SOD and GSH-Px, it has also decrease the level of GSSH, which plays a conservative role in reactive oxygen species. This increase in reactive oxygen species can also lead to DNA damage and lipid peroxidation in cell membrane (23).

David R. et al. were administered cyclophosphamide, a cisplatin-like agent, to the mice. After the injection they were determined decrease of uterine tissue weight, plasma estradiol level and endometrial glands and showed vacuolation of stroma. During the experiment lack of plasma estradiol levels caused atrophy at uterin tissue. At the end of study plasma estradiol level has been returned to normal but no change in uterine weight depending on the decline of the cells in the basal layer of the endometrium, in the connective tissue and myometrium. As a result of the research, it was determined that cyclophosphamide directly affects both the ovary and the uterus (24). Coskun et al. assessed the effects of cisplatin treatment. Researchers reported that rat weights were decreased after cisplatin injection (17). Moreover, Iraz et al. concluded that the toxic effects induced by cisplatin administration include a decrease in SOD and GSH-Px activity, also decrease rat weights (25). As supported by previous study, we found that cisplatin affects histomorphologically at uterine structure and rat weights like cyclophosphamide.

Many studies have been carried out on protective treatments with free radical scavengers because cisplatin is caused an increase of free oxygen radicals (26). These studies have shown that antioxidants play a critical role in toxicity and is understood their importance (10).

L-carnitine is one of the significant antioxidant and free radical scavenger. Some studies have been notified that it increased the antioxidant effects of askorbik asit, glutatyon ve E vitamini and reduced the accumulation of lipofuscin which is known peroxidative marker in neurons (27). Moreover, in a study reported that L-carnitine partially protected the DNA (28).

Coskun et al. have observed the protective effects of L-carnitine against the damage on testicular tissue (17). Moreover Chang et al. administered cisplatin to rats at a dose of 5 mg/kg intraperitoneal to induce nephrotoxicity and reported that acetyl L-carnitine administered subcutaneously at a dose of 200 mg/kg prevented nephrotoxicity (29).

As supported by previous studies, we evaluated prophylactic effects of acetyl L-carnitine administration to rats at a dose of 200 mg/kg against cisplatin toxicity on uterine tissue prophylactic administration of acetyl L-carnitine after cisplatin injection. We found that epithelial cells are typical of uterine endometrium epithelial cell formation, subepithelial connective tissue edema and intraepithelial/subepithelial neutrophilic inflammation are not developed. In our study observed that prophylactic effects of acetyl L-carnitine administration on uterine tissue protect against cisplatin toxicity.

In vitro studies have shown that cisplatin increases apoptosis causing damage to primordial follicles. In addition, oocyte, granulosa and theca cell damage and apoptosis in primordial follicles resulting in chemotherapy can be seen. Saribas et al. concluded that cisplatin caused damage to the tubal tissue and that these injuries were prevented by pretreatment with acetyl L-carnitine (30). Zhang et al. determined that cisplatin administration at Balb/c mice triggered apoptosis on germ cells.



As supported by this study while cisplatin change the maturation periods of spermatogenic series cells, causing azospermia by reducing spermatogenesis. These results obvious that cisplatin may affects fertility (19).

Cytoplasmic caspase release can be determined by immunohistochemical methods using antibodies against caspases, which are apoptotic elements, to detect the presence of apoptosis in a tissue. Caspases 8 and 9, and activated caspase 3 an important agent in apoptosis, to initiate irreversible apoptosis. Another method to determine the apoptosis is TUNEL. This method is shown the cell with DNA fragmentation. TUNEL reaction is the most popular method of recent toxicity studies since it allows the early identification of apoptotic cells in apoptosis (31).

Our study also showed that apoptosis triggered by cisplatin in the uterus was prevented by prophylactic administration of acetyl L-carnitine. This finding was assessed by the TUNEL method, in which the number of cells with DNA fragmentation was determined. In addition, the results of marking anti-caspase 3, 8 and 9 antibodies were evaluated statistically. In the TUNEL results, group IV findings were similar to the control group for uterine epithelium and gland epithelium. Group IV findings were similar to the control group when evaluated for stromal involvement. The number of cytoplasmic and nuclear staining of the caspase 3-labeled uterine epithelial cells and glandular epithelial cells in the group IV was statistically significant compared to the cell numbers in the cisplatin group. When stromal involvement was evaluated; the difference between the group II and group III was evaluated as meaningful, while the difference between the other groups was not significant.

When marked with caspase 8, the number of proapoptotic cells in the uterine epithelium, gland epithelium, and stroma in the group II decreased significantly compared to the cell numbers in the group III. In addition, the number of cells showing caspase 9 involvement in the pre-surgical group III with group II was lower in uterine epithelium, gland epithelium and stroma than in the cisplatin group. However, when the results of caspase 8 and caspase 9 were compared, it was determined that the numbers of proapoptotic cells leading to apoptosis by the extrinsic pathway were higher than those induced by the intrinsic pathway.

Thus, histomorphological and apoptotic effects of cisplatin on uterine tissue were investigated; it is thought that these effects may be protective of the application of prophylactic acetyl L-carnitine. Our study aimed to protect the reproductive system in cancer patients. Similar studies with such treatment approaches will be promising in terms of quality survival for cancer patients in long-term survival.

#### Acknowledgements

This work has supported by Gazi University Scientific Research Project Unit, Ankara, Turkey [grant number: 01/2010-20].

#### Conflict of interest

No conflict of interest was declared by the authors.

#### REFERENCES

1. Sonmezer M, Ozkavukcu S. Fertility preservation in females with malignant disease-1: causes, clinical needs and indications. *Turk J Haematol* 2009; 26:106-13.
2. Familiari G, Caggiati A, Nottola SA, Ermini MD, Benedetto MR, Motta PM. Ultrastructure of human ovarian primordial follicles after combination chemotherapy for Hodgkin's disease. *Hum Reprod* 1993; 8 (12): 2080-7.
3. Fadillioglu E, Erdogan H, Sogut S, Kuku I. Protective effects of erdosteine against doxorubicin-induced cardiomyopathy in rats. *J Appl Toxicol* 2003; 23: 71-4.
4. Fadillioglu E, Erdogan H. Effects of erdosteine treatment against doxorubicin-induced toxicity through erythrocyte and plasma oxidant/antioxidant status in rats. *Pharmacol Res* 2003; 47: 317-22.
5. DeVita VT, Hellman S, Rosenberg SA, editors. *Cancer, principles & practice of oncology*. 7th ed. Philadelphia: A Wolters Kluwer Co; 2005: 295-306.
6. Kelland L. The resurgence of platinum-based cancer chemotherapy. *Nat Rev Cancer* 2007; 7: 573-84.
7. Sonmezer M, Oktay K. Fertility preservation in female patients. *Hum Reprod Update* 2004; 10: 251-66.
8. Warne GL, Fairley KF, Hobbs JB, Martin FI. Cyclophosphamide-induced ovarian failure. *N Engl J Med* 1973; 289: 1159-62.
9. Mackie EJ, Radford M, Shalet SM. Gonadal function following chemotherapy for childhood Hodgkin's disease. *Med Pediatr Oncol* 1996; 27: 74-8.
10. Delibas N, Ozcankaya R. Serbest Radikaller. *SDÜ Tıp Fakültesi Dergisi* 1995; 2: 11-17.
11. Kalinec GM, Fernandez-Zapico ME, Urrutia R, Esteban-Cruciani N, Chen S, Kalinec F. Pivotal role of Harakiri in the induction and prevention of gentamicin-induced hearing loss. *Proc Natl Acad Sci U S A* 2005; 102: 16019-24.
12. Gülçin I. Antioxidant activity of caffeic acid (3,4-dihydroxycinnamic acid). *Toxicology*. 2006; 217: 213-20.
13. Al-Majed AA. Carnitine deficiency provokes cisplatin-induced hepatotoxicity in rats. *Basic Clin Pharmacol Toxicol* 2007; 100: 145-50.
14. Pacifici EH, McLeod LL, Sevanian A. Lipid hydroperoxide-induced peroxidation and turnover of endothelial cell phospholipids. *Free Radic Biol Med* 1994; 17: 297-309.
15. Madesh M, Balasubramanian KA. Activation of liver mitochondrial phospholipase A2 by superoxide. *Arch Biochem Biophys* 1997; 346: 187-92.
16. Tufekci O, Gunes D, Ozogul C, Kolatan E, Altun Z, Yılmaz O, et al. Evaluation of the effect of acetyl L-carnitine on experimental cisplatin nephrotoxicity. *Chemotherapy* 2009; 55: 451-9.
17. Coskun N, Hatipoglu MT, Ozogul C, Korkmaz C, Akyol SN, Micili SC, et al. The protective effects of acetyl L-carnitine on testis gonadotoxicity induced by cisplatin in rats. *Balkan Med J* 2013; 30: 235-41.
18. Rosenberg B. Fundamental studies with cisplatin. *Cancer* 1985; 55: 2303-16.
19. Zhang X, Yamamoto N, Soramoto S, Takenaka I. Cisplatin-induced germ cell apoptosis in mouse testes. *Arch Androl* 2001; 46: 43-9.
20. Molmann JE, Glover DJ, Hogan WM, Furman RE. Cisplatin neuropathy: Risk factors, prognosis, and protection by WR-2721. *Cancer* 1988; 61: 2192-5.
21. Screnci D, Mckeage MJ. Platinum neurotoxicity: Clinical profiles, experimental models and neuroprotective approaches. *J Inorg Biochem* 1999; 77: 105-10.
22. Sugiyama S, Hayakawa M, Kato T, Hanaki Y, Shimizu K, Ozawa T. Adverse effect of anti-tumor drug, cisplatin, on rat kidney mitochondria: disturbances in glutathione peroxidase activity. *Biochem Biophys Res Commun* 1989; 159: 1121-7.
23. Kuhlmann MK, Burkhardt G, Köhler H. Insights into potential cellular mechanisms of cisplatin nephrotoxicity and their clinical application. *Nephrol Dial Transplant* 1997; 12: 2478-80.
24. Plowchalk DR, Meadows MJ, Mattison DR. Reproductive toxicity of cyclophosphamide in the C57BL/6N mouse: 2. Effects on uterine structure and function. *Reprod Toxicol* 1992; 6: 423-9.
25. Iraz M, Ozerol E, Gulec M, Tasdemir S, Idiz N, Fadillioglu E, et al. Protective effect of caffeic acid penethyl ester (CAPE) administration on cisplatin-induced oxidative damage to liver in rat. *Cell Biochem Funct* 2006; 24: 357-61.
26. Ali BH, Al Moundhri MS. Agents ameliorating or augmenting the nephrotoxicity of cisplatin and other platinum compounds: A review of some recent research. *Food Chem Toxicol* 2006; 44: 1173-83.
27. Arockia Rani PJ, Panneerselvam C. Carnitine as a free radical scavenger in aging. *Exp Gerontol* 2001; 36 (10): 1713-26.
28. Vanella A, Russo A, Acquaviva R, Campisi A, Di Giacomo C, Sorrenti V, et al. L-propionyl-carnitine as superoxide scavenger, antioxidant, and DNA cleavage protector. *Cell Biol Toxicol* 2000; 16: 99-104.
29. Chang B, Nishikawa M, Sato E, Utsumi K, Inoue M. L-Carnitine inhibits cisplatin-induced injury of the kidney and small intestine. *Arch Biochem Biophys* 2002; 405: 55-64.
30. Saribas GS, Erdogan D, Goktas G, Akyol SN, Hirfanoglu IM, Gurgun SG, et al. Examining the protective effects of acetyl l-carnitine on cisplatin-induced uterine tube toxicity. *J Obstet Gynaecol* 2016; 36: 1086-92.
31. Pabla N, Dong Z. Cisplatin nephrotoxicity: mechanisms and renoprotective strategies. *Kidney Int* 2008; 73: 994-1007.