

## Research Article

# Reliability of RUST and modified RUST scores for evaluation of union in pediatric and adult femoral shaft fractures

Abdulhamit Mısırlı<sup>1</sup>, Kadir İlker Yıldız<sup>2</sup>, Turan Bilge Kızılcapan<sup>3</sup>, Erdal Uzun<sup>4</sup>, Mustafa Özçamdallı<sup>5</sup>, Sinan Oğuzkaya<sup>6</sup>

<sup>1</sup>Department of Orthopaedics and Traumatology, Health Sciences University Gaziosmanpaşa Training and Research Hospital, İstanbul, Turkey

<sup>2</sup>Department of Orthopaedics and Traumatology, Health Sciences University, Metin Sabancı Baltalimanı Bone and Joint Diseases Training and Research Hospital, İstanbul, Turkey

<sup>3</sup>Clinic of Orthopaedics and Traumatology, Bursa Çekirge State Hospital, Bursa, Turkey

<sup>4</sup>Department of Orthopaedics and Traumatology, Erciyes University, School of Medicine, Kayseri, Turkey

<sup>5</sup>Department of Orthopaedics and Traumatology, Ahi Evran University School of Medicine, Kırşehir, Turkey

<sup>6</sup>Clinic of Orthopaedics and Traumatology, Sivas Salkışla State Hospital, Sivas, Turkey

## ARTICLE INFO

## Article history:

Submitted March 12, 2020

Received in revised form

May 26, 2020

Last revision received

September 12, 2020

Accepted October 6, 2020

## Keywords:

Femur

Radiographic union

Nailing

Scale

Modified

Tibial

## ORCID iDs of the authors:

A.M. 0000-0002-5270-1429;

K.İ.Y. 0000-0003-2034-9974;

T.B.K. 0000-0002-6614-888X;

E.U. 0000-0002-5456-3699;

M.Ö. 0000-0002-9000-2135;

S.O. 0000-0003-3032-5714.

## ABSTRACT

**Objective:** This study aimed to determine the reliability levels of the radiographic union scale for tibial fractures (RUST) and the modified version of the system, mRUST, for femoral shaft fractures in pediatric and adult patients and to evaluate the value of the scores for total and each cortex in the decision making on fracture union.

**Methods:** A total of 15 orthopedic surgeons scored the radiographs of 24 pediatric and 24 adult patients with femoral shaft fractures that were obtained at 0, 4, 8, 12, and 16 postoperative weeks treated with elastic stable intramedullary nail in pediatric patients and locked intramedullary nail in adult patients using the RUST and mRUST scores. Intra-class correlation coefficient (ICC) was used in the evaluation of reliability of the RUST and mRUST scores. The Fleiss kappa (k) coefficient was used in the agreement between evaluators regarding union decision (united or non-united). The thresholds for RUST and mRUST for radiographic union decision were determined. Receiver operating curves were created to evaluate the contribution of total and individual cortical scores in the decision of united or non-united.

**Results:** Intra- and inter-rater reliabilities of mRUST (ICC: 0.92 and 0.86, respectively) were slightly higher than those of RUST (ICC: 0.81 and 0.77, respectively) with perfect intra- and inter-rater reliabilities for RUST (ICC: 0.92 and 0.90, respectively) and mRUST (ICC: 0.88 and 0.83, respectively) in pediatric patients and substantial intra- and inter-rater reliabilities in adult patients (ICC: 0.80 and 0.76, respectively, for mRUST, and 0.76 and 0.71, respectively, for RUST). At each time point, the mean mRUST and RUST scores were higher for pediatric fractures ( $p < 0.001$ ). The Fleiss k coefficient for union decision was perfect for pediatric fractures (0.88) and substantial for adult fractures (0.79). The total mRUST score had a higher predictive value of union than the total RUST score (area under the curve: 0.984 vs. 0.922 in adult fractures and 0.990 vs. 0.943 in pediatric fractures). A RUST score of  $\geq 10$  and mRUST score of  $\geq 12$  were excellent predictors of fracture union.

**Conclusion:** Fracture union of simple two-part pediatric and adult femoral shaft fractures treated with intramedullary fixation can be reliably assessed using the RUST and mRUST scores. The diagnostic value of the mRUST score is more evident in adult fractures.

**Level of Evidence:** Level II, Diagnostic Study

## Introduction

There are no universally accepted tools for the evaluation of healing in femoral fractures (1). In addition to clinical characteristics, such as pain on palpation and weight bearing, serial radiographs have been used to determine fracture healing and union (2). Cortical continuity, loss of fracture line visibility, and size of callus formation are commonly used in making radiological decisions on fracture union (3). The ability to describe fracture healing and union is important in determining the success of treatment and predicting patient outcomes (4). Previously, radiographic criteria for fracture healing included cortical continuity, fracture line visibility, and number of bridging cortices combined with the surgeon's general impression (5). The radiographic union scale for tibial fractures (RUST) was recently developed to assess healing of the tibial shaft fractures after intramedullary nailing (6, 7). Using a numerical value for each tibial cortex (anterior, posterior, medial, and lateral), the RUST uses bridging callus and fracture line visibility to as-

sess fracture healing, both of which have been found to be the most reliable signs of bone healing between observers (2). The validity and reliability of the RUST score have been previously evaluated (7, 8). However, this radiographic scoring system does not propose an exact score to define the bone union. Rather, the RUST score includes a dichotomous decision as to whether the fracture line is visible or not after bridging callus has occurred (4). A fracture line that disappears with complete bone remodeling leads to further subdivision in the cortical assessment regarding the presence or absence of a cortical bridging callus (9). To describe this progression in radiographic healing more accurately, the modified RUST (mRUST) score was developed (4). In addition to the standard RUST score, mRUST further subdivides callus formation into simply present or bridged (1).

To the best of our knowledge, the effect of individual cortical RUST and mRUST scores on the decision of fracture union has not been investigated before. In clinical practice, because the total callus amount

## Corresponding Author:

Abdulhamit Mısırlı  
misirabdulhamitmd@gmail.com



Content of this journal is licensed under a Creative Commons Attribution-NonCommercial 4.0 International License.

Cite this article as: Mısırlı A, Yıldız Kİ, Kızılcapan TB, Uzun E, Özçamdallı M, Oğuzkaya S. Reliability of RUST and modified RUST scores for evaluation of union in pediatric and adult femoral shaft fractures. Acta Orthop Traumatol Turc 2021; 55(2): 127-33.

and cortical bridging is affected, lower RUST or mRUST scores of one or more cortices in a certain follow-up period may affect union decision. Moreover, these scores have not been used to evaluate the differences in healing of adult and pediatric femoral shaft fractures. This is an important clinical issue to consider as the radiographic features of bone healing in children are different from those in adult fractures (10), with pediatric patients requiring less callus formation to achieve a clinically stable or healed fracture (11). A larger sub-periosteal hematoma with a thicker and stronger periosteum provides a more rapid callus formation, leading to a shorter fracture healing time (12). Moreover, although the RUST score has been used to evaluate the femoral shaft fractures in adults (4, 13, 14), to date, it has not been used to evaluate pediatric femoral shaft fractures. Therefore, our study aimed to evaluate the reliability levels of the RUST and mRUST scores for both pediatric and adult femoral shaft fractures and to evaluate the value of the score for each cortex (anterior, posterior, medial, and lateral) in predicting radiographic union.

### Materials and Methods

After institutional review board approval (approval date and number: 22.02.2018/24), pediatric and adult patients with femoral shaft fractures who were treated operatively at our training and research hospital between January 2013 and September 2019 were identified. A total of 102 adult and 94 pediatric fractures were screened. Eligibility for enrollment included patients between the ages of 5 and 12 years or between 18 and 65 years, who had sustained a simple two-part closed femoral shaft fracture and were treated with an intramedullary nail or elastic stable intramedullary nail and those who achieved complete bone union. Exclusion criteria were as follows: comminuted or segmented fractures; fracture non-unions; re-fractures; presence of a neurovascular injury; pathological fractures; osteoporotic fractures; insufficiency fractures; history of systemic infection; malignancy; chemotherapy or radiotherapy treatment; lack of or inadequate radiographs obtained at postoperative weeks 4, 8, 12, and 16; re-displacement of fracture alignment or requirement of revision; and treatment with additional fixation methods. After the exclusion criteria were applied, 48 fractures were included in the study. Of these 48 fractures (24 pediatric and 24 adult patients), 24 radiographic sets each for the pediatric and adult fracture groups were selected for review (Figure 1).

A total of 15 orthopedic surgeons with varying levels of experience (general orthopedic surgeons, trauma surgeons, and pediatric orthopedic surgeons) who were blinded to the patient and radiographic data were invited to review the radiographs of 48 patients twice in a 21-day interval. They were informed about descriptions of the RUST and mRUST scores based on the descriptions of Whelan et al. (6) and Litrenta et al. (4). A total of 48 sets of images, each set including anterior-posterior and lateral view radiographs obtained at 0, 4, 8, 12, and 16 postoperative follow-up weeks, were included in a Microsoft PowerPoint file (Microsoft® Office 2011 for Mac; Microsoft, Redmond, WA). The radiographs were randomly arranged by a person

blinded to the study such that the images within each set were not in chronological order in the first and second evaluations. All images were anonymized.

For radiographic evaluation, each femoral cortex (anterior, posterior, medial, and lateral) was scored according to the RUST scale (1 to 3) or mRUST scale (1 to 4) (Table 1) (4, 6). Reviewers were asked to evaluate each femoral cortex (anterior, posterior, medial, and lateral) and assign both a RUST and mRUST score to each as well as provide a total score. In addition, the surgeons were asked to record whether the fracture was healed or not in their opinion and to group the fractures as united or non-united. To establish an objective and standard decision, fractures, where cortical continuity was achieved in 3 or more of the 4 cortices, were considered as united.

### Statistical analysis

The mean, standard deviation, and median range values were used in the descriptive statistics of the data. The Kolmogorov-Si-

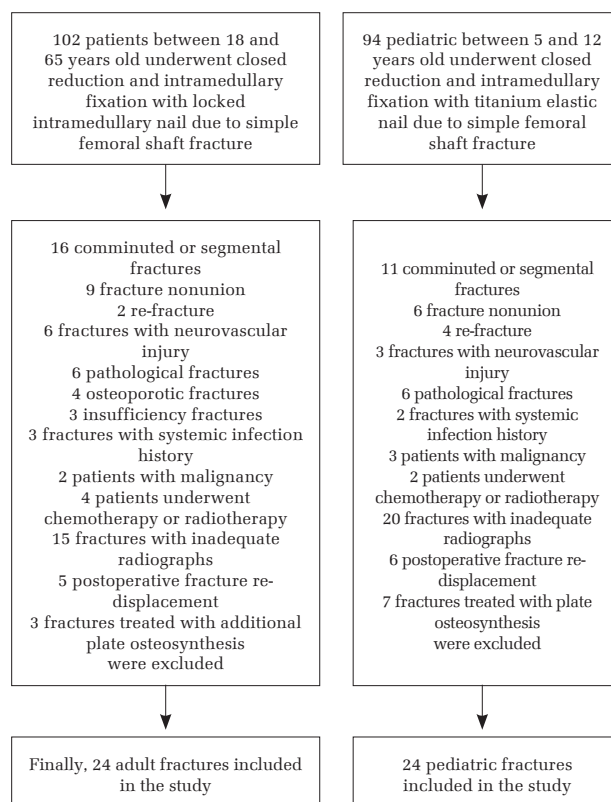


Figure 1. The flowchart showing exclusion steps and exact numbers of exclusions in adult and pediatric fracture groups

Table 1. Comparative descriptive table showing RUST and mRUST scoring. A score is assigned for each cortex, and the total score is calculated by adding the scores assigned for each cortex

Score	RUST score <sup>a</sup>		Score	mRUST score <sup>a</sup>	
	Radiographic criteria			Radiographic criteria	
	Fracture line	Callus		Fracture line	Callus
1	Visible	Absent	1	Visible	Absent
2	Visible	Present	2	Visible	Present
3	Invisible	Present	3	Visible	Bridging
			4	Invisible	Remodeled

RUST: radiographic union scale in tibial fractures; mRUST: modified radiographic union scale in tibial fractures

<sup>a</sup>: Litrenta J, Torretta P 3<sup>rd</sup>, Mehta S, et al. Determination of radiographic healing: An assessment of consistency using RUST and modified RUST in Meladiaphyseal fractures. J Orthop Trauma 2015; 29: 516-20.

<sup>b</sup>: Whelan DB, Bhandari M, Stephen D, et al. Development of the radiographic union score for tibial fractures for the assessment of tibial fracture healing after intramedullary fixation. J Trauma 2010; 68: 629-32.

### HIGHLIGHTS

- A total of 15 surgeons scored the radiographs of 24 pediatric and 24 adult fractures, and the agreement between the scores was evaluated.
- Both the radiographic union scale for tibial fractures (RUST) and modified radiographic union scale for tibial fractures (mRUST) scores reliably assessed fracture healing in pediatric and adult patients.
- The total and individual cortical mRUST scores had significantly higher diagnostic values for radiographic fracture union than the total and individual cortical RUST scores in adult fractures.

mirnov test was used in the evaluation of data distribution. The independent samples t-test was used in the comparison of independent quantitative data. The intra-class correlation coefficient (ICC), with the associated 95% confidence interval (CI), was used to evaluate agreement in the RUST and mRUST scores for the treatment groups (pediatric or adult) and experience levels (general orthopedic surgeon, trauma surgeon, or pediatric orthopedic surgeon) using the total and individual cortical scores. The Fleiss kappa (k) coefficient was used in the evaluation of the agreement between individual examiners regarding the presence of bone union. On the basis of a study by Landis and Koch (15), we defined agreement for ICC scores as follows: 0–0.2, slight agreement; 0.21–0.40, fair; 0.41–0.60, moderate; 0.61–0.8, substantial; and >0.81, perfect agreement. The McNemar test was used in the evaluation of change of the qualitative dependent data. A priori sample size of 24 patients per group was calculated to be needed to reach qualitative estimation. A sample size of 48 (24 adult and 24 pediatric patients) was calculated as necessary to detect a difference in measurements, with 80% power. The type 1 error rate associated with the null hypothesis test was 0.05. Receiver operating curves (ROCs) were created using the gold standard of considered union. To define radiographic union, a cutoff value

was defined as total RUST and mRUST scores with specificity equal to or higher than 0.90 (95% CI). The area under ROC (AUC) was interpreted as failed test, 0.5–0.6; poor accuracy, 0.6–0.7; fair accuracy, 0.7–0.8; good accuracy, 0.8–0.9; and excellent accuracy, 0.9–1.0 (16). The ROC characteristics and comparisons were used to evaluate the value of the score obtained for each cortex for determining the diagnostic value of radiographic union. Statistical analyses were performed using the Statistical Package for the Social Sciences (SPSS®) version 22 (IBM SPSS Corp.; Armonk, NY, USA) and MedCalc (version 19.2.6; MedCalc® Software Ltd., Ostend, Belgium).

## Results

The mean age of patients was 7.2±3.1 (range, 5–12) years for pediatric patients and 41.3±5.8 (range, 18–65) years for adult patients. Patient characteristics are shown in Table 2. Intra- and inter-rater reliabilities of mRUST (ICC: 0.92 and 0.86, respectively) were slightly higher than those of RUST (ICC: 0.81 and 0.77, respectively) (Table 3). There was perfect intra- and inter-rater reliability for RUST (ICC: 0.92 and 0.90, respectively) and mRUST (ICC: 0.88 and 0.83, respectively) in the pediatric patients and substantial intra- and inter-rater reliability in adult patients (ICC: 0.80 and 0.76, respectively, for mRUST, and 0.76 and 0.71, respectively, for RUST) (Table 3).

There were similar intra-observer reliability values and perfect inter-observer agreement between the observer groups (Table 4).

The mean mRUST and RUST scores at each time point were significantly higher for the pediatric group than for the adult group (Figure 2) (Table 5).

The Fleiss k coefficient for decision on radiographic union was perfect for pediatric femoral shaft fractures (0.88) and substantial for adult femoral shaft fractures (0.79). The mean mRUST and RUST scores at the time of union were 14.0±1.6 (range, 12–16) and 11.1±1.4 (range, 9–12), respectively, for pediatric femoral shaft fractures, and 12.3±2.9 (range, 9–16) and 9.9±2.7 (range 8–12), respectively, for adult femoral shaft fractures. The total and individual cortical mRUST scores had significantly higher diagnostic values for radiographic fracture union than the total and individual cortical RUST scores in adult femoral shaft fractures (Table 6) (Figure 3). However, there was no significant difference between the total and individual cortical mRUST and RUST scores regarding the diagnostic values for radiographic fracture union in pediatric femoral

**Table 2.** Patient characteristics of pediatric and adult femoral shaft fracture groups

	Pediatric fractures (n=24) mean±SD/n (%)	Adult fractures (n=24) mean±SD/n (%)
Age (years)	7.2±3.1	41.3±5.8
<b>Sex</b>		
Female	10 (41.7)	13 (54.1)
Male	14 (58.3)	11 (55.9)
BMI (kg/m <sup>2</sup> )	23.6±3.5	24.9±5.6
<b>Side</b>		
Right	16 (66.7)	12 (50)
Left	8 (33.3)	12 (50)
<b>Injury mechanism</b>		
Fall	9 (37.5)	7 (29.1)
Pedestrian injury	10 (41.7)	13 (54.1)
Motor vehicle accident	5 (20.8)	4 (16.8)
<b>Concomitant injury</b>		
Rib fracture	1 (4.1)	2 (8.2)
Abdominal injury	4 (16.4)	3 (12.3)
Head trauma	3 (12.3)	1 (4.1)
Duration between injury and surgery (days)	2.3±2.0	3.7±3.2
Time to union (weeks)	8.6±1.9	17.5±4.0

SD: standard deviation, BMI: body mass index

**Table 3.** Inter-observer agreement results of total and individual cortices RUST and mRUST scores in all patients

		RUST		mRUST	
		ICC	95% CI	ICC	95% CI
<b>All patients (n=48)</b>	Total	0.77	0.72–0.84	0.86	0.83–0.91
	Medial cortex	0.78	0.72–0.84	0.84	0.81–0.87
	Lateral cortex	0.69	0.61–0.77	0.74	0.67–0.80
	Anterior cortex	0.71	0.66–0.76	0.76	0.68–0.84
	Posterior cortex	0.75	0.69–0.81	0.82	0.77–0.87
<b>Adult patients (n=24)</b>	Total	0.73	0.63–0.83	0.78	0.72–0.84
	Medial cortex	0.74	0.68–0.80	0.81	0.77–0.85
	Lateral cortex	0.67	0.61–0.72	0.70	0.60–0.80
	Anterior cortex	0.73	0.65–0.81	0.75	0.71–0.79
	Posterior cortex	0.75	0.66–0.84	0.79	0.72–0.86
<b>Pediatric patients (n=24)</b>	Total	0.85	0.81–0.89	0.92	0.85–0.99
	Medial cortex	0.88	0.83–0.93	0.94	0.91–0.97
	Lateral cortex	0.78	0.70–0.86	0.85	0.79–0.91
	Anterior cortex	0.84	0.76–0.92	0.90	0.82–0.98
	Posterior cortex	0.86	0.84–0.88	0.89	0.85–0.93

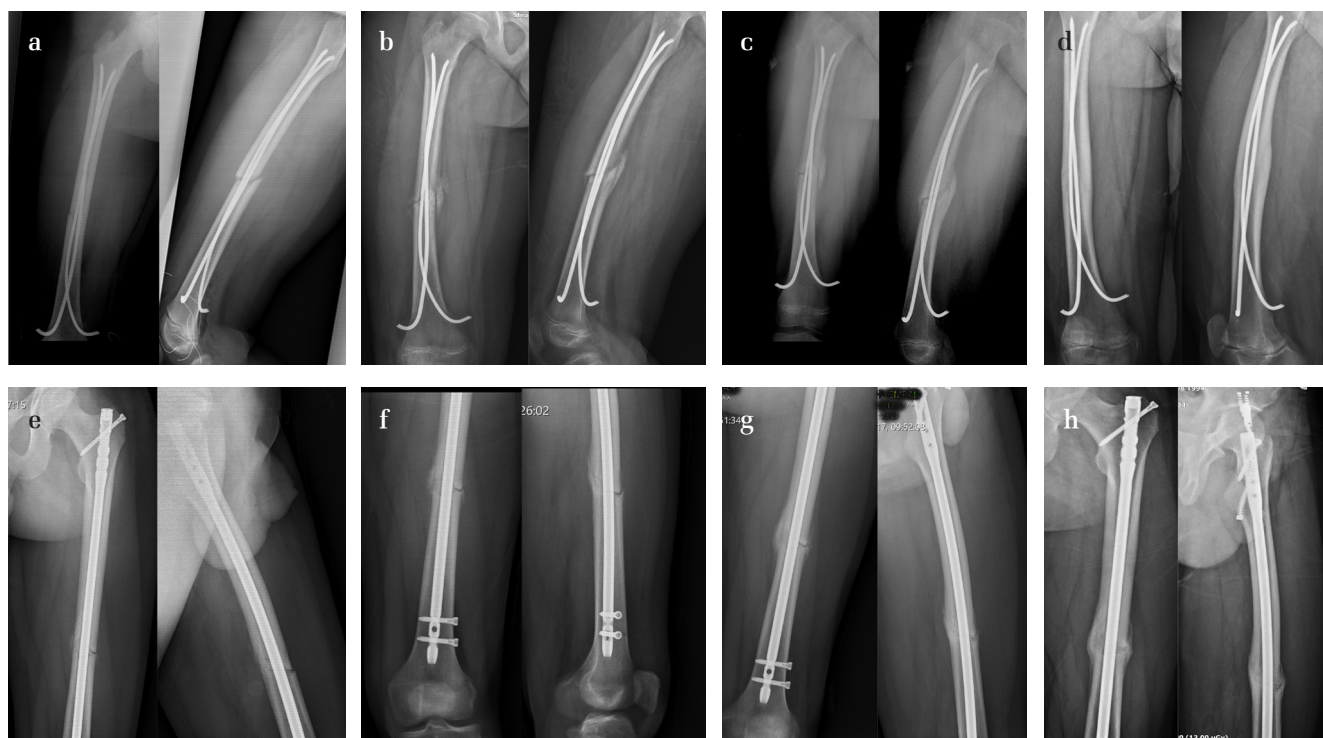RUST: radiographic union scale in tibial fractures; mRUST: modified radiographic union scale in tibial fractures; ICC: intra-class correlation coefficient; CI: confidence interval

shaft fractures. A RUST score of 10 and mRUST score of 12 were excellent predictors for considering fracture union (AUC: 0.924; sensitivity: 0.985 [95% CI: 0.958–0.999]; specificity: 0.898 [95% CI: 0.883–0.947] for RUST score and AUC: 0.993; sensitivity: 0.975 [95% CI: 0.936–0.999]; specificity: 0.924 [95% CI: 0.900–0.958] for mRUST score).

**Table 4.** Intra- and inter-observer agreement results between pediatric orthopedic surgeons, general orthopedic surgeons, and trauma surgeons regarding the RUST and mRUST scores

			Mean±SD (range)	ICC (intra-rater) (95% CI)	ICC (inter-rater) (95% CI)	p**
Pediatric fractures (n=24)	RUST	Pediatric orthopedic surgeons	11.5±1.2 (8–12)	0.90 (0.84–0.96)		
		p*		<0.001		
		General orthopedic surgeons	11.4±1.6 (7–12)	0.86 (0.79–0.94)		
		p*		<0.001	0.83 (0.76–0.91)	<0.001
	mRUST	Pediatric orthopedic surgeons	14.2±1.4 (10–16)	0.89 (0.85–0.93)		
		p*		<0.001		
		General orthopedic surgeons	14.1±1.6 (10–16)	0.88 (0.84–0.92)		
		p*		<0.001	0.90 (0.83–0.99)	<0.001
p***				0.358		
Adult fractures (n=24)	RUST	General orthopedic surgeons	9.9±1.9 (8–12)	0.84 (0.78–0.90)		
		p*		<0.001		
		Trauma surgeons	9.8±2.0 (8–12)	0.84 (0.81–0.87)		
		p*		<0.001	0.84 (0.75–0.92)	<0.001
	mRUST	Pediatric orthopedic surgeons	10.0±2.6 (8–12)	0.81 (0.77–0.85)		
		p*		<0.001		
		General orthopedic surgeons	12.4±2.3 (10–16)	0.85 (0.79–0.92)		
		p*		<0.001	0.81 (0.75–0.89)	<0.001
p***				0.826		
mRUST	Trauma surgeons	12.6±2.8 (10–16)	0.82 (0.79–0.85)			
	p*		<0.001			
	Pediatric orthopedic surgeons	12.8±2.8 (10–16)	0.83 (0.75–0.91)			
	p*		<0.001	0.525		

SD: standard deviation; ICC: intra-class correlation coefficient; RUST: radiographic union scale in tibial fractures; mRUST: modified radiographic union scale in tibial fractures  
 \*intra-observer reliability, \*\*inter-observer reliability, \*\*\*McNemar test  
 Bold values indicate statistical significance



**Figure 2.** a-h. Postoperative 4 (a and e), 8 (b and f), 12 (c and g), and 16-week (d and h) follow-up AP and lateral radiographs of pediatric and adult patients. The radiographic union scale in tibial fractures and modified radiographic union scale in tibial fractures scores of the pediatric patients (a to d) are higher than the adult patients (e to h) at all time points. AP: anteroposterior



**Table 5.** Mean RUST and mRUST scores of pediatric and adult femoral shaft fractures at 4 different time points

	Pediatric fractures (n=24)	Adult fractures (n=24)	p
4-week RUST (mean±SD)	4.8±1.3	4.1±0.8	<b>0.003*</b>
4-week mRUST (mean±SD)	5.3±1.1	4.5±1.2	<b>0.001*</b>
8-week RUST (mean±SD)	7.6±1.5	6.0±1.3	<b>&lt;0.001*</b>
8-week mRUST (mean±SD)	8.6±2.2	7.2±2.0	<b>&lt;0.001*</b>
12-week RUST (mean±SD)	9.8±1.4	8.2±1.9	<b>&lt;0.001*</b>
12-week mRUST (mean±SD)	12.2±2.5	10.6±2.1	<b>0.001*</b>
16-week RUST (mean±SD)	11.1±1.4	9.9±2.7	<b>0.001*</b>
16-week mRUST (mean±SD)	14.0±1.6	12.3±2.9	<b>&lt;0.001*</b>

RUST: radiographic union scale in tibial fractures; SD: standard deviation; mRUST: modified radiographic union scale in tibial fractures

\*independent samples t-test

Bold values indicate statistical significance

**Table 6.** Ability of union decision of total and individual cortex RUST and mRUST scores in adult and pediatric femoral shaft fractures

		RUST AUC	mRUST AUC	p
Adult fractures (n=24)	Total score	0.922	0.984	0.016
	Anterior cortex score	0.856	0.963	<0.001
	Posterior cortex score	0.854	0.958	<0.001
	Lateral cortex score	0.824	0.936	<0.001
	Medial cortex score	0.859	0.972	<0.001
Pediatric fractures (n=24)	Total score	0.965	0.988	0.216
	Anterior cortex score	0.943	0.990	0.456
	Posterior cortex score	0.931	0.953	0.703
	Lateral cortex score	0.923	0.952	0.589
	Medial cortex score	0.894	0.960	0.082

RUST: radiographic union scale in tibial fractures; mRUST: modified radiographic union scale in tibial fractures

Bold values indicate statistical significance

## Discussion

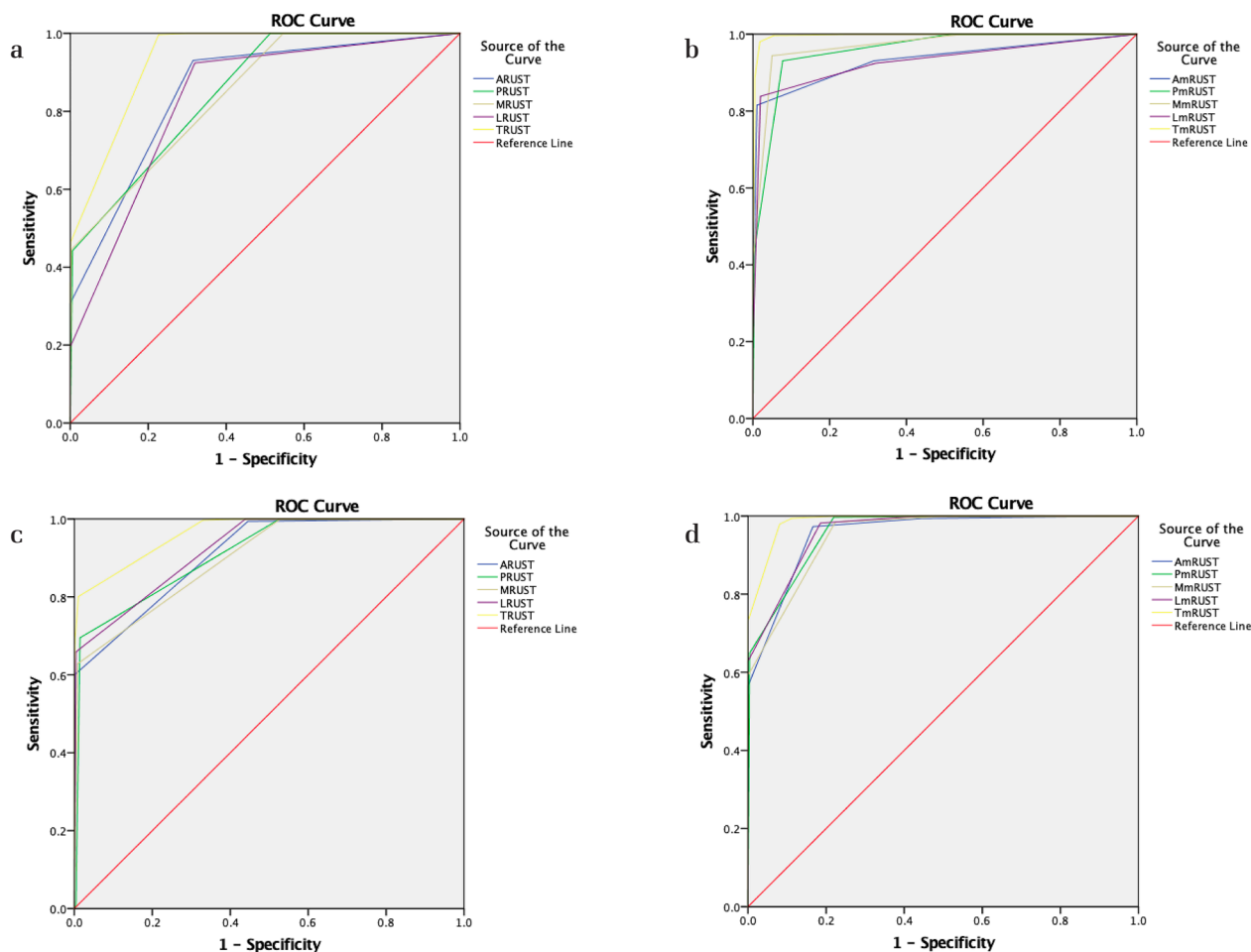
The most important findings of this study were that both the RUST and mRUST scores were reliable for the assessment of fracture union in pediatric and adult femoral shaft fractures treated with intramedullary fixation. The mRUST score had a higher inter-rater agreement than the RUST score for various stages of healing of the femoral shaft fractures. There was perfect agreement between the mRUST and RUST scores for the evaluation of healing of pediatric femoral shaft fractures (0.90 and 0.83, respectively), with substantial agreement for adult femoral shaft fractures (0.76 and 0.71, respectively). No significant difference was found between intra- and inter-observer reliability values of the 2 scores between the observer groups. The total and individual cortical mRUST scores had a significantly higher diagnostic value regarding radiographic union decision than the total and individual cortical RUST scores in adult femoral shaft fractures.

Although the RUST score has been developed to evaluate fracture union after intramedullary fixation of the tibial shaft fractures, it can also be used reliably for the evaluation of bone union in different anatomic regions for different fixation methods and different fracture types or osteotomy conditions (4, 17-20). Litrenta et al. have previously evaluated the reliability of the RUST and mRUST scores for the healing of metadiaphyseal femoral fractures treated using intramedullary nailing or plating (4). They have reported substantial agreement for both scores, with a slightly higher inter-observer agreement for the mRUST score for metadiaphyseal femoral fractures treated using intramedullary nail. They also identified that a RUST score of 10 points and a mRUST score of 13 points were reported by >90% of reviewers when they decided that radiographic fracture union had been achieved. In our study, there was perfect agreement between the mRUST and RUST scores for pediatric femoral shaft fractures (ICC: 0.90 and 0.83, respectively) and substantial agreement for adult fractures (ICC: 0.76 and 0.71, respectively). When we evaluated the scoring for individual reviewers, we identified that a RUST score of 11 points and a mRUST score of 14 points were reported by >90% of reviewers when they decided that radiographic union was achieved in pediatric

femoral shaft fractures. The RUST and mRUST scores at radiographic union for adult femoral shaft fractures were 10 points and 13 points, respectively. The mean RUST and mRUST scores at the time of union were 11.1 and 14.0, respectively, for pediatric fractures and 9.9 and 12.3, respectively, for adult fractures. The differences between pediatric and adult fracture union scores may be attributed to more callus formation and rapid bridging in pediatric fractures (21).

The mRUST score has been developed to present a wider range of scores between the phase of callus formation and bridging (22). As such, the mRUST score is better in decision making regarding fracture union, which is defined as observation of bridging on multiple cortices, than the RUST score. As the mRUST score evaluates the phase of healing from callus presentation to remodeling of the cortices, the agreement in decision of fracture union between the reviewers was higher for the mRUST than for the RUST score (9). The outcomes of our study confirmed these findings, with a higher agreement of union between the reviewers and predictive value for the mRUST than for the RUST score.

There are many radiological methods used in the evaluation of fracture union. Radiography is the most preferred method because of its low cost, widespread use, and low-radiation profile (23). Callus development and bridging of the fracture line with callus are the most common signs of union (23). Computed tomography (CT) is also an important method used to evaluate fracture union. It may show callus formation earlier than radiographs (24). However, its use in routine follow-up is not possible owing to its high cost and radiation levels (23). CT is recommended in case of uncertainty in radiographic findings. In addition, it allows quantitative and volumetric measurements and also helps to evaluate the fracture microstructure (25). Another method used in the evaluation of fracture union is ultrasonography (USG), which is gaining popularity because of its rapid application, widespread use, and lack of ionizing radiation risk. As it is not dependent on mineralization in the evaluation of union in radiography and CT examination, it may show signs of healing within 1–2 weeks after fracture (23). In addition, the availability of hardware makes radiography and CT difficult to evalu-



**Figure 3.** a-d. Receiver operating curves regarding union decision; a) total and individual cortical radiographic union scale in tibial fractures scores in adult femoral shaft fractures, b) total and individual cortical modified radiographic union scale in tibial fractures scores in pediatric femoral shaft fractures, c) total and individual cortical modified radiographic union scale in tibial fractures scores in adult femoral shaft fractures, d) total and individual cortical modified radiographic union scale in tibial fractures scores in pediatric femoral shaft fractures

ate, providing a distinctive advantage for USG. Furthermore, vascularization of the healing tissue can be examined using the Doppler USG method. The disadvantage of USG is that because of shading of the superficial tissues, the evaluation of deep cortical surfaces becomes difficult. Finally, scintigraphy can also be used to evaluate fracture union. It can be used to differentiate the presence of non-viable non-union and viable tissue, especially in cases where radiographic callus tissue is not observed (26). In clinical practice, radiography is the most commonly used method in the evaluation of union in both conservatively and operated fractures. Because of its widespread use, it is important to distinguish the findings and develop scales that will make the decision about union more accurate. In this study, we showed that the previously developed RUST and mRUST scores, which are the most commonly used methods in the evaluation of union in long bone fractures, are reliable methods in the evaluation of healing in simple two-part pediatric and adult femoral shaft fractures. Using other radiological methods within their clinical availability and requirements may be helpful in the evaluation of union.

The diagnostic value of the scores for individual cortices on fracture union has not previously been evaluated. In our study, the diagnostic value of total and individual cortical mRUST scores for bone healing was significantly higher than that of the total and individual cortical RUST scores in adult femoral shaft fractures. The diagnostic value of total and individual cortical mRUST scores for pediatric femoral shaft fractures was slightly higher, although it was not statistically

significant compared with the RUST scores. Our findings support the fact that it may be more beneficial to prefer the mRUST score over the RUST score in the evaluation of radiological union of adult femoral shaft fractures in clinical practice.

There were several strengths and limitations of our study. This was the first study to evaluate the healing of femoral shaft fractures in pediatric and adult patients treated with intramedullary fixation using 2 radiographic scoring systems. We proposed the diagnostic values of total scores and the score for individual cortices on union. Furthermore, evaluation by non-orthopedic observers was not performed, and this factor could have decreased the possibility of bias. A radiologist's evaluation in a dark room with high-resolution monitors and magnifying tools could affect the scoring; however, observers were selected from a wide range of experienced surgeons. Evaluating the segmental fractures and non-unions could give more meaningful results. Future studies are warranted, including complex fracture patterns, different fixation methods, and fracture non-unions. Evaluation of the correlation between physical examination findings, CT imaging, pain scores, and functional outcome scores could enable surgeons to make more precise decisions about fracture healing and union.

In conclusion, fracture union of simple two-part pediatric and adult femoral shaft fractures treated with intramedullary fixation can be reliably assessed using the RUST and mRUST scores. The diagnostic value of the mRUST score is more evident in adult fractures.

**Ethics Committee Approval:** Ethics committee approval was received for this study from the Institutional Review Board of Health Sciences University Metin Sabancı Baltalimani Bone and Joint Diseases Training and Research Hospital (Approval date and number: 22.02.2018/24).

**Informed Consent:** An informed consent is not needed for this type of study.

**Author Contributions:** Concept - A.M., E.U.; Design - A.M., E.U.; Supervision - K.İ.Y.; Fundings - K.İ.Y., M.Ö.; Materials - K.İ.Y., M.Ö.; Data Collection and/or Processing - T.B.K., M.Ö.; Analysis and/or Interpretation - A.M., T.B.K., M.Ö., S.O.; Literature Review - A.M., T.B.K., S.O.; Writing - A.M.; Critical Review - K.İ.Y., E.U., S.O.

**Conflict of Interest:** The authors have no conflicts of interest to declare.

**Financial Disclosure:** The authors declared that this study has received no financial support.

## References

- Morshed S. Current options for determining fracture union. *Adv Med* 2014; 2014: 708574. [\[Crossref\]](#)
- Corrales LA, Morshed S, Bhandari M, Miclau T 3rd. Variability in the assessment of fracture-healing in orthopaedic trauma studies. *J Bone Joint Surg Am* 2008; 90: 1862-8. [\[Crossref\]](#)
- Bhandari M, Guyatt GH, Swiontkowski MF, Tornetta P 3rd, Sprague S, Schemitsch EH. A lack of consensus in the assessment of fracture healing among orthopaedic surgeons. *J Orthop Trauma*. 2002; 16: 562-6. [\[Crossref\]](#)
- Litrenta J, Tornetta P 3rd, Mehta S, et al. Determination of radiographic healing: An assessment of consistency using RUST and modified RUST in Metadiaphyseal fractures. *J Orthop Trauma* 2015; 29: 516-20. [\[Crossref\]](#)
- Dijkman BG, Sprague S, Schemitsch EH, Bhandari M. When is a fracture healed? Radiographic and clinical criteria revisited. *J Orthop Trauma* 2010; 24(Suppl 1): S76-80. [\[Crossref\]](#)
- Whelan DB, Bhandari M, Stephen D, et al. Development of the radiographic union score for tibial fractures for the assessment of tibial fracture healing after intramedullary fixation. *J Trauma* 2010; 68: 629-32. [\[Crossref\]](#)
- Kooistra BW, Dijkman BG, Busse JW, Sprague S, Schemitsch EH, Bhandari M. The radiographic union scale in tibial fractures: reliability and validity. *J Orthop Trauma* 2010; 24: S81-S6. [\[Crossref\]](#)
- Leow JM, Clement ND, Tawonsawatruk T, Simpson CJ, Simpson AHRW. The radiographic union scale in tibial (RUST) fractures: Reliability of the outcome measure at an independent centre. *Bone Joint Res* 2016; 5: 116-21. [\[Crossref\]](#)
- DiSilvio F Jr, Foyil S, Schiffman B, Bernstein M, Summers H, Lack WD. Long bone union accurately predicted by cortical bridging within 4 months. *J Bone Joint Surg Am Open Access* 2018; 3: e0012. [\[Crossref\]](#)
- Islam O, Soboleski D, Symons S, Davidson LK, Ashworth MA, Babyn P. Development and duration of radiographic signs of bone healing in children. *Am J Roentgenol* 2000; 175: 75-8. [\[Crossref\]](#)
- Lindaman LM. Bone healing in children. *Clin Podiatr Med Surg* 2001; 18: 97-108.
- Schell H, Duda GN, Peters A, Tsitsilonis S, Johnson KA, Schmidt-Bleek K. The haematoma and its role in bone healing. *J Exp Orthop* 2017; 4: 5. [\[Crossref\]](#)
- Perlepe V, Cerato A, Putineanu D, et al. Value of a radiographic score for the assessment of healing of nailed femoral and tibial shaft fractures: A retrospective preliminary study. *Eur J Radiol* 2018; 98: 36-40. [\[Crossref\]](#)
- Debuka E, Kushwaha NS, Kumar D, Singh A, Sharma V. Rust score-An adequate rehabilitation guide for diaphyseal femur fractures managed by TENS. *J Clin Orthop Trauma* 2019; 10: 922-7. [\[Crossref\]](#)
- Landis JR, Koch GG. The measurement of observer agreement for categorical data. *Biometrics* 1977; 33: 159-74. [\[Crossref\]](#)
- Tape T. The area under an ROC curve: interpreting diagnostic tests. Available at: <http://gim.unmc.edu/dxtests/roc3.htm>. Accessed 26 May 2020.
- Sganga ML, Summers NJ, Barrett B, et al. Radiographic union scoring scale for determining consolidation rates in the calcaneus. *J Foot Ankle Surg* 2018; 57: 2-6. [\[Crossref\]](#)
- Franzone JM, Finkelstein MS, Rogers KJ, Kruse RW. Evaluation of fracture and osteotomy union in the setting of osteogenesis imperfecta: Reliability of the modified radiographic union score for tibial fractures (RUST). *J Pediatr Orthop* 2020; 40: 48-52. [\[Crossref\]](#)
- Richards BS, Wilkes D, Dempsey M, Nurenberg P. A radiographic scoring system to assess healing in congenital pseudoarthrosis of the tibia. *J Pediatr Orthop B* 2015; 24(2): 118-22. [\[Crossref\]](#)
- Patel SP, Anthony SG, Zurakowski D, et al. Radiographic scoring system to evaluate union of distal radius fractures. *J Hand Surg* 2014; 39: 1471-9. [\[Crossref\]](#)
- Eliezer EN, Haonga BT, Morshed S, Shearer DW. Predictors of reoperation for adult femoral shaft fractures managed operatively in a sub-Saharan country. *J Bone Joint Surg Am* 2017; 99: 388-95. [\[Crossref\]](#)
- Cooke ME, Hussein AI, Lybrand KE, et al. Correlation between RUST assessments of fracture healing to structural and biomechanical properties. *J Orthop Res* 2018; 36: 945-53. [\[Crossref\]](#)
- Fisher JS, Kazam JJ, Fufa D, Bartolotta RJ. Radiologic evaluation of fracture healing. *Skeletal Radiol* 2019; 48: 349-61. [\[Crossref\]](#)
- Grigoryan M, Lynch JA, Fierlinger AL, et al. Quantitative and qualitative assessment of closed fracture healing using computed tomography and conventional radiography. *Acad Radiol* 2003; 10: 1267-3. [\[Crossref\]](#)
- Firoozabadi R, Morshed S, Engelke K, et al. Qualitative and quantitative assessment of bone fragility and fracture healing using conventional radiography and advanced imaging technologies-focus on wrist fracture. *J Orthop Trauma* 2008; 22(8 Suppl): S83-90. [\[Crossref\]](#)
- Niikura T, Lee SY, Sakai Y, Nishida K, Kuroda R, Kurosaka M. Comparison of radiographic appearance and bone scintigraphy in fracture nonunions. *Orthopedics* 2014; 37(1): e44-50. [\[Crossref\]](#)