

Autologous Serum Treatment for Corneoscleral Dellen Following Pterygium Surgery

Pterijum Cerrahisi Sonrası Korneaskleral Dellen için Otolog Serum Tedavisi

Ali KURT¹, Ayşe KARABIÇAK ACER², Raşit KILIÇ¹, Sedat TAŞDEMİR², Çağlar ÖKTEM²

ABSTRACT

In this case report we present autologous serum treatment for corneoscleral dellen developing after an uneventful pterygium surgery with limbal conjunctival autograft. A 52-year-old male patient presenting with symptoms of stinging and redness in the left eye was diagnosed with nasal primary pterygium. Left nasal pterygium excision and conjunctival autograft implantation were performed without an adjunctive antimetabolite therapy. The graft was necrotic and liquefied on the postoperative 11th day despite topical steroid, antibiotic, and artificial tear administration. There was corneoscleral dellen. Upon which topical steroid application was stopped and the frequency of artificial tear administration was increased (24x1). Corneoscleral dellen did not regress on the postoperative 15th day despite addition of lubricant gels/ointment to the treatment. Subsequently autologous serum drops at a concentration of 30% were also added to the treatment. Corneal dellen was completely healed and scleral re-surfacing was observed on the postoperative 22nd day. In conclusion, we believe that autologous serum administration should be considered among the treatment options when wide corneoscleral dellen formations, which are resistant to conventional treatments, are seen in patients.

Key Words: Pterygium, conjunctival autograft, corneal dellen, scleral dellen, autologous serum.

ÖZ

Biz bu vakada problemsiz limbal konjonktival otogreftli pterijum cerrahisi sonrası gelişen korneaskleral dellen için otolog serum tedavisini sunuyoruz. Sol gözünde kızarıklık ve batma semptomları olan 52 yaşında erkek hastaya nazal primer pterijum tanısı konuldu. Sol nazal pterijum eksizyonu ve konjonktival otogreft implantasyonu yardımcı antimetabolit ilaç kullanılmadan gerçekleştirildi. Greft topikal steroid, antibiyotik ve suni gözyaşına rağmen postoperatif 11. gün nekrotik ve erimişti. Burada korneaskleral dellen mevcuttu. Topikal steroid uygulaması sonlandırıldı ve suni göz yaşı sıklığı artırıldı (24x1). Korneaskleral dellen, lubrikant jel ilavesine rağmen postoperatif 15. gün gerilemedi. Tedaviye %30 konsantrasyonda otolog serum damla eklendi. Postoperatif 22. gün korneal dellen tamamen iyileşti ve skleral kalınlaşma gözlendi. Sonuç olarak, otolog serum geleneksel tedaviye dirençli geniş korneaskleral dellen geliştiği zaman tedavi seçenekleri arasında düşünülebilir.

Anahtar Kelimeler: Pterijum, konjonktival otogreft, korneal dellen, skleral dellen, otolog serum.

- 1- M.D. Asistant Professor, Ahi Evran University Faculty of Medicine, Department of Ophthalmology, Kirsehir/TURKEY
KURT A., dralikurt@gmail.com
KILIC R., kilicrasit@gmail.com
- 2- M.D., Ahi Evran University Faculty of Medicine, Department of Ophthalmology, Kirsehir/TURKEY
KARABIÇAK ACER A., drayseacer@hotmail.com
TASDEMİR S., drsedattasdemir@hotmail.com
OKTEM C., cglrokttem@hotmail.com

Geliş Tarihi - Received: 30.07.2015
Kabul Tarihi - Accepted: 21.12.2015
Glo-Kat 2016;11:67-69

Yazışma Adresi / Correspondence Address:
M.D. Asistant Professor, Ali KURT
Ahi Evran University Faculty of Medicine, Department of Ophthalmology,
Kirsehir/TURKEY

Phone: +90 531 992 86 04
E-mail: dralikurt@gmail.com

INTRODUCTION

The treatment of ocular pterygium has evolved with the development and application of various new strategies in recent years. Excision accompanied by adjunctive treatment with mitomycin C or conjunctival autograft is currently the most popular treatment option for both primary and recurrent pterygium cases.¹ However, the technique can lead to complications such as graft edema, graft necrosis, corneal and scleral dellen, conjunctival inclusion cyst, and Tenon's granulomas.²

Corneal dellens are small round excavations at the corneal margin and occur most often with a paralimbal elevation. The result is a localized break in the precorneal oily layer of the tears leading to localized dehydration and corneoscleral thinning, and the revelation of the underlying bluish uveal tissue color.³ Corneoscleral dellen cases following pterygium surgery performed without adjunctive therapy have rarely been reported.³⁻⁴

Autologous serum is quite similar to tears in terms of osmolarity and pH, and contains various growth factors that are very important for the ocular surface. These growth factors play a vital role in maintaining the health of the conjunctiva and the corneal epithelium. Autologous serum use is recommended in several ocular surface disorders such as Sjögren's syndrome, neurotrophic keratitis, and persistent epithelial defects.⁵

We, in this study, present autologous serum treatment of corneoscleral dellen developing after an uneventful pterygium surgery with limbal conjunctival autograft.

CASE REPORT

A 52-year-old male patient presenting with symptoms of stinging and redness in the left eye was diagnosed with nasal primary pterygium. The patient had no history of other ocular problems or systemic diseases.

Left nasal pterygium excision and conjunctival autograft implantation were performed without an adjunctive antimetabolite therapy. Cauterization was used at 4 perilimbal and episcleral points to stop hemorrhage during surgery. Eye patching was used postoperatively and while 1% prednisolone acetate, 0.3% lomefloxacin and hypromellose-containing unpreserved artificial tears were started to be administered 4 times a day, carbomer-containing eye gel 2 times a day was also started. The graft was slightly edematous and the corneal epithelial defect was closed on the third day of follow-up. However, the graft was necrotic and melted, and corneal (about 4x2 mm) and scleral (about 4x3 mm) dellen formations coexisted with severe stinging on the postoperative 11th day. There was no ciliary injection and no papillary or follicular reaction at the palpebral conjunctiva. There was only mild nasal conjunctiva edema at the scleral dellen edge and the bluish color of the underlying uveal tissue was not observed. We removed the necrotic tissue and changed the medication regime to 0.3% lomefloxacin 4 times a day, hypromellose containing unpreserved artificial tears 24 times a day, carbomer-containing eye gel 3 times a day and also continued the eye patching. We discontinued 1% prednisolone acetate use as it could delay epithelialization. The corneoscleral dellen was more prominent on the postoperative 15th day (Figure 1).

Topical autologous serum at 30% concentration was added to the treatment and the new treatment regime now consisted of autologous serum 24 times a day, 0.3% lomefloxacin 4 times a day, hypromellose-containing unpreserved artificial tears 24 times a day, together with the eye patching. Complete epithelialization was observed on the postoperative 22nd day. The autologous serum dose was decreased and continued 4 times a day for 1 month. Hypromellose-containing unpreserved artificial tears 4 times a day and carbomer-containing eye gel once a day were continued for 3 months. However, recurrent pterygium developed in the 6th month of follow-up (Figure 2).

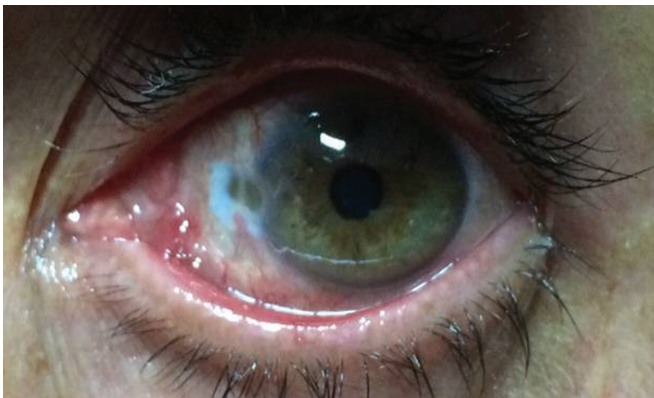


Figure 1: Postoperative 15th day corneoscleral dellen.

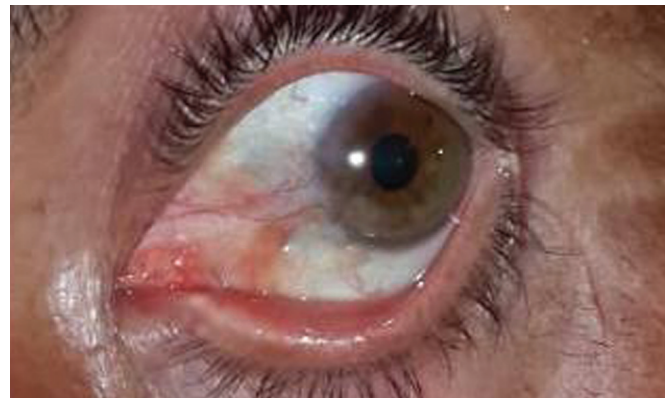

Figure 2: Postoperative 6th month recurrent pterygium.

DISCUSSION

The complication rate of pterygium excision varies between 0% and 26% depending on the selected surgical method and the use of adjunctive therapy such as mitomycin C.⁶ The use of adjunctive radiation and mitomycin C to decrease the risk of recurrence or the excessive cauterization of the scleral bed to prevent bleeding can give way to scleral melting and necrosis.⁷⁻⁸

Necrotizing scleritis induced by surgery should be taken into consideration in the diagnosis of necrosis and corneoscleral thinning following pterygium surgery with autograft. Paleness of the graft and increased inflammation in and around the underlying avascular sclera are indicative of such a complication. Accorinti et al.,³ reported corneal and scleral dellen formation in the 2nd postoperative week in a case receiving adjunctive naked sclera therapy for pterygium. The authors believed that dellen formation was related to the disturbance of tear film stability following a flu-like syndrome with 39°C fever and evaporation of the tears 2 days after the surgery, and reported that dehydration could also have contributed to dellen formation. This case was treated with topical lubricants and oral L-aminoacids together with eye patching.

The epidermal growth factor in autologous serum is especially important for the ocular surface and accelerates the migration of epithelial cells with an anti-apoptotic effect. The transforming growth factor β (TGF- β) concentration in autologous serum is three times of the amount in tears and it also plays a role in epithelial and stromal healing. Vitamin A concentration in autologous serums is higher than the one found in tears and it prevents squamous metaplasia of the epithelium. Among the proteins, albumin has anti-apoptotic activity while α -2 macroglobulin has anti-collagenase activity. Fibronectin is very important in cellular migration and its concentration in autologous serum is 10 times the amount found in tears. The autologous serum concentration used in various previous studies varied between 20% and 100% depending on the clinical protocol and patient groups.⁵

In this study, corneoscleral dellen developed on the 11th day following pterygium surgery with autograft without any perioperative complications. We believe that the ischemia and limbal cell damage that developed as a result of intraoperative cauterization performed at the perilimbal and episcleral region can account for one of the reasons for the development of corneoscleral dellen. Recovery was achieved in only one week by using autologous serum at 30% concentration following the patient's unresponsiveness to unpreserved artificial tears and ointments.

To the best of our knowledge, this is the first case of corneoscleral dellen developing after uneventful pterygium surgery with limbal conjunctival autograft without an adjunctive antimetabolite therapy to be treated with autologous serum. We believe that autologous serum should be taken into consideration among the treatment options when wide corneoscleral dellen resistant to conventional treatment develops.

REFERENCES/KAYNAKLAR

1. Mohammed I. Treatment of pterygium. *Ann Afr Med.* 2011;10:197-203.
2. Starck T, Kenyon KR, Serrano F. Conjunctival autograft for primary and recurrent pterygia: surgical technique and problem management. *Cornea.* 1991;10:196-202.
3. Accorinti M, Gilardi M, Giubilei M, et al. Corneal and scleral dellen after an uneventful pterygium surgery and a febrile episode. *Case Rep Ophthalmol.* 2014;5:111-5.
4. Yamazoe K, Shimazaki-Den S, Otaka I, et al. Surgically induced necrotizing scleritis after primary pterygium surgery with conjunctival autograft. *Clin Ophthalmol.* 2011;5:1609-11.
5. Azari AA, Rapuano CJ. Autologous serum eye drops for the treatment of ocular surface disease. *Eye Contact Lens.* 2015;41:133-40.
6. Mitra S, Ganesh A, Shenoy R. Scleral dellen complicating primary pterygium excision. *Eye* 2000;14:924-5.
7. MacKenzie FD, Hirst LW, Kynaston B, et al. Recurrence rate and complications after beta irradiation for pterygia. *Ophthalmology.* 1991;98:1776-80;1781.
8. Rubinfeld RS, Pfister RR, Stein RM, et al. Serious complications of topical mitomycin-C after pterygium surgery. *Ophthalmology.* 1992;99:1647-54.

Copyright of Glokom-Katarakt/Journal of Glaucoma-Cataract is the property of Glokom-Katarakt and its content may not be copied or emailed to multiple sites or posted to a listserv without the copyright holder's express written permission. However, users may print, download, or email articles for individual use.