



Post-radiotherapy bilateral external auditory canal cholesteatoma

Radyoterapi sonrası iki taraflı dış kulak yolu kolesteatomu

Emrah Sapmaz, MD,¹ Battal Tahsin Somuk, MD,¹ Harun Soyaliç, MD,²
Can Koçak, MD,¹ Erkan Gökçe, MD.³

¹Department of Otorhinolaryngology, Medical Faculty of Gaziosmanpaşa University, Tokat, Turkey

²Department of Otorhinolaryngology, Medical Faculty of Ahi Evran University, Kırşehir, Turkey

³Department of Radiology, Medical Faculty of Gaziosmanpaşa University, Tokat, Turkey

ABSTRACT

In this article, we report a 55-year-old female case was treated with radiotherapy due to nasopharynx carcinoma and diagnosed with bilateral external auditory canal cholesteatoma four years after radiotherapy. Persistent otorrhea was present in the patient and the diagnosis was established through noticing a soft tissue mass eroding external auditory canal anterior wall in temporal bone tomography as well as the otoscopic findings. Canaloplasty and cholesteatoma excision were administered as the surgical treatment.

Keywords: External auditory canal cholesteatoma; nasopharynx carcinoma; post-radiotherapy.

ÖZ

Bu yazıda, nazofarenks karsinomu nedeniyle radyoterapi ile tedavi edilen ve radyoterapiden dört yıl sonra iki taraflı dış kulak yolu kolesteatomu saptanan 55 yaşında bir kadın olgu sunuldu. Hastada inatçı otore vardı ve tanı otoskopik bulguların yanı sıra, temporal kemik tomografisinde dış kulak yolu ön duvarını aşındıran yumuşak doku kitlesinin görülmesi ile konuldu. Cerrahi tedavi olarak kanaloplasti ve kolesteatom eksizyonu yapıldı.

Anahtar Sözcükler: Dış kulak yolu kolesteatomu; nazofarenks karsinomu; radyoterapi sonrası.

External auditory canal cholesteatoma (EACC) is a rarely encountered disease, and its etiology is uncertain.^[1] External auditory canal cholesteatoma was first described in 1850,^[2] and defined in 1980,^[3] distinguishing EACC from keratosis obturans. Middle ear cholesteatoma is more commonly encountered than EACC in clinical practice. Post-surgical and post-traumatic inflammation, canal stenosis, canal atresia and

unknown etiology are the possible causes of EACC.^[4-6] External auditory canal cholesteatoma is typically associated with otorrhea and a chronic, dull pain because of local invasion of squamous tissue into the bony external auditory canal (EAC).^[3] Depending on its etiology, EACC is categorized into different types as congenital, post-traumatic, iatrogenic, post-obstructive, post-inflammatory, and spontaneous.^[7]



Radiotherapy, administered as the mainstay treatment of nasopharyngeal carcinoma (NPC) causes tissue breakdown and eventual radionecrosis impairing normal collagen synthesis and cell production in classic 3H principle including hypoxia, hypo-vascularity and hypo-cellularity.^[8] Post-radiotherapy EACC has rarely been reported in the literature.^[9] Because the initial symptomatology of crust, otorrhea, and otalgia is misdiagnosed as chronic otitis media, the disease may be overlooked.^[10]

We present a patient administered with radiotherapy for nasopharyngeal carcinoma who complained of a post-radiotherapy ear discharge for two years.

CASE REPORT

The 55-year-old female patient who was diagnosed with benign, differentiated non-keratinizing nasopharyngeal carcinoma six years ago underwent 7400 cGY of radiation therapy (RT) at 200 cFY for each fraction. For nearly two years, she had non-healing purulent discharge in both ears despite local and systemic medical treatment. There was no problem in complete blood count and biochemistry values. She also had no additional systemic disease. On otoscopic examination, purulent discharge was noted in both external auditory canals. The right tympanic membrane was centrally 2 mm perforated, and the left membrane had normal appearance. On temporal tomography, both exterior auditory canals were determined to have an appearance compatible with cholesteatoma at 0.7 cm diameter adjacent to the glenoid fossa on

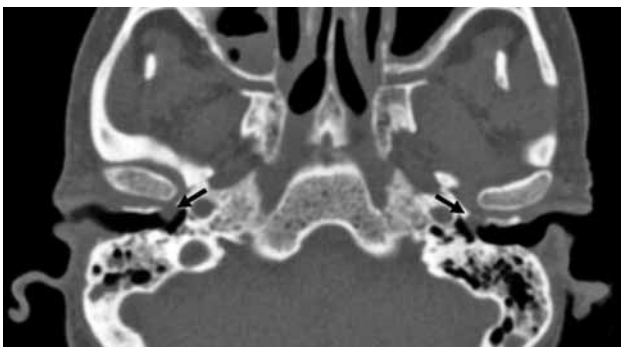


Figure 1. Computed tomography scan of a patient with both ears radiotherapy-related external auditory canal cholesteatoma. Radiotherapy-related external auditory canal cholesteatoma (right and left) with partial destruction of anterior-inferior bony canal.

anterior wall (Figure 1). The patient underwent cholesteatoma surgery with canaloplasty under general anesthesia (Figure 2). The cholesteatoma extended until the temporomandibular joint capsule eroding the external auditory canal bones anteriorly on both sides. During drilling, the eardrum was protected with a sheet of silastic film cut to size. After canaloplasty, the external canal cholesteatoma was removed. The area with the defect was covered with perichondrium drawn from the tragal cartilage. The patient had no problems on the sixth postoperative month follow-up. Written informed consent was obtained from the patient, and the study was conducted in accordance with the principles of the Declaration of Helsinki.

DISCUSSION

A cholesteatoma is a cystic structure lined by keratinizing stratified squamous epithelium associated with periostitis and bone erosion that are commonly found in middle ear cavity. Cholesteatoma is almost exclusively noticed in the middle ear and mastoid, and rarely in the EAC. Among all otologic patients, estimated incidence of EACC is 0.1-0.5%.^[11] Even though EACC is a rarely encountered disease, its distinctive diagnosis is important.

The external auditory canal embryologically derives from the pharyngeal groove between

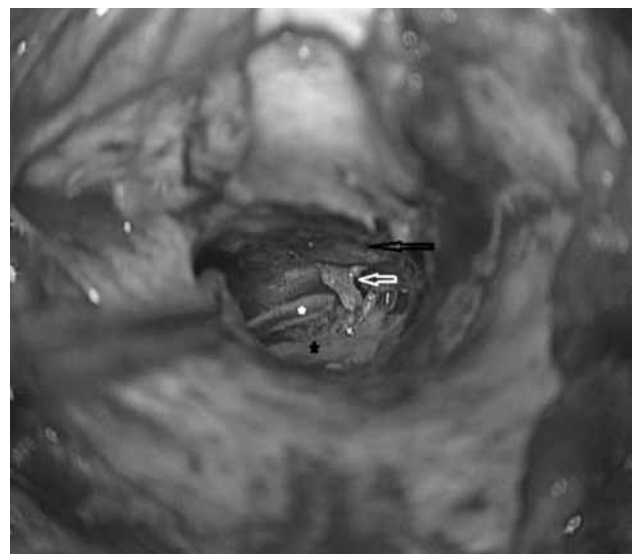


Figure 2. The view on the right external ear canal cholesteatoma. Black star: Tympanic membrane, White star: Anterior annulus fibrosis, White arrow: Cholesteatoma matrix, Black arrow: Capsule of temporomandibular joint.

the first and second branchial arches; and therefore derives from ectoderm and lined by the squamous epithelium. The skin that outlines the external auditory canal is thin and delicate.^[10] This particular site is predisposed to frequent iatrogenic trauma causing EACC in irradiated patients. Hypoxia and angiogenic factors have been reported to be responsible for the development of EACC.^[5,6] Within the irradiated skin area, a post-radiotherapy progressive decrease in size and number of blood vessels was frequently encountered with a concomitant increase in fibrous tissue.^[12] Thus, the possibility for cholesteatoma to occur in the external auditory canal is higher in the inferior part where blood build-up is less.

Radiation involving the external ear canal causes both soft tissue changes including epithelial hyperplasia and subsequent atrophic changes and osteitis including necrosis; therefore, in these cases, primary pathogenetic events are not clear.^[13] In their study, Owen et al.^[14] determined that the latencies between cholesteatoma therapy and discovery were five years (ranges from 3 to 12) on average. In our patient, the symptoms started four years after RT in parallel with the literature. The ECAA symptomatology of purulent otorrhea, otalgia, and granuloma can mimic the symptomatology of chronic otitis media.

As mentioned in the study of Yu et al.,^[15] invasion sites of EACC were predominantly in the anterior (14/18, 77.8%) and inferior (15/18, 83.3%) parts. Those were different from the invasion sites of EACC reported in the study of Owen et al.^[14] that specified the predominant sites as posterior (71%) and inferior (71%). In the case we presented, the cholesteatoma was bilaterally located anterior and inferior (Figure 1).

Computed tomography of the temporal bones is the gold standard for staging and preoperative planning in external auditory canal cholesteatoma.^[16] Through this method, accurate evaluation of local bone erosion and examination for involvement of adjacent structures are provided.^[1]

Depending upon the extent of bone destruction, treatment of spontaneous EACC can vary. However, some simple office procedures as meticulous debridement under the microscope, topical antibiotic drops, and the use of mineral

oil can be considered for EACC with mild bone erosion. These may be used singly or in combination.^[17] Most cases of spontaneous EACC have been satisfactorily managed with local dressing, even in the presence of significant bone destruction.^[7] In our patient the cholesteatoma extended to the temporomandibular joint capsule causing erosion of the external auditory canal bone so we applied surgical treatment.

Declaration of conflicting interests

The authors declared no conflicts of interest with respect to the authorship and/or publication of this article.

Funding

The authors received no financial support for the research and/or authorship of this article.

REFERENCES

1. Sayles M, Kamel HA, Fahmy FF. Operative management of external auditory canal cholesteatoma: case series and literature review. *J Laryngol Otol* 2013;127:859-66.
2. Toynbee J. A Specimens of molluscum contagiosum developed in the external auditory meatus. *Lond Med Gaz* 1850;46:261-4.
3. Piepergerdes MC, Kramer BM, Behnke EE. Keratosis obturans and external auditory canal cholesteatoma. *Laryngoscope* 1980;90:383-91.
4. Holt JJ. Ear canal cholesteatoma. *Laryngoscope* 1992;102:608-13.
5. Naim R, Riedel F, Bran G, Hörmann K. Expression of beta-catenin in external auditory canal cholesteatoma (EACC). *Biofactors* 2003;19:189-95.
6. Naim R, Riedel F, Gotte K, Bran G, Sadick H, Gossler U, et al. Co-expression of different angiogenic factors in external auditory canal cholesteatoma. *Acta Otolaryngol* 2004;124:563-8.
7. Vrabc JT, Chaljub G. External canal cholesteatoma. *Am J Otol* 2000;21:608-14.
8. Marx RE. Osteoradionecrosis: a new concept of its pathophysiology. *J Oral Maxillofac Surg* 1983;41:283-8.
9. Ramsden RT, Bulman CH, Lorigan BP. Osteoradionecrosis of the temporal bone. *J Laryngol Otol* 1975;89:941-55.
10. Hao SP, Tsang NM, Chang KP, Chen CK, Chao WC. Osteoradionecrosis of external auditory canal in nasopharyngeal carcinoma. *Chang Gung Med J* 2007;30:116-21.
11. Anthony PF, Anthony WP. Surgical treatment of external auditory canal cholesteatoma. *Laryngoscope* 1982;92:70-5.
12. Fitzgerald TJ, Jodoin MB, Tillman G, Aronowitz J, Pieters R, Balducci S, et al. Radiation therapy toxicity to the skin. *Dermatol Clin* 2008;26:161-72.
13. Adler M, Hawke M, Berger G, Harwood A. Radiation effects on the external auditory canal. *J Otolaryngol* 1985;14:226-32.
14. Owen HH, Rosborg J, Gaihede M. Cholesteatoma of the external ear canal: etiological factors, symptoms

- and clinical findings in a series of 48 cases. *BMC Ear Nose Throat Disord* 2006;6:16.
15. Yu SS, Lee KJ, Lin YS. External auditory canal cholesteatoma in patients given radiotherapy for nasopharyngeal carcinoma. *Head Neck* 2014 Jul 2.
 16. Shin SH, Shim JH, Lee HK. Classification of external auditory canal cholesteatoma by computed tomography. *Clin Exp Otorhinolaryngol* 2010;3:24-6.
 17. Chang J, Choi J, Im GJ, Jung HH. Dilute vinegar therapy for the management of spontaneous external auditory canal cholesteatoma. *Eur Arch Otorhinolaryngol* 2012;269:481-5.